

## An introduction to Orthodontics

### Definitions of Orthodontics:

- Is that branch of dentistry concerned with facial growth; development of the dentitions and occlusion; diagnosis; interception and treatment of occlusal anomalies. From etymological point, Orthodontics" is derived from the Greek "orthos" meaning straight or correct and "dontics" meaning teeth. Orthodontics therefore describes the practice of straightening misaligned teeth or malocclusions. Dentists who specialize in orthodontics can help manage abnormal positioning of the teeth, jaws and face.
- In 1907 Angle stated that the objective of the science of orthodontics is "The correction of malocclusion of the teeth".
- In 1911 Noyes defined orthodontics as "The study of the relation of the teeth to the development of the face and correction of arrested and perverted development".
- According to British society of orthodontics (1922) "Orthodontics includes the study of growth & development of the jaws & face particularly, & the body generally as influencing the position of the teeth; the study of action & reaction of internal & external influences on the development & the prevention & correction of arrested & perverted development.
- According to American Board of orthodontics (1929) "Orthodontics is that specific area of dental practice that has as its responsibility the study and supervision of the growth and the development of the dentition and its related anatomical structures from birth to dental maturity, including all preventive and corrective procedures of dental irregularities requiring the repositioning of teeth by functional or mechanical means to establish normal occlusion and pleasing facial contours".

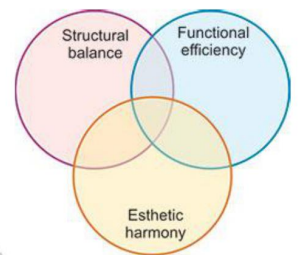
### Branches of Orthodontics:

- 1- Preventive Orthodontics: Graber (1966) defined it as the action taken to preserve the integrity of what appears to be normal occlusion at specific time. Proffit and Ackerman (1980) defined Preventive orthodontics as the prevention of potential interference with occlusal development
- 2- Interceptive Orthodontics: Richardson (1982) defined interceptive orthodontics as the prompt an early treatment of unfavourable features of a developing occlusion in children that may make the difference between achieving a satisfactory result by simple mechanics later, thus reducing overall treatment time and providing better stability and functional and aesthetic results

- 3- Corrective Orthodontics: Corrective orthodontics is that branch of orthodontics that recognizes the existence of malocclusion and the need for employing certain technical procedure to reduce or eliminate the problem and the attendant sequelae
- 4- Surgical Orthodontics: refers to surgical procedures carried out as an adjunct to or in conjunction with orthodontic treatment, that it may be before, within, or after orthodontic procedure.

**Aims & objectives of orthodontic treatment:** Aims & objectives of orthodontic treatment have been summarized by Jackson as the Jackson's Triad.

1. Functional Efficiency.
2. Structural Balance.
3. Esthetic Harmony.



Functional Efficiency Many malocclusions affect normal functioning of the stomatognathic system. The orthodontic treatment should thus aim at improving the functioning of the orofacial apparatus.

Structural Balance The oro-facial region consists of the dentoalveolar system, the skeletal tissue and the soft tissue including musculature. Stable orthodontic treatment is best achieved by maintaining a balance between these three tissue systems.

Esthetic Harmony By far the most common reason for seeking orthodontic care is to improve the appearance of the teeth & face. Many malocclusions are associated with unsightly appearance of teeth & can thus affect the individual's self-image, wellbeing & success in society. Thus, the orthodontic treatment should aim at improving the esthetics of the individual.

### **Scope of orthodontic treatment:**

1. Alteration in tooth position.
2. Alteration in skeletal pattern.
3. Alteration in soft tissue pattern.



### Important definitions:

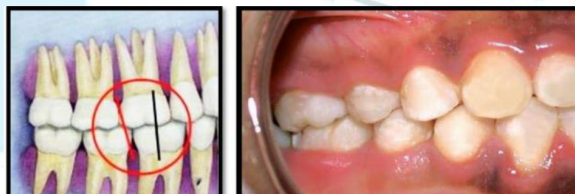**Occlusion:** Any position or relationship in which the upper and the lower teeth come together.

**Ideal Occlusion:** A theoretical concept of an ideal arrangement of the teeth within the dental arches, combined with an ideal inter-arch relationship, which concentrates optimal esthetic, function, and stability of the dentition and supporting structures. But it is almost never found in nature.

**Normal occlusion:** That occlusion which satisfies the requirements of function and esthetic but in which there are minor irregularities of individual teeth.

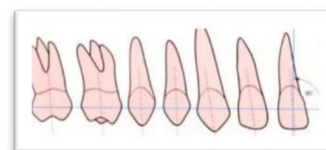
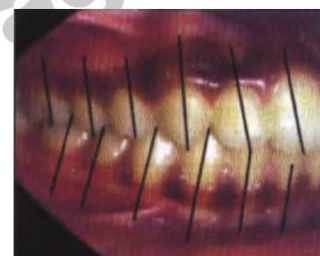### **6 keys of normal occlusion:**

**1: Molar relation:** The distal surface of the distobuccal cusps of the upper first permanent molar made contact and occluded with the mesial surface of the mesiobuccal cusps of the lower second molar, the mesiobuccal cusp of the upper first permanent molar fell within the groove between the mesial and middle cusps of the lower first permanent molar. (The canines and premolars enjoyed a cusp-embasement relationship).



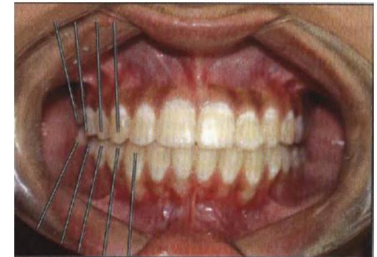**2: Crown angulation “The mesiodistal tip”**, The term angulation refers to angulation (or tip) of the long axis of the crown not to angulation of the long axis of the entire tooth. The gingival portion of the long axis of each crown was distal to the incisal portion varying with the individual tooth type, the long axis of the crown for all teeth except molars is identified to be the mid developmental of ridge which is the most prominent part and center most vertical portion of the labial or buccal surface of the crown.

The long axis of the molar crown is identified by the dominant vertical groove on the buccal surface of the crown.



### 3: Crown inclination (Labiolingual or buccolingual inclination):

Crown inclination refers to the labiolingual or buccolingual inclination of the long axis of the crown not to the inclination of the long axis of entire tooth. The inclination of all the crowns has a consistent scheme:



#### a- Anterior teeth (Central and lateral incisors)

The labial inclination of upper and lower anterior crown is sufficient to resist over eruption of anterior teeth and sufficient also to allow proper distal positioning of the contact points of the upper teeth in their relationship to the lower teeth, permitting proper occlusion of the posterior teeth.

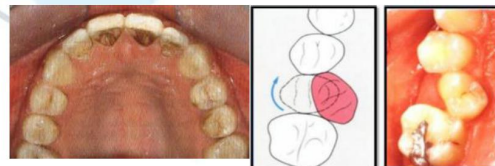
#### b-Upper posterior teeth (Canines through molars)

A palatal crown inclination existed in the upper posterior crown was a constant and similar from the canines through the second premolar and was slightly more pronounced in the molars.

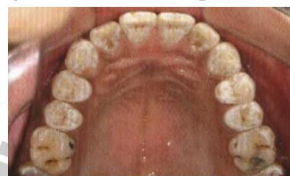#### c-Lower posterior teeth (Canines through molars)

The lingual crown inclination in the lower posterior teeth progressively increases from the canine through the second molar.

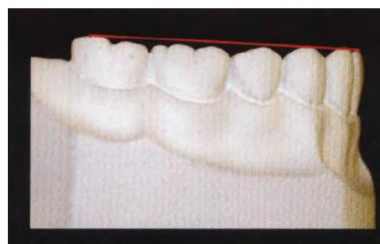**4: Rotation:** There are no undesirable rotations. Rotated molar and bicuspid occupy more space than normal while rotated incisors occupies less space than normal



**5: Spaces:** there were no spaces with tight contact point.



**6: Occlusal planes:** the plane of occlusion varied from generally flat to a slight curve of spee (which measured from most prominent cusp of lower second molar to the lower central incisor), no curve deeper than 1.5 mm is accepted from a stand point of occlusal stability.





Recently the authors believe that the correct crown diameter represents the seventh key to normal occlusion this key (the seventh key) had to be present in Andrews non-orthodontic normal study models.

## Malocclusion

Defined as any deviation from the normal or ideal occlusion.

### Aims of Orthodontics: Improve the following:

- 1- Dental health:
  - a- Dental caries: Mal-alignment of the teeth may reduce the potential for natural teeth –cleansing and increase the risk of decay.
  - b- Periodontal disease: Irregular teeth reduce effective brushing, in addition to that, crowding may force one or more teeth to be squeezed buccally or lingually out of their investing bone reducing periodontal support and finally traumatic occlusion may lead to increase loss of periodontal support (e.g.: anterior crossbite).
  - c- Trauma to anterior teeth: Researches have shown that overjet more than 3 mm had more than double the risk of traumatic injury.
  - d- Impacted teeth: Impacted (unerupted) tooth may affect normal position and health of adjacent teeth in addition to the loss of function of the impacted tooth itself.
- 2- Function:
  - a- Masticatory function: Patients with open bites; markedly increased overjet (Class II) or reversed overjet (Class III) often complain difficulties with eating, particularly incising food.
  - b- Speech: Crowding may have little effect on normal speech.
  - c- Temporo-mandibular joint: There is no clear association between malocclusion and the TMJ.
- 3- Psychosocial -wellbeing: Unattractive dento-facial appearance does have a negative effect on expectations of teachers and employers.

### **Risks of orthodontic treatments:**

- 1- Root resorption: During 2- years of fixed orthodontic treatment it is inevitable to find 1mm of root resorption, however the use of excessive orthodontic force may lead to un-accepted amount of

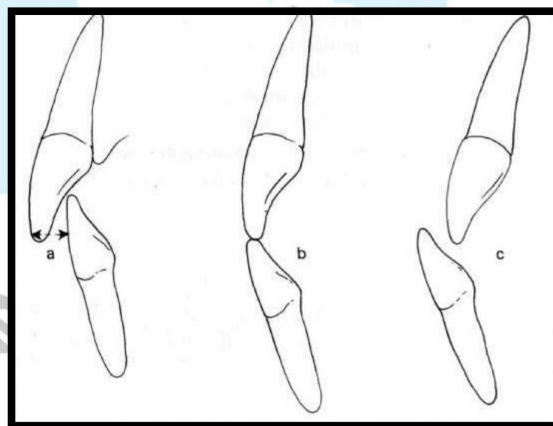
root resorption and hence devitalization of affected tooth or teeth.

- 2- Loss of periodontal support: Caused by poor oral hygiene during orthodontic treatment.
- 3- Demineralization: May occur during fixed orthodontic treatment specially, as a result of plaque accumulations in case of un-cooperative patient (poor oral hygiene).
- 4- Soft tissue damage: Traumatic ulceration may occur specially in fixed orthodontic treatment.
- 5- Pulpal injury: Excessive orthodontic force may lead to pulp injury and death especially for the teeth with a history of trauma.

### Orthodontic definitions:

**Incisal overjet:** The horizontal distance between the upper and lower incisors in occlusion, measured at the tip of the upper incisor (Fig. 1).

It is dependent on the inclination of the incisor teeth and the antero-posterior relationship of the dental arches. In most people, there is a positive overjet, i.e. the upper incisor is in front of the lower incisor in occlusion (normally 2-4 mm), but the overjet may be reversed (in case of Class III), or edge-to-edge.

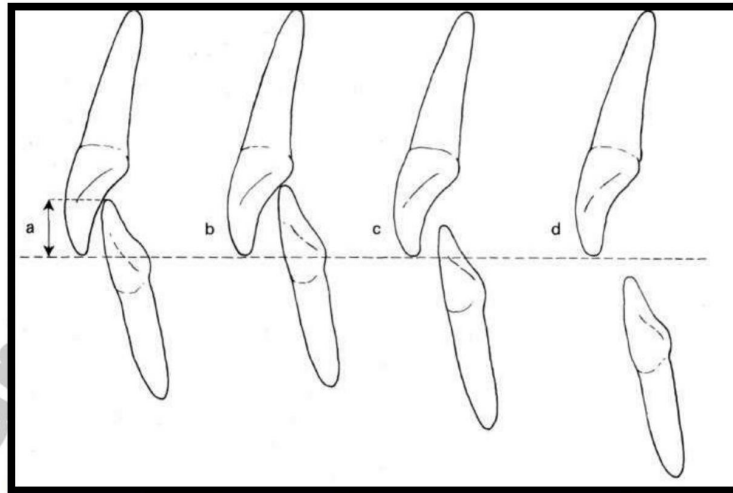


Incisal overjet: (a) The ideal overjet relationship, (b) Edge to edge incisal position, (c) Reversed overjet.

**Incisal overbite:** The overbite is the vertical distance between the tips of the upper and lower incisors in occlusion (Fig.2).

It is governed by the degree of vertical development of the anterior dento-alveolar segments. Ideally, the lower incisors contact the middle third of the palatal surface of the upper incisors in occlusion (2-4 mm),

but there may be excessive overbite (deepbite), or there may be no incisal contact, in which case the overbite is described as *incomplete overbite* when the lower incisors are above the level of the upper incisal edges, or *anterior open bite*, when the lower incisors are below the level of the upper incisal edges in occlusion.



Incisal overbite: (a) Ideal overbite relationship, (b) Excessive incisal overbite (deepbite), (c) Incomplete overbite, (d) Anterior open bite.

**Acknowledgement:** I would like to thank Prof. Dr. Dhiaa J. Nasir Al-Dabagh, for helping me completing and presenting the lecture



<https://youtu.be/S63F0z8dtjo>