Human Anatomy

Lec.3 **د.فراس عبد الرحمن**

The Nasal region

The Nose

The nose consists of the external nose and the nasal cavity, both of which are divided by a septum into right and left halves.

❖ External Nose

The external nose has two elliptical orifices called the **nostrils,** which are separated from each other by the **nasal septum** (**Fig. 1**). The lateral margin, the **ala nasi,** is rounded and mobile. The framework of the external nose is made up above by the nasal bones, the frontal processes of the maxillae, and the nasal part of the frontal bone. Below, the framework is formed of plates of hyaline cartilage (**Fig. 1**).

Nerve Supply of the External Nose

The external nose is supplied by the infratrochlear and external nasal branches of the ophthalmic nerve (**CN V**), and the infraorbital branch of the maxillary nerve (**CN V**).

Blood Supply and Venous Drainage of the External Nose

The skin of the external nose is supplied by branches of the **ophthalmic** and the **maxillary** arteries. The skin of the ala and the lower part of the septum are supplied by branches from the **facial** artery. Venous blood from the external nose drains mostly into the **facial vein** via the angular and lateral nasal veins.

❖ Nasal Cavity

The nasal cavity extends from the nostrils in front to the **posterior nasal apertures** or **choanae** behind, where the nose opens into the nasopharynx. The **nasal vestibule** is the area of the nasal cavity lying just inside the nostril (**Fig. 2**). The nasal cavity is divided into right and left halves by the **nasal septum** (**Fig. 1**). The septum is made up of the **septal cartilage,** the **vertical plate of the ethmoid,** and the **vomer.**

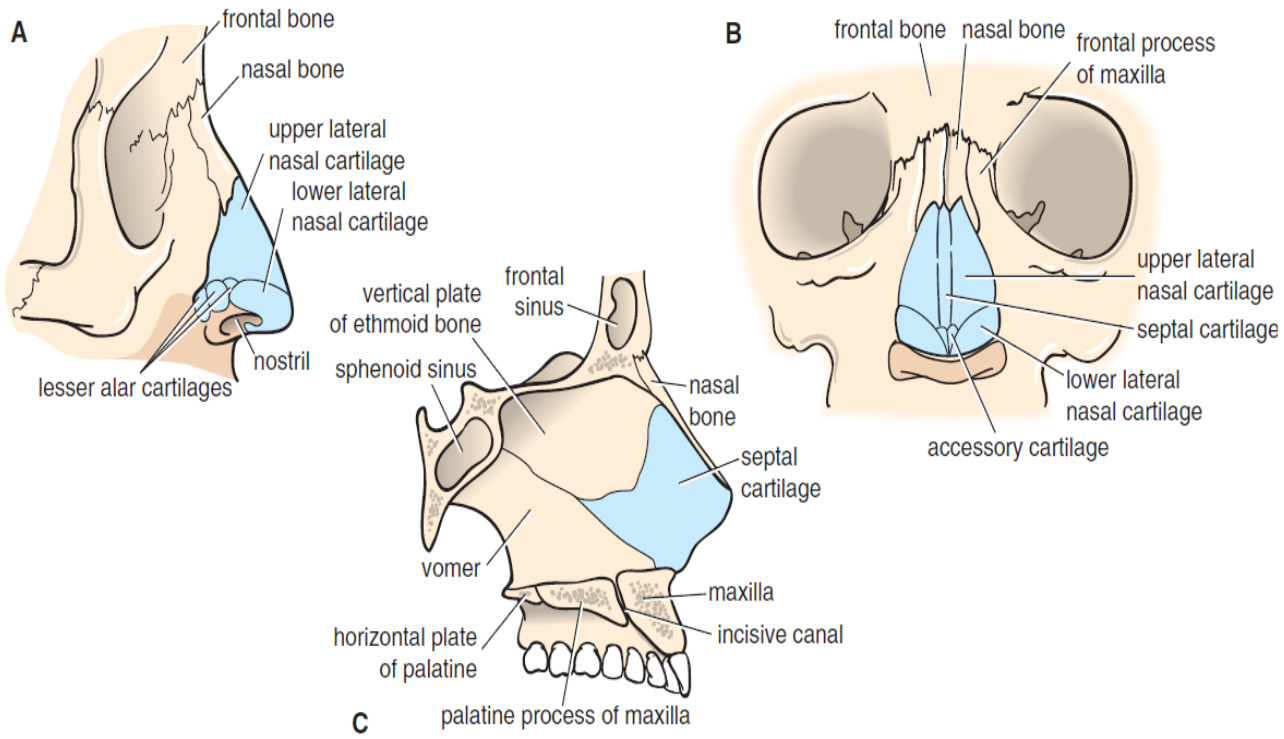

FIGURE 1: External nose and nasal septum. **A.** Lateral view of bony and cartilaginous skeleton of external nose. **B.** Anterior view of bony and cartilaginous skeleton of external nose. **C.** Bony and cartilaginous skeleton of nasal septum.

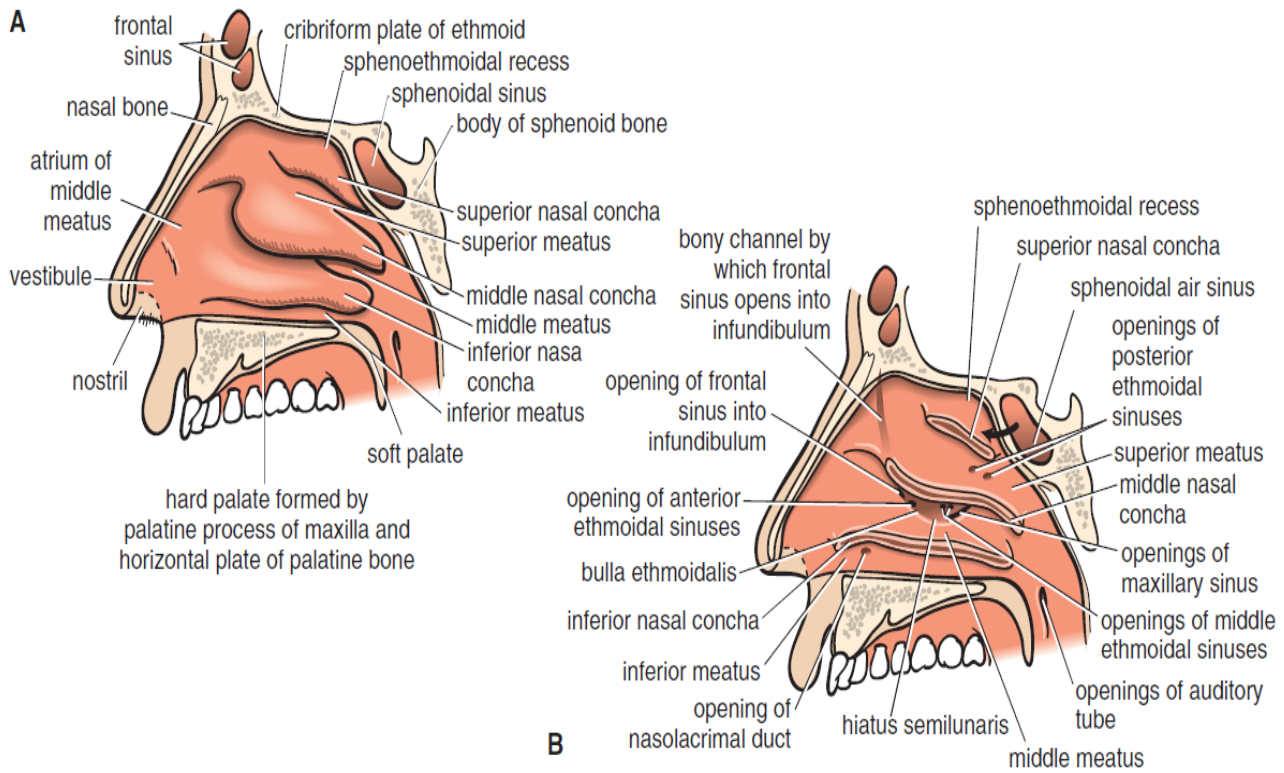

FIGURE 2: **A.** Lateral wall of the right nasal cavity. **B.** Lateral wall of the right nasal cavity; the superior, middle, and inferior conchae have been partially removed to show openings of the paranasal sinuses and the nasolacrimal duct into the meati.

Mucous Membrane of the Nasal Cavity

The vestibule is lined with modified skin and has coarse hairs. The area above the superior concha is lined with olfactory mucous membrane and contains nerve endings sensitive to the reception of smell. The lower part of the nasal cavity is lined with respiratory mucous membrane. A large plexus of veins in the submucous connective tissue is present in the respiratory region.

The presence of warm blood in the venous plexuses serves to heat up the inspired air as it enters the respiratory system. The presence of mucus on the surfaces of the conchae traps foreign particles and organisms in the inspired air, which are then swallowed and destroyed by gastric acid.

Nerve Supply of the Nasal Cavity

The olfactory nerves from the olfactory mucous membrane ascend through the cribriform plate of the ethmoid bone to the olfactory bulbs (**Fig. 3**). The nerves of ordinary sensation are branches of the ophthalmic division (V1) and the maxillary division (V2) of the trigeminal nerve (**Fig. 3**).

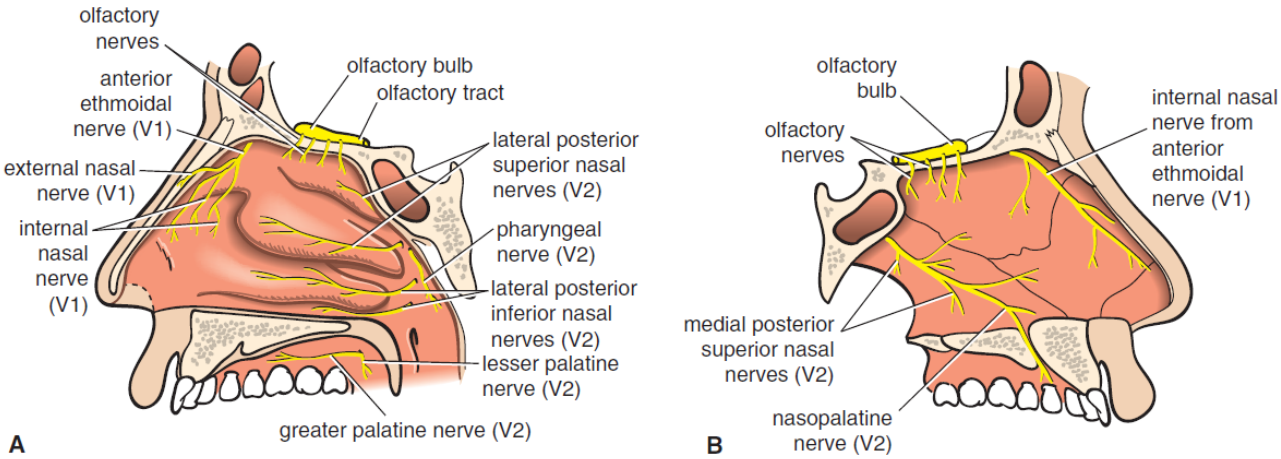

FIGURE 3: **A.** Lateral wall of nasal cavity showing sensory innervation of mucous membrane. **B.** Nasal septum showing sensory innervation of mucous membrane.

Blood Supply to the Nasal Cavity

The arterial supply to the nasal cavity is from branches of the **maxillary**, the **ophthalmic**, and the **facial** arteries. The most important branch is the sphenopalatine artery (**Fig. 4**). The sphenopalatine artery anastomoses with the septal branch of the superior labial branch of the facial artery in the region of the vestibule. The submucous venous plexus is drained by veins that accompany the arteries.

The arterial supply of the medial and lateral walls of the nasal cavity can be summarized as follow (**Fig. 4**):

1. **Anterior ethmoidal artery** (a branch from the ophthalmic artery).
2. **Posterior ethmoidal artery** (a branch from the ophthalmic artery).
3. **Sphenopalatine artery** (a branch from the maxillary artery).
4. **Greater palatine artery** (a branch from the maxillary artery).
5. **Septal branch of the superior labial artery** (a branch from the facial artery).

The anterior part of the nasal septum is the site (**Kiesselbach area**) of an anastomotic arterial plexus involving all five arteries supplying the septum (**Fig. 4**). The external nose receives blood from first and fifth arteries listed plus nasal branches of the infra-orbital artery and the lateral nasal branches of the facial artery.

Venous Drainage of the Nasal Cavity

A rich **submucosal venous plexus,** deep to the nasal mucosa, provides venous drainage of the nose via the sphenopalatine, facial, and ophthalmic veins. The plexus is an important part of the body's thermoregulatory system, exchanging heat and warming air before it enters the lungs.

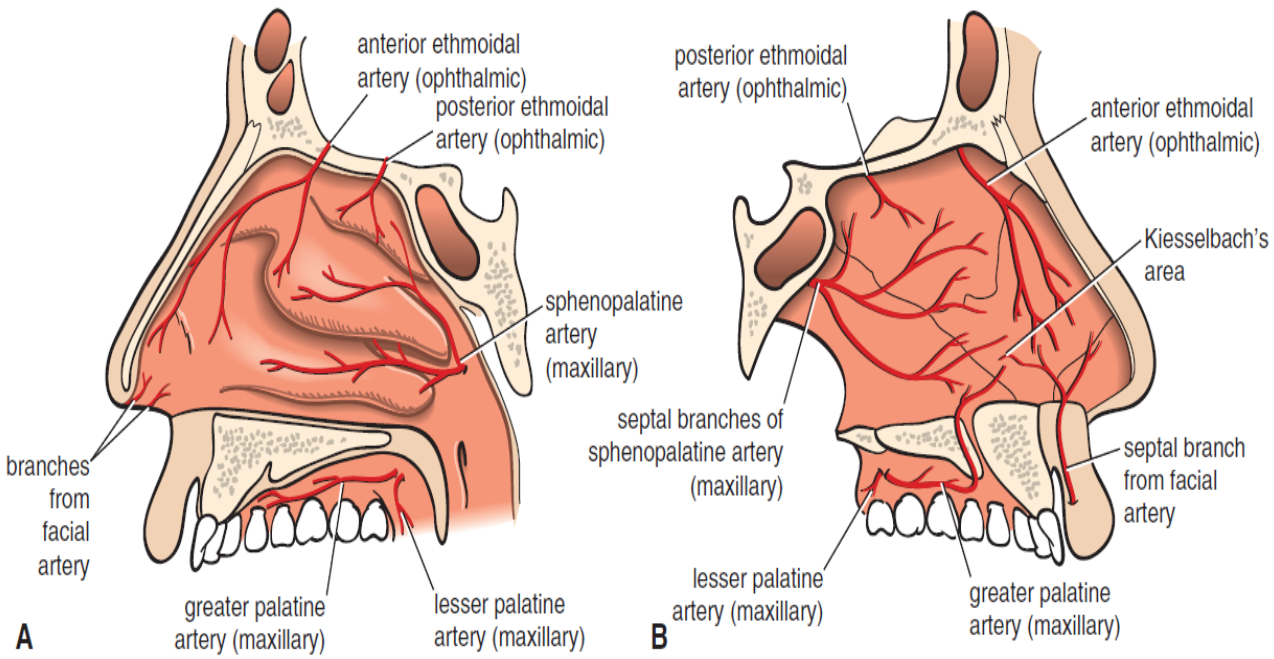

FIGURE 4: **A.** Lateral wall of nasal cavity showing the arterial supply of the mucous membrane. **B.** Nasal septum showing the arterial supply of the mucous membrane.

Lymph Drainage of the Nasal Cavity

The lymph vessels draining the vestibule end in the **submandibular nodes**. The remainder of the nasal cavity is drained by vessels that pass to the **upper deep cervical nodes**.

The Paranasal Sinuses

The paranasal sinuses are cavities found in the interior of the maxilla, frontal, sphenoid, and ethmoid bones (**Fig. 5**). They are lined with mucoperiosteum and filled with air; they communicate with the nasal cavity through relatively small apertures. The maxillary and sphenoidal sinuses are present in a rudimentary form at birth; they enlarge appreciably after the eighth year and become fully formed in adolescence.

Drainage of Mucus and Functions of Paranasal Sinuses

The mucus produced by the mucous membrane is moved into the nose by ciliary action of the columnar cells. Drainage of the mucus is also achieved by the **siphon action** created during the blowing of the nose. The function of the sinuses is to act as resonators to the voice; they also reduce the weight of the skull. When the apertures of the sinuses are blocked or they become filled with fluid, the quality of the voice is markedly changed.

➢ Maxillary Sinus

The maxillary sinus is pyramidal in shape and located within the body of the maxilla behind the skin of the cheek (**Fig. 5**). The roof is formed by the floor of the orbit, and the floor is related to the roots of the premolars and molar teeth. The maxillary sinus opens into the middle meatus of the nose through the hiatus semilunaris (**Fig. 5**).

➢ Frontal Sinuses

The two frontal sinuses are contained within the frontal bone (**Fig. 5**). They are separated from each other by a bony septum. Each sinus is roughly triangular, extending upward above the medial end of the eyebrow and backward into the medial part of the roof of the orbit. Each frontal sinus opens into the middle meatus of the nose through the infundibulum (**Fig. 2**).

➢ Sphenoidal Sinuses

The two sphenoidal sinuses lie within the body of the sphenoid bone (**Fig. 5**). Each sinus opens into the sphenoethmoidal recess above the superior concha.

➢ Ethmoid Sinuses

The ethmoidal sinuses are anterior, middle, and posterior and they are contained within the ethmoid bone, between the nose and the orbit (**Fig. 5**). They are separated from the latter by a thin plate of bone so that infection can readily spread from the sinuses into the orbit. The anterior sinuses open into the infundibulum; the middle sinuses open into the middle meatus, on or above the bulla ethmoidalis; and the posterior sinuses open into the superior meatus.

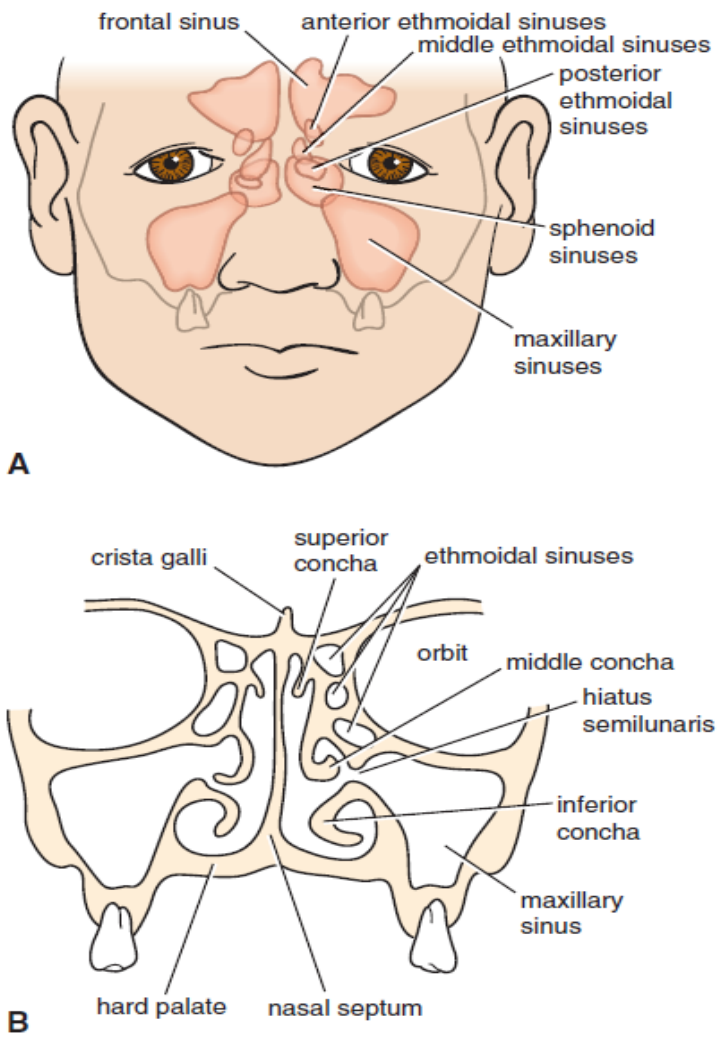

FIGURE 5: **A.** The position of the paranasal sinuses in relation to the face. **B.** Coronal section through the nasal cavity showing the ethmoidal and the maxillary sinuses.

Clinical Notes

Foreign bodies in the nose are common in children. It should be remembered that the nasal septum is rarely situated in the midline. A severely deviated septum may interfere with drainage of the nose and the paranasal sinuses.

✓ Trauma to the Nose

Fractures involving the nasal bones are common. Blows directed from the front may cause one or both nasal bones to be displaced downward and inward. Lateral fractures also occur; the nasal septum is usually involved.

✓ Nose Bleeding

Epistaxis, or bleeding from the nose, is a frequent condition. The most common cause is nose picking. The bleeding may be arterial or venous, and most episodes occur on the anteroinferior portion of the septum.

✓ Infection of the Nasal Cavity

Infection of the nasal cavity can spread in a variety of directions. The paranasal sinuses are especially prone to infection. Organisms may spread via the nasal part of the pharynx and the auditory tube to the middle ear. It is possible for organisms to ascend to the meninges of the anterior cranial fossa, along the sheaths of the olfactory nerves through the cribriform plate, and produce meningitis.

✓ Sinusitis and the Examination of the Paranasal Sinuses

Infection of the paranasal sinuses is a common complication of nasal infections. Rarely, the cause of maxillary sinusitis is extension from an apical dental abscess. The frontal, ethmoidal, and maxillary sinuses can be ***palpated clinically*** for areas of tenderness. The frontal sinus can be examined by pressing the finger upward beneath the medial end of the superior orbital margin. Here, the floor of the frontal sinus is closest to the surface. The ethmoidal sinuses can be palpated by pressing the finger medially against the medial wall of the orbit. The maxillary sinus can be examined for tenderness by pressing the finger against the anterior wall of the maxilla below the inferior orbital margin; pressure over the infraorbital nerve may reveal increased sensitivity.

References

1. **Snell RS. Clinical Anatomy by Regions. 9th edition. Philadelphia, PA: Lippincott Williams & Wilkins, 2012.**
2. **Keith LM: Clinically Oriented Anatomy, 7th edition. Wolters Kluwer, 2014.**