

## **SERIAL EXTRACTION**

Serial extraction involves the timed extraction of primary and, ultimately, permanent teeth to relieve severe crowding and to guide the erupting permanent teeth into a more favorable position. It is better termed it 'Guidance of Eruption' or 'Guidance of Occlusion'.

Commonly at 7-8 years of age the maxillary and mandibular central incisors have erupted, but there is inadequate space in anterior segments to allow normal eruption and positioning of lateral incisors. In some cases, mandibular lateral incisors have already erupted but they are usually lingually positioned and rotated. The same is with the maxillary lateral incisors. The orthodontist has four options:

- Wait for growth to provide more space and re-evaluate later.
- Expansion of the dental arch. However, the stability of expansion may be compromised by the insufficient alveolar basal bone.
- Cement a transpalatal or lingual bar to preserve the Leeway space for later on.
- Serial extraction can reduce crowding and irregularity during the mixed dentition.

### **HISTORY**

Bunon (1743) made the first reference to the extraction of deciduous teeth to achieve a better alignment of permanent teeth. In 1929, Kjellgren of Sweden first used the term 'serial extraction'. In the 1940s, the technique was popularised in the United States by Nance who is known as the Father of serial extraction.

It was advocated originally as a method to treat severe crowding by their own dentists without or with only minimal use of appliance therapy, thus minimizing demands upon the orthodontic service.

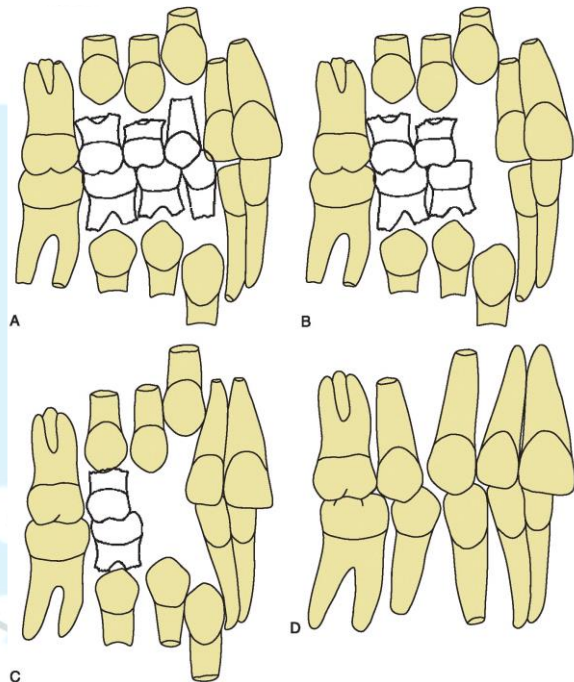
Although serial extraction makes later comprehensive treatment easier and often quicker, by itself it almost never results in ideal tooth position or closure of excess space. Also, the patients must be chosen carefully and supervised carefully as they develop.

## PROCEDURE

There is no fixed technique to be followed while carrying out serial extractions. Different authors have given different sequences for following guidance of occlusion. Some of the most common and accepted sequences are Tweed's, Dewel's, Nance's, and Grewe's methods. Careful diagnosis and continuous re-evaluation during the course of treatment is mandatory to achieve required results. However, based on the usual eruption sequence of teeth when the first premolar is ahead of the canine, there are several stages:

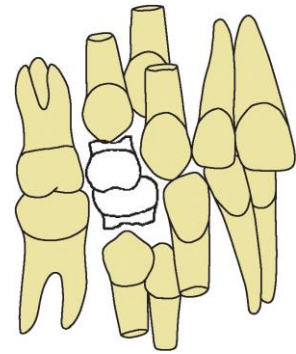
1. Extraction of primary lateral incisors as permanent central incisors erupt, if necessary. Most often this occurs spontaneously.

2. Extraction of primary canines as permanent laterals erupt at 8 to 9 years of age to allow eruption and alignment of permanent incisors. As the permanent teeth align without any appliances in place, there is usually some lingual tipping of the lower incisors, and overbite often increases during this stage. But this does not pose a problem because labio-lingual displacements are better resolved than rotational displacements.



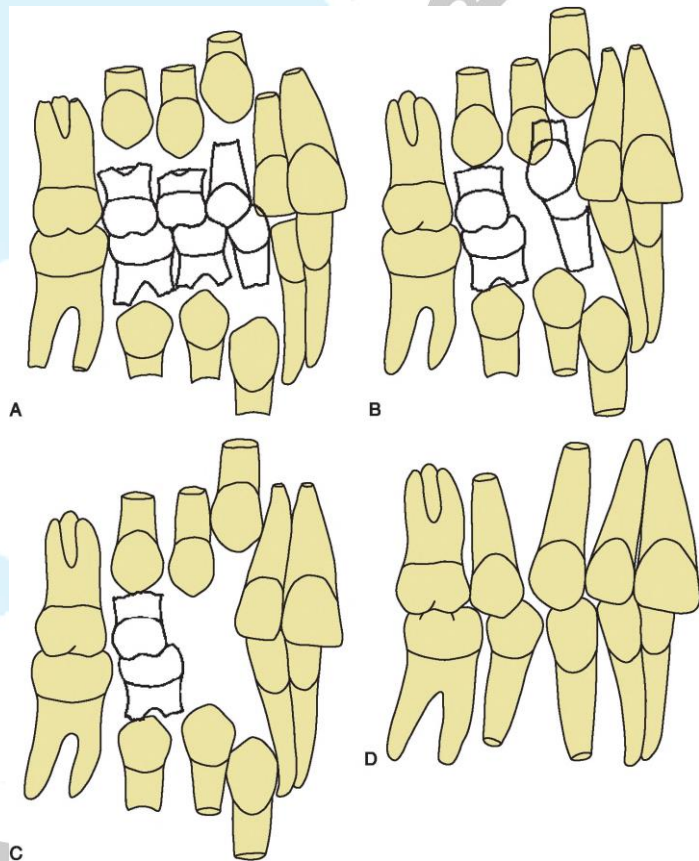
3. Extraction of primary first molars 6 to 12 months before their normal exfoliation time when there is one half or two-third root formation of the first premolar usually between 9 to 10 years of age. This is done to encourage first premolars to erupt ahead of permanent canines, so that they can be extracted and permit canines to move distally into the space.
4. Extraction of first premolars, just as they emerge through the mucosa after checking that all other teeth are present and sound and that the permanent canines are mesially inclined.
5. After the first premolar has been extracted, the second primary molars should exfoliate normally. The premolar extraction spaces close partially by mesial drift of the second premolars and permanent first molars but largely by distal eruption of the canines. If serial extraction is not followed by mechanotherapy, ideal alignment, root positioning, correct rather than deep overbite, and space closure usually are not achieved.

In the lower arch, the canines often erupt before the first premolars, which causes the canines to be displaced facially. If the primary first molar is extracted early and the first premolar still does not erupt before the canine, this can lead to impaction of the premolar that requires later surgical removal. If radiographic examination shows that it is obvious that the canine will erupt before the premolar, to avoid this complication:



- Deciduous first molars are extracted and first premolars surgically enucleated at the same time. If possible, however, enucleation should be avoided because the erupting premolar brings alveolar bone with it. Early enucleation can leave a bone defect that persists.

- The primary canines are retained, and the primary first molars are extracted to speed up the premolar eruption and cause them to enter the arch before the canines, but this has a minimal effect on relief of incisor crowding and in many patients with severe crowding, the primary canines are lost to ectopic eruption of the laterals and cannot be maintained. The first premolars are extracted as they emerge through the mucosa and the deciduous canines are also removed allowing the permanent



canines to erupt distally. This technique can also be used to prevent lingual tipping of the lower incisors and deepening of the bite.

- Deciduous first molars are extracted first, and 6 months later deciduous second molars are extracted. A lingual bar prevents permanent first molars from migrating mesially. Unerupted first premolars move distally into the alveolar bone as the canine erupts. When first premolar erupts, it is extracted.



## RATIONALE:

- If primary teeth are extracted prematurely 1½ years or more before the time of normal exfoliation, the eruption of the permanent teeth will be delayed. Conversely, the eruption rate can be accelerated if the primary tooth overlying the permanent tooth is extracted less than a year before the time of normal exfoliation.
- Crowded teeth adjacent to an extraction site tend to align themselves.
- Intercanine width increases in the mandible up to 9 years of age by an average of 3mm. In maxilla, it increases up to 12 years in females and 16 years in males by about 4.5mm.
- Serial extraction allows the teeth to erupt over the alveolus and through keratinized tissue, rather than being displaced buccally or lingually.
- It is normal for children to have more prominent lips which flatten out with growth, so lip fullness is not a reliable criterion for extraction in the mixed dentition. Also, the growth of the nose and chin are unpredictable and continue to grow long after other facial parts. Therefore, extraction in an attempt to end with straight profile may actually end with a concave one.

## INDICATIONS

Serial extraction is directed toward severe dental crowding. Typically, Class I malocclusion with an arch size-tooth size deficiency of 5mm or more per quadrant (10mm per arch), normal eruption sequence as assessed radiographically and a skeletal growth pattern within normal limits.

The average width of first premolar is 7-8mm. After serial extraction, incisors tend to drift lingually and the posterior teeth tend to drift mesially to some extent, leading to 2-3mm of space closure in each quadrant. Thus the remaining 5mm is available for resolution of crowding.

If the crowding is severe, little space will remain after the teeth are aligned, which means there will be little tipping and uncontrolled movement of the adjacent teeth into the extraction sites. If the initial crowding is smaller, more residual space must be expected.

It is unwise for a non-specialist to start serial extraction in a child who has a skeletal problem (Class II or III) because the closure of extraction spaces would be affected by the treatment of the skeletal problem. Sometimes serial extraction can be used only in the maxillary arch of Class II maxillary alveolodental protrusion patients.

## CONTRAINDICATIONS

1. Mild to moderate crowding less than 4mm per quadrant.
2. Class II division 2 and Class III malocclusions.
3. Spaced dentition.
4. Congenital absent second premolars.
5. Extensive caries involving permanent first molars, which cannot be conserved.
6. Open bite, deep bite, and crossbite which should be corrected first.

## ADVANTAGES

1. More physiologic treatment as teeth are guided into normal positions using physiologic forces.
2. Duration of fixed treatment is reduced.
3. Health of investing tissues is preserved.
4. Lesser retention period is required.
5. Results are more stable.

## DISADVANTAGES

1. Long-term procedure that requires thorough knowledge of growth, development, eruption sequence and calcification of permanent teeth. No single approach can be universally applied.
2. It is done as intercanine growth is occurring and hence it is difficult to assess accurately how crowded the dentition will be.
3. Treatment time is prolonged over 2-3 years.
4. Psychological trauma to the child because of repeated extractions.
5. Patient cooperation is very important.
6. Tendency to develop tongue thrust as extraction spaces close gradually.
7. Tendency to deepen the bite because of lingual tipping of incisors.
8. Residual spaces can remain between the canine and second premolar.
9. Some amount of fixed appliance therapy is usually required at the end of serial extraction.

## BORDERLINE CROWDING CASES

Since serial extraction is only for patients with severe crowding, and early expansion offers little advantage over expansion during later comprehensive treatment, the best approach to moderately crowded and irregular teeth during the mixed dentition is to maintaining Leeway space increases the chance of successful non-extraction treatment if space is adequate or borderline. Lingual and palatal arches are needed.

Also, extraction of deciduous canines may avoid more complicated treatment later in these cases:

1. To prevent crowded erupting upper lateral incisors from being forced palatally into a crossbite and its apex palatally positioned, making later correction more difficult.
2. To provide space for appliance therapy for correction of an instanding upper lateral incisor.
3. To spontaneously align crowded mandibular incisors where one incisor has been pushed through the labial plate of bone with a compromised labial periodontal attachment.
4. In Class III malocclusion by extraction of the mandibular deciduous canines
5. To improve the position of a displaced permanent canine and to decrease the chance of canine impaction.

## REFERENCES:

- Graber LW, Vig KWL, Huang GJ, Fleming PS. (2023): Orthodontics: current principles and techniques. 7<sup>th</sup> ed. Elsevier Health Science.
- Littlewood SJ, Mitchell L. (2019): An introduction to orthodontics. 5<sup>th</sup> ed. Oxford University Press.
- Phulari BS. (2011): Orthodontics: principles and practice: JP Medical Ltd.
- Proffit WR, Fields HW, Larson BE, Sarver DM. (2019): Contemporary orthodontics 6<sup>th</sup> ed. Philadelphia: Mosby.
- Singh G. (2015): Textbook of orthodontics. 3<sup>rd</sup> ed. JP Medical Ltd.

## YouTube LINKS:

**Channel:** [www.youtube.com/c/akramadp](http://www.youtube.com/c/akramadp)

**Lecture:** <https://youtu.be/t5qC2lufq4Q>