

Immunohistochemical Expression of HER2/neu Receptors in Iraqi Patients with Endometrioid Carcinoma

ZINAH HUSSEIN ABD ALI¹, FARAH FALAH HASSAN², ALAA QASIM YAHYA³

ABSTRACT

Introduction: With the advent of era of targeted cancer therapy, the serious side effects of chemoradiotherapy have been minimised. Considering the success story of anti-HER2/neu drugs in breast cancer oncology, the present study was conducted. The study evaluates the immunohistochemical expression of HER2/neu in endometrioid cancer among Iraqi patients.

Aim: To assess the immunohistochemical expression of HER2/neu in endometrioid carcinoma of uterus and to find the relationship of this expression with FIGO stage and grade and with patient age.

Materials and Methods: In this cross sectional study, formalin-fixed, paraffin-embedded tissue blocks of 62 hysterectomy specimens that were diagnosed as endometrioid carcinoma in the teaching laboratories in the Medical City complex, Baghdad were retrieved and assessed by three pathologists using the

same scoring system for HER2/neu as in breast cancer with positivity regarded as +2 or +3. Statistical correlation using Chi-square test analysis was done.

Results: Out of 62 cases of endometrioid carcinoma, 30 (48.38%) were positive for HER2/neu and a significant statistical relationship between expression of this marker with histological grade and patient age was seen. The cases which were immunohistochemically positive for HER2/neu were closely associated with high grade morphology and patients younger than 40-year-old.

Conclusion: Endometrioid carcinoma is a type of endometrial adenocarcinoma commonly having a well differentiated morphology (Grade I) and low stage at presentation. The study concludes that young patients with a high grade endometrioid carcinoma would hopefully benefit from the application of targeted anti-HER2/neu therapy in future.

Keywords: Endometrioid carcinoma, Immunohistochemistry, Post menopausal

INTRODUCTION

Endometrial adenocarcinoma is a common malignancy of the female genital tract that arises from glandular cells of the inner lining layer of uterine corpus [1]. The most common histological type is endometrioid adenocarcinoma, representing 75-80% of all cases [2-4] and its incidence is increasing [5]. Based on pathogenesis, it is regarded as an oestrogen-associated type I carcinoma and endometrial hyperplasia is the histological precursor [6]. Previously endometrial hyperplasia was divided into two categories, simple hyperplasia and complex hyperplasia each with or without atypia according to both architecture and cytology of endometrial glands [7]. However, in the latest World Health Organization classification published in 2014 endometrial hyperplasia is divided into hyperplasia without atypia and atypical hyperplasia/endometrioid intraepithelial neoplasia [8].

Uterine bleeding in a post menopausal woman is the main presenting symptom of endometrial carcinoma [9]. After establishment of diagnosis, any endometrial carcinoma should be graded and clinically staged for appropriate management [10]. HER2/neu oncogene activation which leads to overexpression of HER2/neu gene has been established in many human malignancies, including breast, colon, gastric, oesophageal, ovarian, and endometrial; for some of these cancers, anti-HER2/neu therapies have become a mainstay therapy. HER2/neu expression can be detected by immunohistochemistry [11].

The present study was conducted to detect the expression of this oncogene in the most common type of endometrial carcinoma among Iraqi population in an attempt to apply a targeted anti-HER2/neu therapy for endometrioid carcinoma in future.

MATERIALS AND METHODS

In this retrospective study, formalin-fixed, paraffin-embedded tissue blocks of 62 hysterectomy specimens that were diagnosed

as endometrioid carcinoma were retrieved from (March 2016 to January 2017) archives in the pathology department of teaching laboratories in Medical City complex at Bagdad. From each block representing endometrial mass, two histological sections were done for routine haematoxylin and eosin staining and for immunohistochemical staining with HER2/neu by application of the same standardised immunohistochemical protocols used for HER2/neu expression in breast cancer [12]. For detection of HER2/neu antigen polyclonal rabbit anti-human c-erb-2 oncoprotein (Code A0485) manufactured by DAKO with a dilution of (1:1000) was used. The antibody was used with the buffer supplied by the manufacturer and the primary antibody was diluted and, after incubation for 30 minutes, visualisation of antigen was done with envision detection kit and after counterstaining with haematoxylin and eosin the sections were cover slipped. Positive and negative controls were included with each run, positive control was breast tissue known to be positive for HER2/neu and negative control was prepared by omitting the primary antibody. Appropriate grading and staging was done for each case according to the FIGO grading and staging system that is widely used now-a-days for evaluation and reporting endometrial carcinoma [9,10]. Age of women was the only available clinical information that was extracted from the patient records. Regarding HER2/neu immunohistochemical interpretation, this study used the previously laid down HER2/neu scoring criteria for breast carcinoma. A 3+ was rendered if complete, strong membranous staining was present in more than 10% of tumour cells and 2+ if complete, moderately intense staining was seen in more than 10% of tumour cells [13].

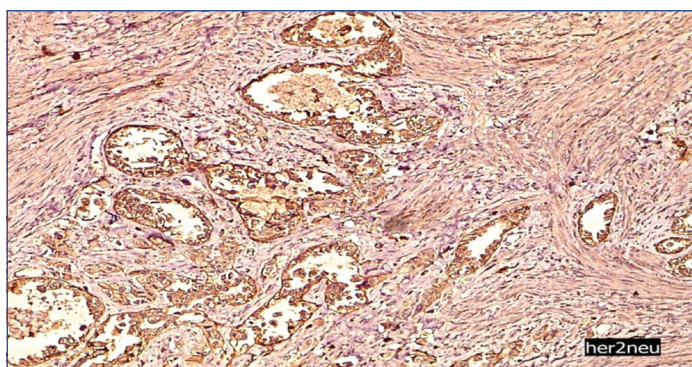
All histopathological observations were done by three pathologists using a light microscope (Leica DM500). This study was approved by the ethical committee of the national centre

for educational laboratories (ethical clearance file number 32/18) and done in accordance with the institutional policy in which patient consent was taken at the beginning of consultation to teaching laboratories for any future retrospective studies. Statistical analysis was done using Chi-square test analysis. Photomicrographs were taken for this study using the camera (Leica Icc 50E).

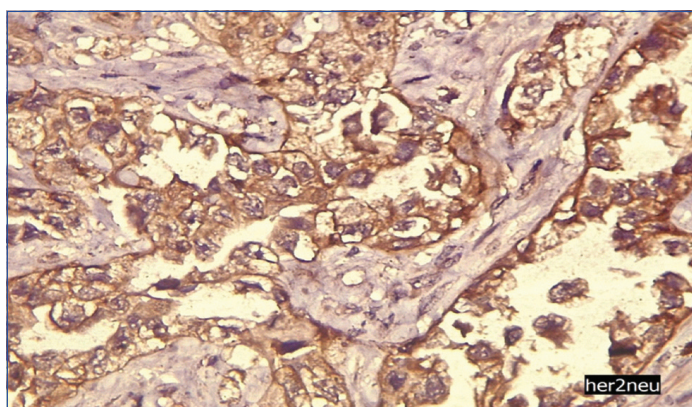
RESULTS

This study enrolled 62 cases of endometrioid carcinoma, the age range from 35 to 72 years with a mean age of 56.16 years. According to FIGO grading system 40 (64.51%) were grade I, 10 (16.12) were grade II, 12 (19.3%) were grade III tumours. According to FIGO staging system, 44 (70.96%) were stage IA, 8 (12.90%) were stage IB, 4 (6.45%) were stage II, 6 (9.67%) were stage III tumours.

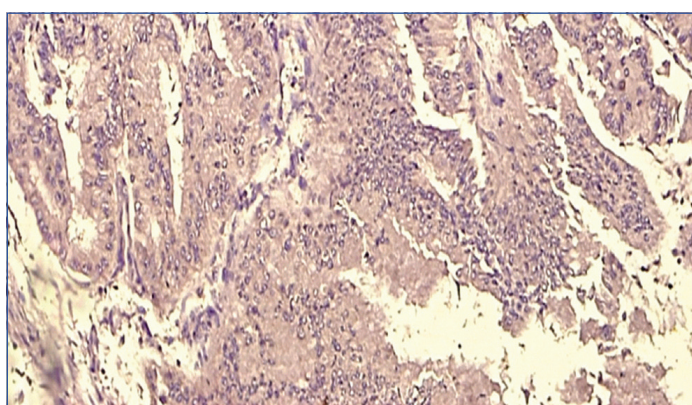
Out of 62 cases 30 (48.38%) were positive for HER2/neu [Table/Fig-1,2] and the remaining cases were negative [Table/Fig-3].



[Table/Fig-1]: Histological section of grade I endometrioid carcinoma showing positive membranous staining pattern for HER2/neu antibody (x100).



[Table/Fig-2]: Histological section of grade II endometrioid carcinoma showing positive membranous staining pattern for HER2/neu antibody (x400).



[Table/Fig-3]: Histological section of grade II endometrioid carcinoma showing negative staining for HER2/neu antibody (x200).

The distribution of HER2/neu immunohistochemical status according to FIGO stage of endometrial carcinoma is shown in [Table/Fig-4].

Stage	HER2/neu status			
	Negative		Positive	
	No. of cases	Percentage %	No. of cases	Percentage %
IA	28	63.6%	16	36.4%
IB	0	0%	8	100.0%
II	0	0%	4	100.0%
III	4	66.7%	2	33.3%

[Table/Fig-4]: Distribution of HER2/neu immunohistochemical status according to FIGO stage of endometrioid cancer.

Association between FIGO grading of endometrioid cancer and HER2/neu immunohistochemical status revealed a highly significant statistical relationship with p-value<0.001 [Table/Fig-5].

Grade	HER2/neu status				p-value
	Negative		Positive		
	No. of cases	Percentage %	No. of cases	Percentage %	
I	28	70.0%	12	30.0%	<0.001
II	4	40.0%	6	60.0%	
III	0	0%	12	100.0%	

[Table/Fig-5]: Association between FIGO grading of endometrioid cancer and HER2/neu immunohistochemical status (Chi-square test).

Association between patient age and HER2/neu immunohistochemical status revealed a significant statistical relationship with p-value 0.002 [Table/Fig-6].

Age	HER2/neu status				p-value
	Negative		Positive		
	No. of cases	No. of cases	No. of cases	Percentage %	
<45 years	0	0%	8	100.0%	0.002*
≥45 years	32	59.3%	22	40.7%	

[Table/Fig-6]: Association between patient age and HER2/neu immunohistochemical status (Chi-square test).

DISCUSSION

International Federation of Gynaecology and Obstetrics (FIGO) established a surgical staging and grading system widely used nowadays for endometrial cancer and carries an important prognostic implication in which histological grading relies on both architectural and nuclear features in three tier system while the staging system relies mainly on depth of myometrial and adjacent structures or organ invasion [10]. Treatment is mainly surgical, the extent of which depends on the stage of disease [14,15]. In general, the prognosis of endometrioid carcinoma is favorable because over 80% of disease is diagnosed in the early stages [16].

Immunohistochemical expression of HER2/neu has been used most successfully in mammary cancer as a potent predictor to select patients who will most likely respond to anti-HER2 therapies such as trastuzumab [17]. There were limited studies worldwide on HER2/neu expression in endometrial cancer in general and endometrioid carcinoma in particular (unlike in breast cancer) and no such Iraqi study was done earlier.

HER2 is a 185-kDa member of the human epidermal growth factor receptor (HER) family of transmembrane tyrosine kinase receptor, it is also known as HER2/neu, ERBB2, and CD340 [11,12]. The HER family (to which HER2/neu belong) consists of three other tyrosine kinase receptors (HER1/EGFR, HER3, and HER4) [13,18].

There are no well established standardised criteria currently available for the immunohistochemical methods (i.e., tissue handling/fixation, antibodies used, controls, and artifacts) and for interpretation and

scoring of HER2/neu immunohistochemical results. In the majority of studies and in this study, the original FDA approved criteria (previous breast HER2/neu scoring criteria based on more than 10 years experience in breast cancer) with positivity accepted as 3+ and +2 were used [13].

The present study showed that the mean age of endometrioid carcinoma was in the sixth decade of life which agreed with study done by Sharon N et al., and the majority of endometrioid cancers were well differentiated grade I which agreed with an Iraqi study done by the study of Sharon N et al., and Abeer et al., [19,20]. This study showed that 48.38% of endometrioid carcinoma were immunohistochemically positive for HER2/neu suggestive of its role in the pathogenesis of endometrioid carcinoma. There is a great variation in the reported percentages of HER2/neu overexpression in endometrioid carcinoma ranging between 1% to 47% [13,21-24]. There are many factors accounting for this difference such as variations in sample size, methods of testing, detection systems used, immunohistochemical interpretation and scoring criteria with interobservational variations.

The current study also showed that there is a significant statistical relationship between HER2/neu immunohistochemical results and histological grade in which the expression is closely associated with a high grade cancer. Variable results have been reported in the literature in which some studies are in congruence with current results [23,25] while other studies differ [22,26]. Such wide variations in the reported results again are due to lack of standardised protocols of testing HER2/neu in endometrial cancer. Histological grade is regarded as one of the prognostic factors applied in clinical decisions regarding treatment [27].

A significant statistical relationship between the patient age and HER2/neu immunohistochemical results were seen in this study in which the positivity closely associated with patients younger than 40 years. However, Srijaipracharoen S et al., failed to find such an association [27]. Because the cancer treatment field progressed to an era of targeted therapy which has the advantage of overcoming undesirable serious side effects of chemo radiotherapy, search for therapeutic targets by using accurate and reliable immunohistochemical test especially for common cancers worldwide is the first critical step. Our results demand standardisation of HER2/neu testing in endometrioid cancer is mandatory step in order to accurately identify patients who might benefit from HER2/neu-targeted therapy, and further for prognostication because most studies in the literature proved that both HER2/neu over expression and amplification are associated with poor prognosis and low overall patient survival in endometrial carcinoma [13].

A recent study on the use of (Trastuzumab for Gastric Cancer) shows the guidelines of immunohistochemical interpretation in a biologically and pathogenically unrelated different tumour category and couldn't be simply applied, because this may lead to false interpretation of HER2/neu immunohistochemical results [28].

This is the first study in Iraq and may serve as the starting point towards the awareness about the probable use of HER2/neu targeted therapy in endometrioid carcinoma. However, large scale future immunohistochemical studies as well as genetic studies on HER2/neu amplification associated with clinical therapeutic response to targeted drugs in endometrioid carcinoma and establishing the specific HER2/neu scoring criteria and testing guidelines in endometrial carcinoma are required.

LIMITATION

The present study was conducted in a single centre with small number of cases included in the study. There was limited clinical

information about cases present in the records. In addition, no standardised testing protocols were available on HER2/neu expression in endometrioid carcinoma.

CONCLUSION

HER2/neu expression in endometrioid carcinoma is significantly associated with higher grade of tumour and younger age of patients. The study concludes that young patients with a high grade endometrioid carcinoma may hopefully benefit from the application of targeted anti-HER2/neu therapy in future.

REFERENCES

- [1] Di Cristofano A and Ellenson L. Endometrial carcinoma. *Annu Rev pathol.* 2007;2:57-65.
- [2] Nirmala S, Rekha B, Rajeev A, Suman N. Endometrioid endometrial adenocarcinoma in a premenopausal woman with multiple organ metastas. *Indian J Med Paediatr Oncol.* 2009;30(2):80-83.
- [3] Gien L, Kwon J, D'Souza D, Radwan J, Hammond J, Sugimoto A et al. Brain metastases from endometrial carcinoma: A retrospective study. *Gynecol Oncol.* 2004;93:524-28.
- [4] Neto A, Gupta D, Broaddus R and Malpica A. Endometrial endometrioid adenocarcinoma in a premenopausal woman presenting with metastasis to bone: a case report and review of the literature. *Int J Gynecol Pathol.* 2002;21:281-84.
- [5] Alexandra L, Carien C, Nadeem A and Emile D. Endometrial cancer. *Lancet.* 2016;387(10023):1094-108.
- [6] Felix A, Weissfeld J, Stone R, Bowser R, Chivukula M, Edwards R, et al. Factors associated with Type I and Type II endometrial cancer. *Cancer Causes Control.* 2010;21:1851.
- [7] Lacey J, Sherman M, Rush B, Ronnett B, Ioffe O, Duggan M, et al. Absolute risk of endometrial carcinoma during 20-year follow-up among women with endometrial hyperplasia. *J Clin Oncol.* 2010;28:788-92.
- [8] Emons G, Beckmann M, Schmidt D, Mallmann P and for the Uterus commission of the Gynecological Oncology Working Group (AGO). New WHO classification of endometrial hyperplasia. 2015;75(2):135-36.
- [9] Denschlag D, Ulrich U, Emons G. The Diagnosis and treatment of endometrial cancer progress and controversies. *Dtsch Arztebl Int.* 2011;108(34-35):571-77.
- [10] Wen H, Zhang L. Effect of pelvic lymphadenectomy on prognosis of endometrial carcinoma. *Zhonghua Fu Chan Ke Za Zhi.* 2004;39(3):152-55. (pubMed)
- [11] Khasraw M, Bell R. Primary systemic therapy in HER2-amplified breast cancer: A clinical review. *Expert Rev Anticancer Ther.* 2012;12:1005-13.
- [12] Emad A, Sarah E, John M, Merdol I, Jane S, Pauline J, et al. Updated UK Recommendations for HER2 assessment in breast cancer. *J Clin Pathol.* 2014;0:1-7.
- [13] Natalia B, Dana M, Alessandro D. HER2/neu in endometrial cancer: A promising therapeutic target with diagnostic challenges. *Archives of Pathology & Laboratory Medicine.* 2014;138(3):343-50.
- [14] Tufun B, Sema O, Saki O, Turkan A. Coexisting endometrial carcinoma in patient with a preoperative diagnosis of atypical hyperplasia. *The Journal of Obs and Gynae Research.* 2004;30(3):200.
- [15] Santin A, Bellone S, O' Brien T, Pecorelli S, Cannon M and Roman J. Current treatment options for endometrial cancer. *Expert Rev Anticancer Ther.* 2004;4(4):679-89.
- [16] Shah C, Johnson E, Everett E, Tamimi H, Greer B, Swisher E, et al. Does size matter? Tumour size and morphology as predictors of nodal status and recurrence in endometrial cancer. *Gynecol Oncol.* 2005;99:564-70.
- [17] Baselga J. Treatment of HER2-overexpressing breast cancer. *Ann Oncol.* 2010;21 suppl 7: 36-40.
- [18] Citri A, Yarden Y. EGF-ERBB signalling: Towards the systems level. *Nat Rev Mol Cell Biol.* 2006;7:505-16.
- [19] Sharon N, Zeina G, Nadia I, Ida A, Gillian T, Lisa B, et al. Endometrial endometrioid adenocarcinoma: A pathologic analysis of 827 consecutive cases. *Am J Clin Pathol.* 2008;129:110-14.
- [20] Abeer H, Wahda M. Immunohistochemical detection of oestrogen receptor α in endometrial carcinoma. *Ann. Coll. Med. Mosul.* 2010;36(1 & 2):130-37.
- [21] Fleming G, Sill M, Darcy K, Mc Meekin D, Thigpen J, Adler L, et al. Phase II trial of trastuzumab in women with advanced or recurrent, HER2-positive endometrial carcinoma: A Gynecologic Oncology Group study. *Gynecol Oncol.* 2010;116(1):15-20.
- [22] Gul A, Keser S, Barisik N, Kandemir N, Cakir C, Senu S, et al. The relationship of cerb B 2 expression with estrogen receptor and progesterone receptor and prognostic parameters in endometrial carcinomas. *Diagn Pathol.* 2010;5:13.
- [23] Morrison C, Zanagnolo V, Ramirez N, Cohn D, Kelbick N, Copeland L, et al. HER-2 is an independent prognostic factor in endometrial cancer: association with outcome in a large cohort of surgically staged patients. *J Clin Oncol.* 2006;24(15):2376-85.
- [24] Xu M, Schwartz P, Rutherford T, Azodi M, Santin A, Silasi D, et al. HER-2/neu receptor gene status in endometrial carcinomas: a tissue microarray study. *Histopathology.* 2010;56(2):269-73.

- [25] Grushko T, Filiaci V, Mundt A, Ridderstrale K, Olopade O, Fleming G. An exploratory analysis of HER-2 amplification and overexpression in advanced endometrial carcinoma: A Gynecologic Oncology Group study. *Gynecol Oncol.* 2008;108(1):3-9.
- [26] Halperin R, Zehavi S, Habler L, Hadas E, Bukovsky I, Schneider D. Comparative immunohistochemical study of endometrioid and serous papillary carcinoma of endometrium. *Eur J Gynaecol Oncol.* 2001;22(2):122-26.
- [27] Srijaipracharoen S, Tangjitgamol S, Tanvanich S, Manusirivithaya S, Khunrarong J, Thavaramara T, et al. Expression of ER, PR, and Her-2/neu in endometrial cancer: A clinicopathological study. *Asian Pacific J Cancer.* 2010;11(1): 215-20.
- [28] Albarello L, Pecciarini L, Doglioni C. HER2 testing in gastric cancer. *Adv Anat Pathol.* 2011;18(1):53-59.

PARTICULARS OF CONTRIBUTORS:

1. Senior Pathologist, Department of Pathology, Medical City, Baghdad, Iraq.
2. Lecturer, Department of Pathology, Collage of Medicine, Kerbela University, Baghdad, Iraq.
3. Lecturer, Department of Pathology, Al Kindy College of Medicine, Baghdad, Iraq.

NAME, ADDRESS, E-MAIL ID OF THE CORRESPONDING AUTHOR:

Alaa Qasim Yahya,
Maghrib Street, Baghdad, Iraq.
E-mail: alaakasim1983@yahoo.com

Date of Submission: **May 26, 2018**

Date of Peer Review: **Jul 13, 2018**

Date of Acceptance: **Jul 25, 2018**

Date of Publishing: **Nov 01, 2018**

FINANCIAL OR OTHER COMPETING INTERESTS: None.