

See discussions, stats, and author profiles for this publication at: <https://www.researchgate.net/publication/334794722>

Motivational efficacy of lasers on marrow haemopoetic cells

Article in *Journal of Physics Conference Series* · July 2019

DOI: 10.1088/1742-6596/1279/1/012075

CITATION

1

READS

20

4 authors, including:



Mohammed Sh. Aledanni
University of Baghdad

55 PUBLICATIONS 23 CITATIONS

SEE PROFILE

Some of the authors of this publication are also working on these related projects:



Prevalence of low back pain among obese patients attending obesity research and therapy unit in Al-Kindy medical college [View project](#)



Best plate position for midshaft clavicle fracture fixation [View project](#)

PAPER • OPEN ACCESS

Motivational efficacy of lasers on marrow haemopoetic cells

To cite this article: Kasim O. H. Ali *et al* 2019 *J. Phys.: Conf. Ser.* **1279** 012075

View the [article online](#) for updates and enhancements.



IOP | ebooks™

Bringing you innovative digital publishing with leading voices to create your essential collection of books in STEM research.

Start exploring the [collection](#) - download the first chapter of every title for free.

Motivational efficacy of lasers on marrow haemopoetic cells

Kasim O. H. Ali^{1*}, Ihsan, F. Rostum² and Mohammed S. Al – Idani³

¹College of Medicine , Al-Muthanna University, Iraq

²College of Dentistry, Al- Muthanna University, Iraq

³Al- Kindy College of Medicine, Baghdad University, Iraq

* E-mail: Kas702002@yahoo.com

Abstract: Lasers has been proved to increase tissue oxygenation, activate marrow progenitor cells, expanse the microcirculation, accelerate the restoration of functions, stimulate adaptation ability and stabilization of the hormonal status. The semisolid tissue present in the epiphysis of the bone where it's structure is spongy or cancellous is bone marrow and it formed about 4% of body weight , the marrow is composed of hemopoietic cells , however , the structure of the marrow is of both cellular and non – cellular components. The hemopoietic stem cells are responsible of producing white blood cells, red corpuscles, platelets in addition to the fibroblasts, macrophages, adipocytes, osteoblasts , osteocytes and osteoclasts, the current study aimed to detect the effects of lasers on the bone marrow. Twenty four adult New Zealand male rabbits were used in the study, they were divided into two groups with twelve rabbits each ; the first group was treated with He-Ne laser for ten days. the second group was treated with diode laser for ten days. Three rabbits from each group underwent bone marrow aspiration to detect the marrow status assessed by special laboratory investigation at the days "1, 7 ,14 & 21 " using " 18-ga " gauge needle introduced to the marrow cavity through a small hall done in the trochanteric fossa. Samples collected from animals of different groups examined haematologically using Wright's stain. Results of the hematological examinations revealed that low level laser application stimulates the bone marrow and induce the infiltration of the tissues with high numbers of blood cells which were formed by increase mitosis and haemopoiesis to great levels. Conclusions can be done that the irradiation of the marrow with the lasers regardless it's kind was very efficient to make the marrow of the adult rabbits which tend to be yellow in nature motivated and restore it's capability of producing of the hemopoietic stem cells and mature blood cells

1 Introduction

Reports indicated the laser light has various actions on human body cells [1], direct effect of laser lights on the cells and tissues may be regarding the inflammations, studies demonstrated that the direct response of the tissues to the laser in some cases may be as pro-inflammatory [2], immunostimulatory [3] and in other cases as anti-inflammatory [4].

Low level laser therapy L.L.L.T. used to reduce pain, inflammatory traction, edema, to improve wounds healing, to restore function and prevent tissue damage [5], literature reviewing revealed that the L.L.L.T. has a significant effect on cell cultures containing stem cells or other cell lines, creating high incidence of ATP, RNA, and DNA synthesis [6]. Lasers have positive impact on the bone marrow mesenchymal stem cells [7]

Experimental laser irradiation on bone marrow stem cells affect positively on the viability of mesenchymal stem cells and increase their proliferative activity without changing their morphology, increased their viability and the number of cells, the great incidence of fracture healing depends upon the marrow component's activity [8].

All of these facts made bone marrow a vital body tissue and essential for the scientists to search thoroughly for such an important value in case of trauma and fractures and looking for it's response towards low energy laser



therapy specially there is a serious need for such great clinical benefits specifically if an elderly victims subjected to trauma and or fractures.

2 Materials & Methods

Twenty-four male New Zealand rabbits were used in the current study; they were divided in to two groups with 12 animals each;

- group "a" irradiated with a He - Ne laser beam applied on the left thigh, the wave length of the laser was 632.8 nm , power 5 mW , for 10 minutes / session for 10 days.
- group " b" irradiated with a pulsed diode laser " window type" applied on the left thigh, the wave length of the laser was 904 nm , power 5 mW , for 10 minutes / session for 10 days .

Three rabbits from each group underwent bone marrow aspiration to detect the marrow status assessed by special laboratory investigation at the days "1, 7 ,14 & 21 " . Sites which can be used for the marrow aspiration may be the trochanteric fossa of the proximal femur , greater tubercle of the proximal humerus or the greater tubercle of the proximal humerus [9] , in the current study the trochanteric fossa of the proximal femur chosen.

The site of the operation prepared surgically and the animals anaesthetized with general anesthesia using a mixture of ketamine hydrochloride and Xylazin, a small incision in the skin over the fossa done using a surgical blade and a biopsy needle " 18-ga " hold in a manner to get a precise control ,introduced through the fossa. Biopsy needle is formed of a proximal collar , a hollow needle portion , a solid stylet fits the needle bore and a cap cover the proximal end to keep it sterile and easily handling , the needle placed medial to the greater trochanter within the femoral fossa, and directed toward the femoral shaft , a force was used to penetrate the cortical surface in a perpendicular line. The stylet pulled out and a syringe rinsed with 4% disodium- or dipotassium-EDTA was attached to the end of the biopsy needle to prevent or at least reduce clotting of the sample during collection, full suction was applied so that the blood flash seen , this step is very important to prevent hemo - dilution, then the contents of the syringe and needle were expelled onto glass slides. The incision done in the skin closed using stitches of silk and the animals placed under care. Two slides method was used for preparation of bone marrow smears ; the marrow sample placed on to glass slides so fast to prevent clotting of the sample , then the slide was tilted to make the blood pass away from the slide , another slide place on the first one in a perpendicular position to spread the marrow particles or spicules [10]

The marrow samples then stained with a special stain "Wright`s stain" which is most commonly used to stain marrow aspirate smears [11], to see the white blood cell, a red blood cell morphology, an abnormal granulocyte, lymphocyte or monocyte cells , this stain can be used effectively [12].

3 Results

Samples of aspirated bone marrow smears stained with wright`s stain at the first day of the irradiation with the lasers in the animals of both groups revealed that the marrow is a yellow one or seemed to be , there were a large number of adipocytes "fat cells" which were dominant and occupy a large space of the area , there were a little red blood cells, white blood cells and lymphocytes, Figure1.

Examination of the aspirated bone marrow smears seven days after irradiation with He – Ne laser in the animals of the first group revealed appearance of a large number of mesenchymal stem cells , proerythroblasts, myeloblasts and lymphoblast , adipose cells seen also.

The examination of the marrow smears obtained from the diode laser irradiated group for the same time revealed a large number of mesenchymal stem cells invade the smear , proerythroblasts cells indicating the steps of the development of the erythroblasts seen in the smear , myeloblasts and progranulocytes, lymphoblast, monoblasts and megakaryocytes.

Bone marrow smears after two weeks of irradiation with He- Ne laser in the animals of the first group revealed appearance of steps of the development of the erythroblasts . Basophilic, neutrophilic and eosinophilic myelocytes , some lymphocytes and megakaryocytes.

Examination of the smears obtained from the animals irradiated with diode laser for the same period revealed very rapid development of the erythroblasts , reticulocytes , few newly formed red corpuscles seen. while the basophilic, neutrophilic and eosinophilic myelocytes developed to form band cells , few basophils, neutrophils and eosinophils seen in the smear. Monocytes seen and the megakaryocytes tend to develop in to platelets, Figure 2.

After three weeks of irradiation with He – Ne laser in the animals of the first group the marrow smears obtained from the animals revealed a development in the maturation of the hemopoietic cells , there were a reticular cells and newly formed blood corpuscles , the basophilic, neutrophilic and eosinophilic myelocytes developed in to

band cells and some basophils, eosinophils and neutrophils, lymphocytes and monocytes seen in the smear, the number of the adipose cells decreased.

At the animals of the group which were irradiated with diode laser for the same time the examination of the marrow smears showed large number of well-developed red cells, basophils, eosinophils , neutrophils , monocytes and lymphocytes , there were a large number of platelets , the steps of the maturation of the marrow components significantly invade the smear indicated the change of the marrow from yellow to red , the fibroblasts and remaining stromal cells became very scant, Figure 3.

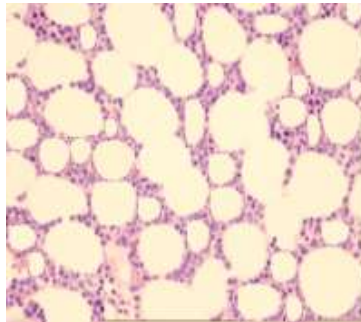


Figure 1: the first day of irradiation in both groups ; the fatty marrow is dominant, large number of adipose cells, little white blood cells and erythrocytes ,(Wright Stain X 100).

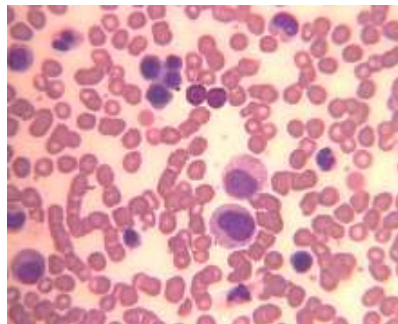


Figure 2: after two weeks of irradiation with diode laser : large number of erythroid cells , myelocytes and metamyelocyte , (Wright Stain X 100) .

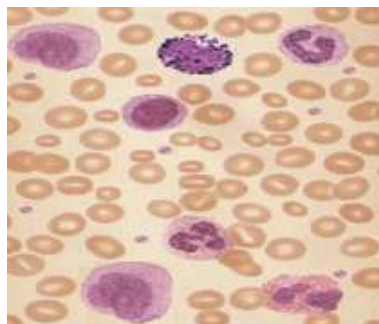


Figure 3: three weeks after the irradiation with diode laser : the red marrow was the dominant, large number of erythrocytes , white blood cells and lymphocytes , (Wright Stain X 100) .

4 Discussion

In the last few years the world gave a great attention for the marrow mesenchymal stem cells as a new method introduced strongly in the fields of tissue engineering and reparative medicine, that for they have a potential ability to proliferate and differentiate any where in the body when there is a need for that, at the same time the scientists and research centers found that irradiation of these cells with low level lasers potentiate them to a great degree.

Mesenchymal stem cells found any where in the body but it can be easily got from the bone marrow and then transmitted and implanted in any injured organ in the body, where they provide their functional roles[13] .

These cells have the ability to differentiate to any mesenchymal derived tissue in vitro, their functional roles in a damaged tissues do not depend on their ability to differentiate, but on their ability to secrete growth factors and cytokines, that stimulate the tissue cells to build new microcirculation, extracellular matrix and promote the endogenous regenerative response [14, 15]. They also possess immunosuppressive properties that make them easily used in both autologous and allogenic contexts [16].

Low level lasers stimulates the differentiation of mesenchymal stem cells, enhances osteogenesis and inhibits adipocytes formation and decrease the osteoclast's capability of bone resorption [17], that contributes the decrease in the adipose cells, osteoblasts, osteocytes and osteoclasts in the smears obtained from the animals of both laser treated groups after 7 days of irradiation and also the early appearance of the hemopoietic cells.

Irradiation of mesenchymal stem cells with a diode laser promote their proliferative capability, this process is dependent on activating some physiological aspects like the membrane ion channel and Notch-1 upregulation [16].

Results shown that after 7 days post exposure to low power laser radiation indicate that the irradiation caused releasing of prostaglandin which cause an inflammatory reaction in the area which in turn initiate a release of histamine, however the mechanism underlying the bio-stimulating effects on the molecular aspect focused on the changing of the laser photons into metabolic energy in the form of ATP, which in turn stimulates a variety of biochemical pathways leading to accelerating of cell proliferation [18].

Regarding the variance in development and regeneration in response to He-Ne and diode laser despite that they are both with 5 mW is contributed that He-Ne laser has a limited penetration capability with a focused beam while the diode laser has a more penetrating capability rather than it was of window type and the radiation distributed on a wider area making it found more pronounced effects, so animals treated with He-Ne Laser showed 14 days later development of the erythroblasts, basophilic, neutrophilic and eosinophilic myocytes, some lymphocytes and megakaryocytes while those treated with diode Laser showed rapid development of the erythroblasts, reticulocytes, few newly formed red corpuscles seen. while the basophilic, neutrophilic and eosinophilic myocytes developed to form band cells, few basophils, neutrophils and eosinophils, referring to a large gap in the effect and the effect of the laser and results seen in the smears between the two groups. Animals treated with He-Ne laser showed 21 days later showed reticular cells, newly formed blood corpuscles, some basophils, eosinophils and neutrophils, lymphocytes and monocytes, while those of the diode laser group showed maturation of the marrow components invading the field indicated the change of the marrow from yellow to red which is contributed to synchronization of formation and much more releasing of prostaglandins. Increased vascularization at the sites irradiated with LLLT is a laser-specific reaction, the laser radiation stimulates Growth hormone G-protein, which in turn facilitate the cyclic adenosine monophosphate cAMP, the latter stimulates cyclic deoxyribonucleic acid cDNA, this product will stimulate the messenger ribonucleic acid mRNA which enhances and increases protein synthesis. Prostaglandins exaggerate the stimulatory effect of GH, cAMP, and protein kinase.5, ATP, ATPase. Adenosine, GH, FGE, and VEGF are angiogenic factors, [19].

5 Conclusions

Irradiation of the marrow with low level lasers regardless the kind is very efficient to make the bone marrow to restore its efficacy even if tend to be yellow in nature, the marrow motivated and restore its capability of producing of the hemopoietic stem cells and mature blood cells

References

1. Aaron C.-H. Chen, Ying-Ying Huang, Sulbha K Sharma and Michael R Hamblin, 2011, Photomed Laser Surg. Jun; 29(6): 383–389.
2. Moriyama Y. Nguyen J. Akens M. Moriyama E.H. Lilge L. 2009. Lasers Surg Med. 41:227–231.
3. Omi T. Kawana S. Sato S., et al. 2005. Br. J. Dermatol. 153(Suppl 2):57–62.
4. Boschi E.S. Leite C.E. Saciura V.C., et al. 2008. Lasers Surg. Med. 40:500–508.
5. Silva, I. Branco, J.C., 2012, Acta. Reumatol Port. 37: 302 – 13.
6. Al- Ghamidi, K.M., Kumar, A. and Moussa, N.A., 2012; LLLT, Lasers Med. Sci. 27 : 237 – 49.
7. Somaye Fallahnezhad, Abbas Piryaei, Hasan Darbandi, Abdollah Amini, Seyed Kamran Ghoreishi and Reza Jalalifirouzkouhi, 2018, Journal of Cellular Biochemistry, Volume 119, Issue 1, Pp: 983-997.
8. Cavalcanti, Marcos, Maria, Durvanei, de Isla, Natalia, Cesar Pinto Leal-Junior, Ernesto, Joensen, Jon, Bjordal, Jan, Lopes-Martins, Rodrigo Alvaro, Diomedea, Francesca, Trubiani, Oriana & Frigo, Lucio, 2015; Photomedicine and laser surgery. 33. 10.1089/pho.

9. Thrall MA, Weiser G, Jain N., 2004; Laboratory evaluation of bone marrow. In: Thrall MA, ed. *vet. hematology and clinical chemistry*. Baltimore, Md: Lippincott Williams & Wilkins,;149-178.
10. Weiss DJ, Smith SA., 2002. *Compend Cont. Educ. Pract. Vet.* ;24:670-678.
11. Raphael Rubin & David S. Strayer , 2007; . Pp: 90. ISBN 0-7817-9516-8.
12. <https://www.sigmaldrich.com/catalog/product/SIGMA/WS16?lang=en®ion=IQ>
13. Doorn J, Moll G, Le Blanc K, van Blitterswijk C, de Boer J., 2012, Paracrine Effects and Potential Improvements. *Tissue Eng Part B Rev* 18:101-115.
14. Caplan AI., 2007. *J Cell Physiol* 213:341-347.
15. Sassoli C, Pini A, Chellini F, Mazzanti B, Nistri S, Nosi D, Saccardi R, Quercioli F, Zecchi-Orlandini S, Formigli L., 2012. *PLos One*, in press.
16. Bernardo ME, Pagliara D, Locatelli F., 2012, *Bone Marrow Transplant* 47:164-171.
17. R.-F. Zhang, Q. Wang, A.-A. Zhang, J.-G. Xu, L.-D. Zhai, X.-M. Yang and X.-T. Liu , 2018, *Eur Rev Med Pharmacol. Sci.* ,Vol. 22 - N. 9 , Pp; 2860-2868 , DOI: 10.26355/eurrev-201805-14988.
18. Chen BY, Wang X, Chen LW, Luo ZJ., 2012. *Curr Drug Targets* 13:561-571.
19. F.R. Mohammed, Ihsan, 2005, *Photomedicine and Laser Surgery* , Vol. 23, Number 3, © Mary Ann Liebert, Inc.Pp. 289–294.