

# Laser Diode Enhances Autologous Cartilage Graft's Expansibility

Ihsan, F.R.Mohammed\*, Nuha S. Al-Mustawfi \*\* & Mohammed S. Al- Iedani F.I.C.M.S.\*\*\*

## ABSTRACT

**Background:** Cartilage forms most of the temporary skeleton of the embryo and provides a model in which most bones develop

**Objective:** Using laser therapy to enhance autologous cartilage grafts expansibility and to analyze whether this "enhancement" results in reduced rates of cartilage resorption and greater preservation of normal architectural features compared with "unenhanced" grafts.

**Type of the study:** Cross sectional study.

**Methods:** 24 New Zealand rabbits were divided into two groups (control and treated with 904nm, 10mW diode laser). Auricular cartilage segments measuring 1 cm<sup>2</sup> were harvested from both ears of each rabbit, and were implanted in to the subcutaneous region of the left flank. 3 rabbits from each group were anaesthetized at 3, 6, 9 and 12 weeks post operation, implanted cartilages were then peeled. Gross and microscopic examinations were performed to assess size, structural integrity, and architectural features, with comparisons performed between each of the conditions. The results were assessed using T - test.

**Results:** Grafts of control group were softer, more pliable when compared with grafts treated with laser irradiation. The rate of healing, and the quality of the cartilage is more enhanced in the treated group. The

mean areas of the harvested cartilage grafts treated with laser therapy were 1.17 cm<sup>2</sup>, 1.34 cm<sup>2</sup>, 1.64 cm<sup>2</sup> and 1.76 cm<sup>2</sup> respectively, while the corresponding value for the untreated specimens was 0.95 cm<sup>2</sup>, 0.99 cm<sup>2</sup>, 1.05 cm<sup>2</sup> and 1.08 cm<sup>2</sup>. The percentage of decrease in size was 14% for the untreated specimens and 0% for the specimens treated with laser therapy for all cases.

**Conclusions:** Our findings demonstrated significant improvements in graft quality using laser therapy. These findings may justify changes in how cartilage grafts are prepared and delivered for facial augmentation procedures to reduce graft resorption and maintain the structural integrity of the cartilage.

**Keywords:** Laser Diode, Autologous Cartilage Grafts & Expansibility

*Al-Kindy College Medical Journal Vol.12 No.1. Page: 118-121.*

\* Received at 7<sup>th</sup> Jan 2015, accepted in final 28<sup>th</sup> Oct 2015.

\*College of Medicine - Al- Muthan`na University.

\*\* Ministry of health

\*\*\*Al- Kindy College of Medicine - University of Baghdad.

Corresponding author to: Dr. Ihsan, F.R.Mohammed  
College of Medicine - Al- Muthan`na University.

Cartilage forms most of the temporary skeleton of the embryo and provides a model in which most bones develop. Adult cartilage is nourished by diffusion through its matrix from capillaries in the perichondrium. Due to this, it is a subject to necrosis and poor healing in the case of ulceration of the overlying perichondrium, (1).

Soft-tissue augmentation used for nasal reconstructions while ideal nasal implants for bridge construction attempted such as paraffin, polyethylene and silicone, (2).

In the 19<sup>th</sup>. century, various alloplastic materials were used for nasal reconstruction, the autologous bone was the most common one. In 1941, Peer; described the resistance to resorption of autologous septal and auricular cartilages, (3).

Fibroblast growth factor and fibrin sealant are used to enhance the autologous cartilage grafts and analyze whether this "enhancement" results in reduced rates of cartilage resorption and greater preservation of normal architectural features compared with "unenhanced" cartilage grafts,(4).

Autologous cartilage grafts can be used to provide a structural framework for tissue that has been modified by trauma, or congenital malformation. One method to reshape cartilage for use in reconstructive procedures involves laser irradiation, (5).

The objective of the current study was to assess autologous cartilage grafts irradiated with diode laser to determine whether there is an increase in expansibility and a greater preservation of architectural features compared with non- irradiated cartilage grafts.

**Methods & Surgical Techniques:** 24 New Zealand white rabbits were divided in to two equal groups (control and treated with 904nm, 10mW diode laser).<sup>(1)</sup> The animals were anesthetized by using intramuscular ketamine hydrochloride (35 mg/kg),<sup>(2)</sup> and xylazine hydrochloride (5 mg/kg).<sup>(3)</sup> Sites chosen for the operation were the medial aspect of both auricles and the subcutaneous region of the left flank.

The medial aspect of the right auricle was prepared surgically and a three sided square skin flap was done down to the level of the perichondrium avoiding the central artery of the ear. Skin flaps were elevated with sharp dissection to expose an area of one and half centimeters each side, to expose the yellow cartilage beneath it. Then a square incision made in the cartilage with one centimeter each side, peeled out and transmitted to a Petri dish filled with normal saline, the same thing done on the other side, the area of the operation washed with normal saline and resutured with simple interrupted stitches using 4-0 silk.<sup>(4)</sup>

Careful dissection of the cartilage with the attached perichondrium was performed to completely isolate and transect the exposed segment of the auricular cartilage. The donor site was closed with interrupted 4-0 chromic sutures. The harvested cartilage 1cm<sup>2</sup> segments, transmitted under sterile conditions into 12 individual pockets, each measuring 1.5 x 1.5 cm, these pockets were dissected in the subcutaneous region of the upper side of the flank of each animal to serve as recipient sites for each of the explanted specimens, the same procedure was carried out in the left auricle.

The left flank was prepared surgically and a three sided skin flap was done, the skin raised and the two pieces of the cartilage placed in contact with the subcutaneous tissue without any fixation, the skin flap was closed and sutured with interrupted stitches using 3-0 silk.

The site of the operation in the treated group was irradiated with a diode laser with wave length of 904nm, and output of 10mW, window type, for 10 minutes/session and total of 10 sessions starting immediately after the operation. Laser light was applied by direct contact of the laser window to the flank.

1-Russian- Palisb, Joint venture << Moskovesky Polisib>> Gblid .3 , Noroslobodskay , Moscow ,Russia .  
2-Ketallar , 50 mg/ ml , park dauis 8 Co. Gwent , U.K.  
3-Rompon , 20 mg/ml, Dehoeve 28 , Pantex ,Holland .  
4-Eth, Ltd ., PO .Box 408 , Bankhead Auenue , Edinburgh, and Scotland.

**Harvesting & Analysis:** Three rabbits of each group were anaesthetized and the implanted cartilages were dissected and removed for study. Gross analysis included a measurement of the area (area [cm<sup>2</sup>] = length [cm] x width [cm]) of each harvested cartilage graft using ocular stage. Results were analyzed using paired samples *t* test to determine the variations in mean area and resorption rates. Subjective assessments on the gross specimens included a determination of the pliability of each segment of cartilage and an inspection for the presence of inflammatory exudates surrounding the cartilage graft or within the recipient bed .Sections prepared from the specimens at each time stained with hematoxylin - eosin for histopathological examination.

**Results:** Palpation of the skin overlying the implanted cartilage revealed a subjective difference in the ability for manual displacement of grafts within the subcutaneous pocket from the first postoperative day till the third week postoperative, when all the grafts were subjectively immobile. On harvesting the cartilage grafts, there was no gross, subjective evidence of inflammatory exudates, either within the recipient bed or area surrounding the cartilage grafts. All grafts were noted to have a thin, fibrous capsule surrounding them. Palpation of the grafts revealed a subjective difference in the structural integrity between those treated with laser irradiation comparing with the control group grafts. Grafts of control group were softer, more pliable, when compared with grafts treated with laser radiation.

Samples collected from the animals of control group 3 weeks post operation showed bleeding with chronic inflammatory cells infiltration. Samples collected from the treated group for the same period showed mild hemorrhage in the area of the operation with inflammatory cell infiltration especially macrophages and neutrophils seen in the area. The cartilage appeared to be surrounded with perichondrium, chondroblasts while the chondrocytes appeared clearly and the matrix seemed to contain collagen and elastic fibers.

Samples collected from the animals of control group 6 weeks post operation showed continuing inflammatory reaction, while the samples collected for the same period from the irradiated group showed formation of connective tissue and newly blood vessels in the area of the operation.

Samples collected from the control group 9 weeks post operation showed some damaged blood vessels in the area with inflammatory reaction, the connective tissue consists mainly collagen fibers and lesser amount of elastic fibers, while samples collected from the treated group for the same period showed large number of

chondrocytes and chondroblasts. The perichondrium showed a thick layer of connective tissue consisting of dense collagen and elastic fibers, Fig1.

Samples collected 12 weeks post operation showed increase in number of chondroblasts and chondrocytes. The matrix appeared thick layer of connective tissue surrounding the cartilaginous cells, while samples collected from the treated group for the same period revealed high

developing in the cartilage proliferation including high increase in the number of the chondrocytes and chondroblasts and connective tissue (dense collagen and elastic fibers) in the area of operation, Fig 2.

Thick connective tissue matrix with high increase in numbers of chondroblasts and chondrocytes that make cartilage grow in size and show penetration into the surrounding tissue.

Fig 1: Sample collected from the treated group (9 weeks post operative showed large number of chondrocytes and chondroblasts (H&E X 400).

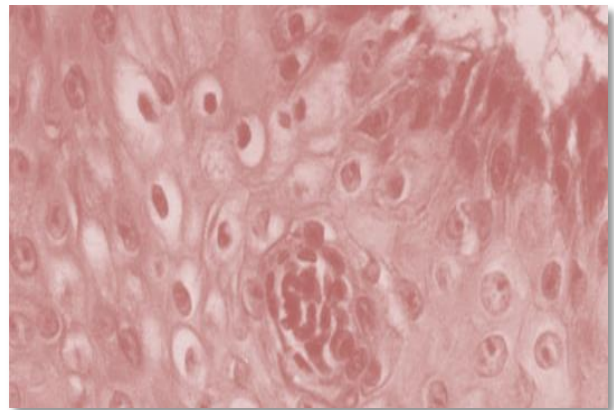


Fig 2 : Sample collected from the treated group ( 12 weeks post operative showed proliferation of well developed cartilage , thick matrix and high increase in the number of the chondrocytes and chondroblasts , ( H & E X 100 ) .

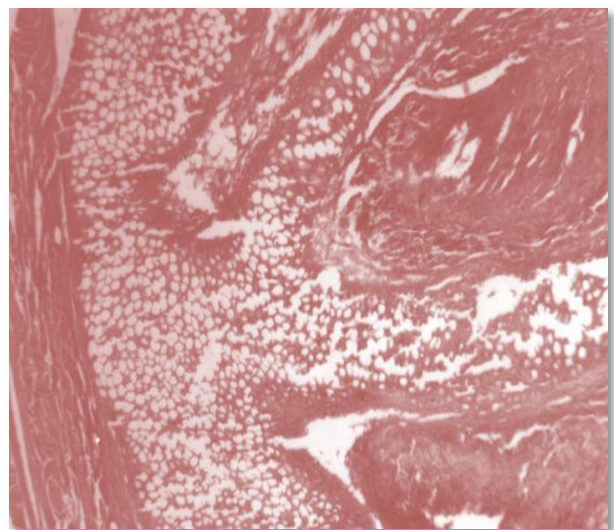


Table 2: Mean, Standard Deviation SD, Standard Error SE, Value of Probability and Degree of Significance of both groups.

| Readings               | Groups |       |       |      |       |      |       |      |
|------------------------|--------|-------|-------|------|-------|------|-------|------|
|                        | C3     | L3    | C6    | L6   | C9    | L9   | C12   | L12  |
| Mean                   | 0.95   | 1.17  | 0.993 | 1.34 | 1.05  | 1.64 | 1.08  | 1.76 |
| SD                     | 0.12   | 0.01  | 0.092 | 0.04 | 0.01  | 0.05 | 0.03  | 0.04 |
| SE                     | 0.049  | 0.005 | 0.038 | 0.01 | 0.004 | 0.02 | 0.01  | 0.02 |
| P- Value               | 0.001  |       | 0.000 |      | 0.000 |      | 0.000 |      |
| Degree of Significance | *      |       | *     |      | *     |      | *     |      |

\*Very Highly Significant

**Comments:** Investigations determined that perichondrium possesses chondrogenic properties, which promote the survival of cartilage grafts, and has even yielded whole cartilage when implanted alone. The mitogenic properties of the perichondrium support the use of auricular cartilage autografts,(6).

The outcomes of the current study agreed with studies which reconstructed the internal septum of the nose using graft expansibility, in which they had subjective improvement in function in 95% of patients. Many patients also report high satisfaction rates in both the function and aesthetics, nasal symmetry and appearance post the operation, (7).

The results obtained from the current study revealed that the irradiation of the autograft cartilages with diode laser increases the rate of healing, and the quality of the cartilage is more enhanced. Laser irradiation appeared to also decrease the rate of resorption. These results correlate with those obtained by Ozcan et. al., to assess the clinical outcome of crushed cartilage grafts used to conceal contour irregularities in rhinoplasty. They determined that the degree of crushing applied is important for long-term clinical outcome of autogenous crushed cartilage grafts. Slight or moderate crushing of cartilage creates an outstanding graft material for concealing irregularities and provides both excellent long-term clinical outcome and predictable esthetic results,(8).

It is known for the last few decades that low level lasers accelerate some phases of wound healing; they can stimulate fibroblast and keratinocyte proliferation and migration. It is thought to work via light absorption by mitochondrial chromophores leading to an increase in ATP, reactive oxygen species and consequent gene transcription, (9).

Fibroblast growth factor FGF-2 has been applied in vitro to chondrocyte cells both in monolayer culture and in three dimensional environments. It has been established that FGF-2 (also called basic fibroblast growth factor) is a potent mitogen for chondrocytes in monolayer culture and in vivo. However, reports about the use of FGF-2 to culture cartilage tissue in vitro in a three dimensional environment have been contradictory. For example, FGF-2 has been reported both to cause a waning of the mature phenotypic characteristics typical of cartilage explants and increase the rate of proliferation without affecting the mature phenotypic characteristics of chondrocytes - seeded implants in the presence of FGF-2, (10).

Prostaglandins enhance the stimulatory effect of Fibroblast Growth Factor, FGF, (11).

In general, fluencies of red or near infrared NIR as low as 3 or 5 J/cm<sup>2</sup>. The molecular and cellular mechanisms LLLT suggest that photons are absorbed by the mitochondria; they stimulate more ATP production and low levels of reactive oxygen species ROS, which then activates transcription factors, such as the transcription

factor NF- $\kappa$ B, to induce many gene transcript products responsible for the beneficial effects of LLLT. ROS are well known to stimulate cellular proliferation of low levels, but inhibit proliferation and kill cells at high levels. Nitric oxide is also involved in LLLT, and may be photo-released from its binding sites in the respiratory chain and elsewhere. It is possible that NO release in low amounts by low dose light may be beneficial, while high levels released by high dose LLLT may be damaging. The third possibility is that LLLT may activate transcription factors, upregulating protective proteins which are anti-apoptotic, and generally promote cell survival.

In contrast, it is entirely possible that different transcription factors and cell-signaling pathways, that promote apoptosis, could be activated after higher light exposure, (12).

The results of this study agreed with those obtained by Wright et al. (2004) who found that cartilage specimens irradiated at higher power show a greater degree of shape change while those which were irradiated at lower power may have reverted to their native shape, (13). The results of this study also agreed with those which demonstrated the benefits of enhancing cartilage autografts with either fibrin sealant and  $\alpha$ FGF or  $\beta$ FGF or simply fibrin sealant alone, (4).

**Conclusions** : Enhancing of cartilage grafts expansibility using diode laser irradiation to improve the spreading, increasing the space or the dimensions not the size or the volume, or producing a mass of cartilage and graft quality has not been studied. The current study revealed significant improvements in both the gross and histological features of implanted cartilage using laser irradiation. These results may improve the method of how cartilage grafts are prepared, expanded and delivered for nasal and auricular augmentation to reduce the resorption rate while preserving the structural integrity of the cartilage.

#### References

1. Richard, S. Snell; Clinical Anatomy by Regions. Introduction: Cartilage, 8t. Edition, Lippincott Williams & Wilkins, 2008.
2. Burt Brent; History of Auricular Reconstruction. <http://www.microtia.us.com/microtia-atresia-auricular-reconstruction-history.html>, 1998-2007.
3. Patrick Byrne&Peter Hilger: Rhinoplasty, Augmentation, <http://www.emedicine.com>, Oct 3, 2006.
4. Matthew R. Kaufman, Richard Westreich, Sherif M. Ammar, Asif Amirali, Andrew Iskander& William Lawson. Autologous Cartilage Grafts Enhanced by a Novel Transplant Medium Using Fibrin Sealant and Fibroblast Growth Factor , Arch Facial Plast Surg. Vol. ;6, No. 2, 6:94-100 , March - April 2004;.
5. Ryan Wright & Mentor: Brian Wong; Determination of Chondrocytes Viability Following Nd: YAG (l = 1.32 mm) Laser Irradiation, UCI Undergraduate Research Symposium,2004,[www.urop.uci.edu/symposium/past\\_symposia/04/abstracts3.html](http://www.urop.uci.edu/symposium/past_symposia/04/abstracts3.html).
6. Alan J. C. Burke, Tom D. Wang & Ted A. Cook , Irradiated Homograft Rib Cartilage in Facial Reconstruction , Arch Facial Plast Surg. ; 6:334-341. Vol. 6 No. 5, Sep-Oct 2004 ,
7. John M Hilinski & Patrick Byrne; Rhinoplasty, Spreader Grafts. [http](http://www.archfacialplasticsurgery.com), Jun 30, 2006.
8. Ozcan Cakmak& Fuat Buyuklu; Crushed Cartilage Grafts for Concealing Irregularities in Rhinoplasty ,Arch Facial Plast Surg. ;352-357 Vol. 9 No. 5, Sep-Oct 2007 ;
9. Tatiana N Demidova , Ira M Herman , Elena V Salomatina , Anna N Yaroslavsky & Michael R Hamblin ; Wound healing stimulation in mice by low-level light: Proc. of SPIE Vol. 6140 61400C-1, (2006) .
10. Hawkinse, D. & Ibrahams, H.; Laboratory Methods for Evaluating the Effect of Low Level Laser Therapy (LLL) In Wound Healing , African Journal of Biomedical Research,Vol.81 - 14,(2005); <http://www.bioline.org.br/md> , ISSN 1119 - 5096 © Ibadan Biomedical Communications Group .
11. Ganong, W.F.: Synaptic and Junctional transmission. In; Review of Medical Physiology. 21<sup>st</sup>. edition. Chapter (4), pp: 85-120, Lange medical book, 2005.
12. Ying Huang, Boston, MA. , Aaron C. H. Chen, James D. Carroll & Michael R. Hamblin; Biphasic Dose Response in Low Level Light Therapy, dose-response. 10.2203, 09-027.Hamblin. Copyright © 2009 University of Massachusetts .ISSN: 1559-3258.
13. Ryan Wright & Mentor: Brian Wong; In vivo Response of Cartilage to Laser Reshaping in the New Zealand White Rabbit, UCI Undergraduate Research Symposium,2004,[www.urop.uci.edu/symposium/past\\_symposia/04/abstracts3.html](http://www.urop.uci.edu/symposium/past_symposia/04/abstracts3.html).