

See discussions, stats, and author profiles for this publication at: <https://www.researchgate.net/publication/349481771>

Study of Histological Structure of Kidney in Snake *Eryx gaculus gaculus*

Article in *International Journal of Science and Research (IJSR)* · January 2015

DOI: 10.21275/ART20172468

CITATIONS

0

READS

382

4 authors:



Entekhab Hameed Abed
University of Baghdad

5 PUBLICATIONS 1 CITATION

[SEE PROFILE](#)



Wijdan B. Abid
University of Baghdad

26 PUBLICATIONS 5 CITATIONS

[SEE PROFILE](#)



Azhaar Raheem Hussein Al-Fartwsi
University of Baghdad

5 PUBLICATIONS 1 CITATION

[SEE PROFILE](#)



Asmaa Basheer Abed
University of Baghdad

16 PUBLICATIONS 11 CITATIONS

[SEE PROFILE](#)

Study of Histological Structure of Kidney in Snake *Eryx gaculus gaculus*

Entekhab Hameed Al-Shuwaili^{*1}, Wijdan Basheer Abed², Azhaar R. Al-Fartwisy³, Asmaa Basheer Abid⁴

Department of Biology, College of Education for Pure Sciences (Ibn Al-Haitham), University of Baghdad, Baghdad, Iraq

*E-mail: intikhab.hameed[at]yahoo.com

Abstract: The purpose of this study was to examine the histological structure of the kidney in snake *Eryx gaculus gaculus*. In present study, the snakes were collected from the city of Baghdad and transferred to the laboratory where their kidneys were dissected out. The samples were then processed to be prepared for histological examination microscopic observations showed that there is no border between the cortex and medulla regions of kidney. The kidney consists of nephrons which are composed of glomerulus surrounded by Bowman's capsule; the other segments are proximal tubule, distal tubule and connecting tubule. The epithelial tissue lining of these segments simple cuboidal tissue.

Keywords: Snake, kidney, nephron.

1. Introduction

The kidney are located in abdominal cavity and receive blood from the paired renal arteries and drain into the paired renal veins [1; 2]. The kidney plays an important role as one of the necessary organs of the body of animals where the infiltration of blood and secretion of waste object, as well as urine excretion through the ureter to the Urinary Bladder, Where the water leak a Urine in mammals and as auric acid in reptiles. The kidney is also has the function of endocrine secretion, where secrete Erythropoietin which stimulates the production of red blood cells (Erythrocytes) in the bone marrow, as well as the production of reninenzyme which helps regulate blood pressure [3; 4].

Many researchers studying the histological structure of the kidney in reptiles Anderson [3]; Robert and Schmith-Nielsen [5], the studies showed that the kidney in reptiles is similarity in to the kidney in birds but they differ from the kidney of mammals and amphibians Jacobson [6]. Renal Corpuscles was studied in Chelonia by Jacobson [7] and in lizards by Zuasti *et al.* [8].

Many studies focus on part of kidney which is found in males only and is called a Sexual Segment which is modify in renal channels in lizards and snakes [9; 10]. Interest in studying the kidney in reptiles increased because of their vital role for these animals [11; 12; 13; 14]. Renal units or nephrons of kidney reptiles consist of renal corpuscles, glomeruli, distal convoluted tubules, proximal convoluted tubules and the collecting tubules [5; 8; 15; 16]. Human kidney contains about two million functional unit nephrons, while the kidney of reptiles contains a few number of nephrons ranging from (1500-6000) functional unit [7; 17].

Many studies described the histological structure of kidney in the different species of vertebrates. The study of Al-Jubory [18] shows the embryonic development of pronephros in the carp fish and study of Hamdey [19] shows the embryonic development and histological structure of the pronephros and opisthonephros in the

gambezi fish. The study of Daoud *et al.* [20] shows the histological structure of kidney in *Columba livia gaddi* and the study of Al-Ambeky [21] shows the morphological structure of kidney in the *Hyla arborea* and *Passer domesticus* and the study Khadhim and Daoud [22] shows the morphological describe and histological structure of the kidney *Tyo alba* (Brain owt).

The current study has been conducted to determine the histological structure of kidney as an expansion and extension of previous studies and to add information that may be essential in this type of field studies in reptiles.

2. Materials and Methods

The histological study of the kidney in snake *Eryx gaculus* is required following steps:

The snakes were obtained from the city of Baghdad and the study was conducted on five animals and in order to study the following steps:

The kidney on dissecting plate (cork bored) the animals were placed on its back toward the surface of the plate. Incision was made in the along the middle line of the abdominal wall from the cloaca to the thoracic girdle then a transverse incision in the abdominal muscles was made to open the abdominal cavity and expose the kidneys and washed with distilled water and then placed in the fixed solution (formalin) [23]. The samples were fixed in formalin solution concentration of 10% [16] then carried out the washing process by tap water and then drying (dehydrated) by alcohol ethyl, then clarification (cleared) by xylene then infiltrated and embedded in wax paraffin melting temperature (56-58)° C and then casting in special molds, then clips cut a thickness of 7 micrometer by rotary microtome (Milano - Italy), then sections stained with hematoxylin and eosin to clarify the cellular composition of the kidney and mounting by Canada balsam [24]. The sections were filming to clarify the histological structure using the light microscope supply by a camera.

3. Results

Histological Structure of Kidney in Snake *Eryx gaculusgaculus*

Results showed that the kidney is surrounded by a thin capsule of fibrous connective tissue (Figure 1).

The kidney consists of the two regions the peripheral region called the cortex and contains a small number of renal units (nephrons) which is represented by proximal convoluted tubules, distal convoluted tubules in addition to glomeruli with a bowman's capsule, and the other region is medulla. The cortex and medulla regions are not separated by distinct border (Figure 1-6).

Renal corpuscle

The results of the current study showed that the renal corpuscles in the kidney of snake was deployed within the cortex and are small spherical structures consists of glomerulus and Bowman's capsule the glomeruli were various sizes and are surrounded by the Bowman's capsule which composed of two layers, the parietal layer is (capsular epithelium) composed of simple squamous epithelial tissue and visceral layer (glomerular epithelium) and the space shows between visceral layer and parietal layer is called capsular space (Bowman's capsule) and glomerulus (Fig 3).

Proximal convoluted tubule

The epithelial tissue of this tubule is composed of simple cuboidal epithelial tissue and has a small cavity, and its cells containing a brush border in the free surface of the cells. The cytoplasm of the cells is Light-colored the nucleus of the cells are dark-colored and a central location. The lumen of the proximal tubule is often occluded by apposition of the brush borders of the surrounding cells. (Figure 4).

Distal convoluted tubule

The results of the current study showed that the lining of the distal convoluted tubule be composed simple cuboidal epithelial tissue where cells contain nuclei of a central location, a dark character, and the apical surface of the cells was not covered by brush border and of microvilli the lumen of the distal convoluted tubule was larger than the lumen proximal convoluted tubule (Figure 4).

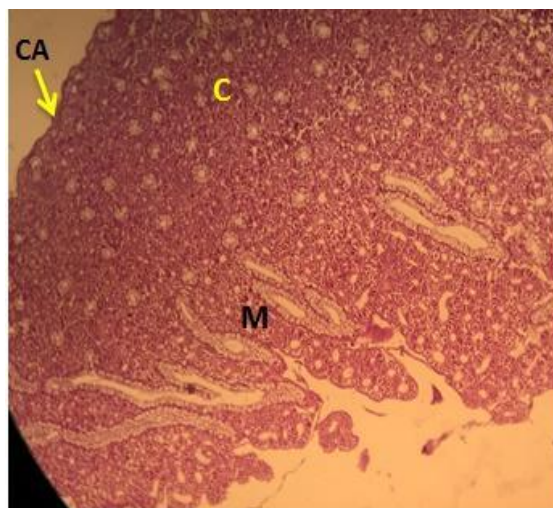


Figure 1: T.S. of kidney in snake *Eryxgaculusgaculus*. Notice: Cortex (C), Medulla (M), Capsule (CA), (H & E). 10x.

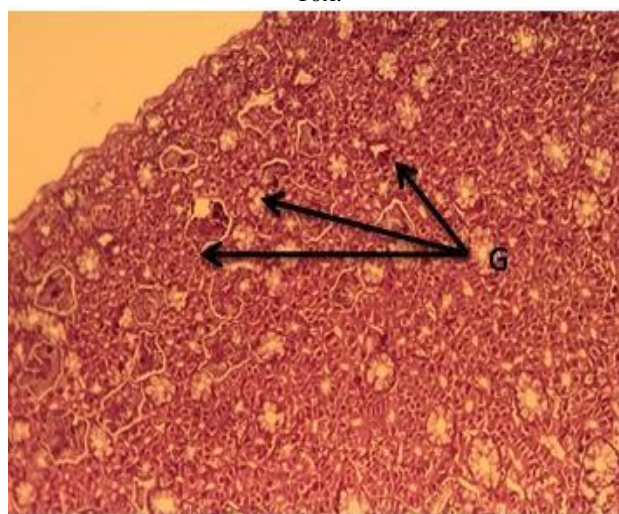


Figure 2: T.S. through of kidney in snake *Eryxgaculusgaculus*. Notice: Glomerulus (G), (H & E). 10x.

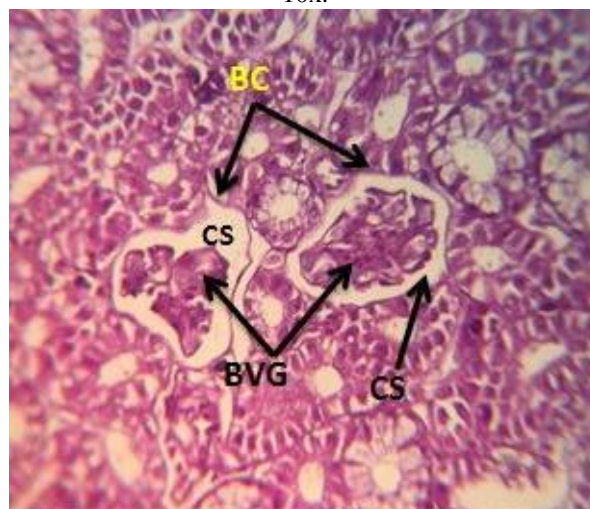


Figure 3: T.S. of kidney in snake *Eryxgaculusgaculus*. Notice: Bowman's capsule (BC), Capsule space (CS), Blood vessel glomeruli (BVG), (H & E). 40x

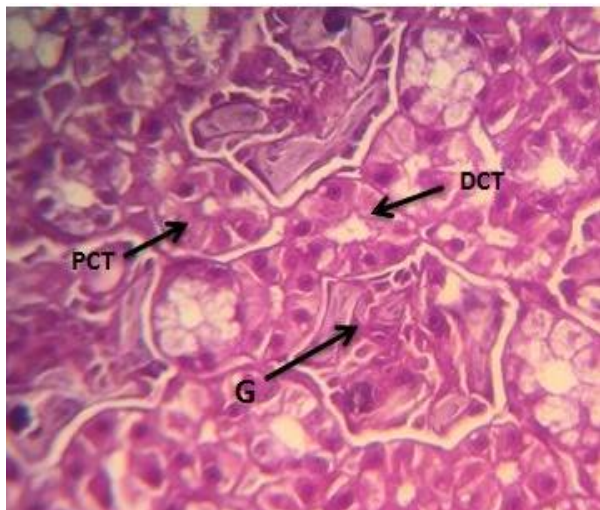


Figure 4: T.S. through of kidney in snake *Eryxgaculusgaculus*. Notice: Proximal convoluted tubule (PCT), Distal convoluted tubule (DCT), Glomerulus (G). (H & E), 40x.

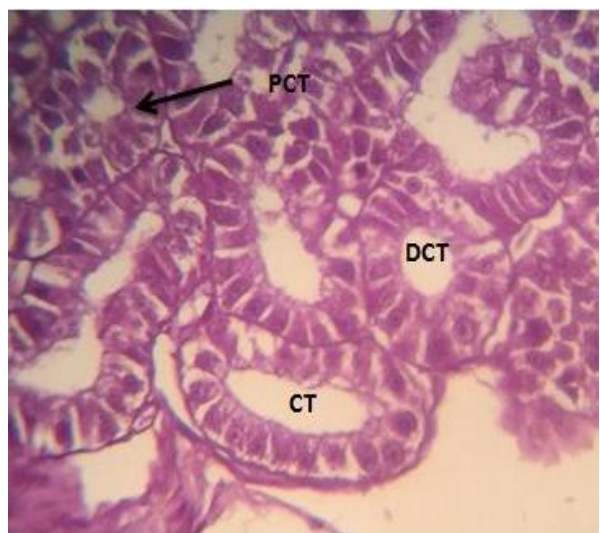


Figure 5: T.S. of kidney in snake *Eryxgaculusgaculus*. Notice: Proximal convoluted tubule (PCT), Distal convoluted tubule (DCT), Collecting tubule (CT). (H & E)

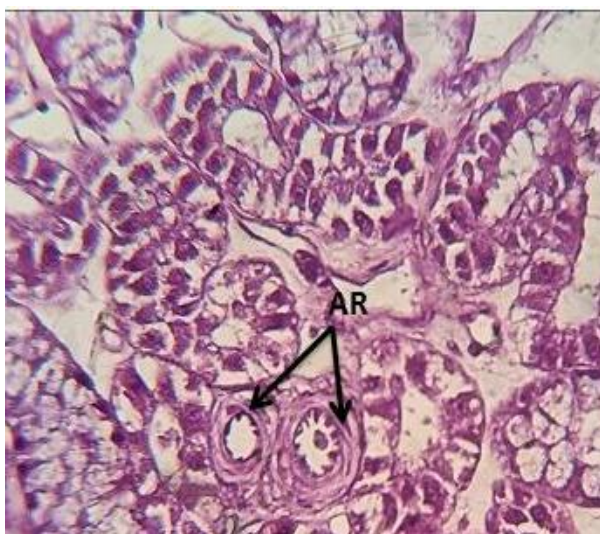

Figure 6: T.S. of kidney in snake *Eryxgaculusgaculus*. Notice: Arterioles (AR) in the cortex. (H & E), 100x

4. Discussion

The kidneys are important organs to the urinary system because the kidneys regulate the electrolytes including salts, acid-base balance, fluid balance and blood pressure and the kidneys excrete nitrogenous wastes such as urea and ammonium. The kidneys produce hormones, including calcitriol and erythropoietin and they produce renin enzyme. They are also responsible for the reabsorption of water, glucose and amino acids [1; 16].

The kidney develops from intermediate mesoderm and kidney developmental proceeds through a series of developmental phases: the pronephros, mesonephros and metanephros) [25].

The nephron of reptiles is comprised of several segments including renal corpuscle that consists of Bowman's capsule and glomerulus, proximal tubule, distal tubule and collecting tubule [7; 26]. That is agreement with the present study.

The snake *Eryx gaculusgaculus* has a few nephrons because of many reptiles live in dry environments and among the many adaptations to such environments is their ability to convert waste nitrogen compounds into uric acid and it is insoluble and so can excreted using a small amount of water [27] while the kidney of human and other mammals consist of two million nephrons [1].

The physiology of the kidney has adapted to specific conditions of life, including the type of food, environmental temperature and the availability of water [16]. The Bowman's capsule develops around globular mass of capillaries together comprise renal corpuscle similar results were observed in different species of reptiles. Some renal corpuscles have a wide Bowman's space because of the small glomerulus within the kidney [28]. The number of glomeruli in the kidney is related to the habitat of the animal and environment [7]. The number of the glomeruli is 400 to 6000 per kidney in the lizard, *Ctenophorus ornatus* [29].

The proximal tubules consisted of a simple cuboidal epithelial tissue and the surface of the cells contained a thick layer of microvilli forming a brush border. Same results reported by Yari and Gharzi [16] on lizard *Acanthodactylus boskianus*. The proximal tubules reabsorbed more than the other renal tubules at 60% of most filtered substances [1]. The proximal tubules in the avian absorb about 70% of the filtered volume of water, which depends on active reabsorption [30].

In the present study, the distal tubules consisted of a simple cuboidal epithelial tissue similar results were observed in *Tyto alba* and *Francolinus francolinus* [22]. The distal tubule showed few microvilli in snakes *Eryx jaculus*, *Psammophis sibilans*, *Naja haie* and *Echis pyramidum* from Egypt [14]. While in the present study, the microvilli was not located in the apical cells.

The distal tubules play a role in producing concentrated urine by reabsorbing water from the lumen of tubules [31];

32]. The distal tubules carried out selective absorption and active secretion of certain [1; 28].

The collecting tubules consisted of a simple cuboidal epithelial tissue and the cells contained a basal nuclei, the arrangement of the cells of the tissue are agreed with the findings obtained on the *Cyrtopodion scabrum* [33]. The collecting tubules are secrete mucin, which may aid in eliminating uric acid from kidney [32; 34]. The collecting tubules of snakes from the Egyptian area consist of mucous cells [14].

References

- [1] Kent, C. C. and carr, R. K. (2001). Comparative anatomy of the vertebrates, 9th ed., McGraw-Hill. Book Co. Inc., New York: 824 pp.
- [2] Nabipour, A.; Alishshi, E. and Asadian, M. (2009). Some histological and physiological features of avian kidney. J. Appl. Anim. Res., 36: 195-198.
- [3] Anderson, F. (1960). The ultramicroscopic structure of a reptilian kidney. J. Morph., 106: 205-240.
- [4] Aughey, E. and Frye, F. L. (2001). Comparative veterinary histology, with clinical correlates. Manson Publishing Ltd: 288 pp.
- [5] Robert, J. S. and Schmidt-Nielsen, B. (1966). Renal ultrastructure and excretion of salt and water by three terrestrial lizards. Am. J. Physiol., 211: 476-486.
- [6] Huber, C. G. (1906). The morphology of the uniferous tubule of the reptilian kidney. Br. Med. J., 201: 710-718.
- [7] Jacobson, E. R. (2007). Infection diseases and pathology of reptiles. Tylor and Franeicis. New York: 71 pp.
- [8] Zuasti, A.; Ferrev, C.; Ballesta, J. and Pastor, L. M. (1987). Ultrastructure of the tubules nephron of *Testudo aracea* (Chelonia). A comparison between hibernation and non hibernation animals. Histol. Histopath., 2: 391-400.
- [9] Peek, W. and McMillan, D. (1979). Ultrastructure of the renal corpuscle of the garter snake *Thamnophis sirtalis*. Am. J. Anat., 155: 83-101.
- [10] Sever, D. M.; Rheubert, J. L. and Gautreaux, J. (2012). Observation on the sexual segment of the kidney of snakes with emphasis on ultrastructure in the Yellow-Bellies sea snake, *Pelamis platurus*. The Anatomical Record, V(295), 5: 872-885.
- [11] Khalil, A.; Nasr, A. N. and Gabri, M. S. (1974). Studies on the histology and histochemistry of the sexual segment of *Mabuya quinquetaeniata* (Lacertilia), Scinidae. Bull. Fac. Sci. Assiutouniv., 3: 31-46.
- [12] Soares, A. M. V. and Fava de Moraes, F. (1983). Histochemistry of the tropical lizard *Tropidurus*. Gegebours morph. Jahrb., 129: 331-344.
- [13] Bradshaw, S. D. (2002). Arginine vasotocin site and mode of action in the reptilian kidney. Revue. J. Title., 126: 7-13.
- [14] Allam, A. A. and Abo-Eleneen, R. E. (2013). Comparative histological, histochemical and ultrastructural studied of the nephron of selected snakes from the Egyptian area. (68), 3: 546-558.
- [15] Edward, M. C. (1998). Evaluation kidney function in reptiles. The United State of America. Original edition. <http://www.angel.fire.com>.
- [16] Yari, A. and Gharzi, A. (2013). Anatomical and histological study of the excretory system in the Bosc's fringe toes lizard *Acanthodactylus boskianus*. Asian J. Anim. Sci., 7(1): 30-35.
- [17] Bishof, K. E. (1959). A histological and histochemical study of the kidney of the common garter snake *Thamnophis sirtalis* with special reference to the renal segment in the male. J. Morph., 104: 307-358.
- [18] Al-Jubory, A. H. A. (1987). Embryogenesis of pronephros in Carp fish. MSc. Thesis College of Science/ University of Baghdad.
- [19] Hamdey, B. A. (1988). Embryogenesis and Histological structure for pronephros and metanephros in mosquito fish. MSc. Thesis. College of Education for Pure Sciences/ Ibn Al-Haitham, University of Baghdad.
- [20] Daoud, H. A.; Mnati, E. M. and Balasem, A. N. (2002). The histological structure of kidney in rock pigeon, *Columba livia gaddi* (Gmelin, 1788). Tikreet J. Sci., 8(2): 18-26.
- [21] Al-Ambeky, D. A. Z. (2013). Morphological and Histological Description of the kidney in *Passerdomesticus* and *Hyla arborea*. MSc. Thesis, College of Education for Pure Sciences/ Diyala University: 109 pp.
- [22] Khadhim, I. A. A. and Daoud, H. A. (2014). Morphological Description and Histological Structure of Kidney in Barn Owl *Tyto alba*. Ibn Al-Haitham J. Pure And Appl. Sci., 27(3): 45-59.
- [23] Bancroft, T. D. and Stevens, A. (1982). Theory and practice of histology techniques, 2nd ed., Churchill Livingstone. London: 662 pp.
- [24] Luna, L. G. (1968). Manual of histological staining methods, 3rd ed. McGraw- Hill book. Co. Inc. New York: 258 pp.
- [25] Carlson B. m. (2004). Human Embryology and Developmental Biology (3rd ed.). Saint Louis: Mosby.
- [26] Davis, L. E.; Schmidt, N. B. and Stolle, H. (1976). Anatomy and ultrastructure of the excretory system of the lizard *Sceloporus cyanogenys*. J. Morphol. Jul., 149: 279-326 pp.
- [27] Nabipour, A. (2008). Histological strcture of kidney of insectivorous bats. World J. Zool., 3(2): 59-62.
- [28] Uchiyama, M.; NMurakami, T.; Yoshizawa, H. and Wakasugi, C. (1990). Strcture of the kidney in the crab-eating frog, *Rana cancrivora*. J. Morph., 204(2): 147-156.
- [29] O Shea, J. E. and Bradshaw, S. D. and Stewart, T. (1993). The renal vasculature and excretory system of the agamid lizard *Ctenophorus ornatus*. J. Morphol., 217: 287-299.
- [30] Reece, W. O. (2004). Dukes physiology of domestic animal. 12th ed., Cornell Univ. Press I theca, :107-113.
- [31] Bacha, W. L. and Bacha, L. M. (2000). Color atlas of veterinary histology. Lippincott Williams and Wilkins, 2nd ed., Philadelphia: 163-164.
- [32] Casotti, G. (2001). Effect of season on kidney morphology in house separrow. J. Exp. Biol., 204: 1201-1206.
- [33] Al-Shuwaili, E. H. (2015). Morphological and Histological Study of the Kidney in *Cyrtopodion scaberum*. J. Kerbala Univ., Second Conference of Science College.
- [34] Cummingham, J. C. and Klein, B. G. (2007). Text book of veterinary physiology. 4th ed., St. Luis, Saunders: 528-540