

Original Article

Prognostic Value of Intracellular Transcription of Factors HIF-1 α and p53 and Their Relation to Estradiol and TNM Parameters of Breast Cancer Tissues in Women with Invasive Ductal Carcinoma in Thi-Qar Province, Iraq

Ali Khadem, Z¹*, Abdul Wadood AL-Shammaree, S²

1. Department of Clinical Biochemistry, College of Medicine, University of Thi-Qar, Thi-Qar, Iraq
2. Department of Chemistry, College of Sciences, University of Baghdad, Baghdad, Iraq

Received 28 January 2022; Accepted 20 May 2022
Corresponding Author: rafahj.2t@gmail.com

Abstract

Breast cancer is the most common malignancy affecting women's health, with an increasing incidence worldwide. This study aimed to measure the intracellular concentration of the hypoxia-inducible factor 1 α (HIF-1 α), tumor suppression protein p53, and estradiol (E2) in tumor tissues of adult females with breast cancer and their relation to tumor grade, tumor size, and lymph node metastases (LNM). The study was conducted on 65 adult female participants with breast mass admitted to the operating theater in Al-Hussein Teaching Hospital and Al-Habboby Teaching Hospital in Nasiriyah, Iraq, from January to November 2021. Fresh breast tumor tissues were collated and homogenized for intracellular biochemical analysis using the enzyme-linked immunosorbent assay method. In total, 44 (58%) out of 65 patients, in the age range of 18-42 years and the mean \pm SD age of 32.55 \pm 6.40 years, had fibroadenomas, and other 21 (42%) cases, in the age range of 32-80 years and the mean \pm SD age of 56 \pm 14.4 years had invasive ductal carcinoma (IDC) breast cancer. Intracellular levels of HIF-1 α , p53, and E2 were elevated significantly ($P < 0.001$) in IDC cases compared to the benign group. The most malignant tumors of IDC cases were in grade III and sizes T₂ and T₃. The tissue concentrations of HIF-1 α , P53, and E2 were significantly elevated in patients with tumor stage T₃ compared to T₂ and T₁. A significant elevation was found in the levels of HIF-1 α , p53, and E2 in the positive LNM subgroup compared to the negative LNM group. Based on the obtained results, the prognostic value of the intracellular HIF-1 α is considered to be a useful prognostic factor in Iraqi women with ICD and the combination of a HIF-1 α protein with the nonfunctional p53 and E2 tends to indicate the proliferation, invasiveness, and metastases of the breast tumors.

Keywords: Intracellular estradiol, Intracellular hypoxia-inducible factor-1, Intracellular tumor suppression protein p53, Invasive ductal carcinoma, Tumor metastasis

1. Introduction

Breast cancer is a disease in which breast tissue cells change and divide uncontrollably, typically resulting in a lump or mass (1), and it is the most common malignancy affecting women's health with an increasing prevalence worldwide. About one out of eight women will be diagnosed with breast cancer in their lifetimes (2).

When the O₂ saturation level is decreased, the normal chemical reactions in living organisms are disrupted. Consequently, the cells and tissues will not function properly and a state of hypoxia will occur. Hypoxia is a characteristic feature of cancer (3). Breast tumors are the most solid tumor types and are invariably less well-oxygenated than the normal tissues from which they

arise, showing regions of hypoxia (4). Tumor cells favor hypoxia in an event known as the Warburg Effect which is a common phenotype of the cancer cells. In other words, it is the formation of the new vascular networks from pre-existing ones through the migration and proliferation of the differentiated endothelial cells (angiogenesis) that plays an important role in the development of cancer (5).

The hypoxia activates the hypoxia-inducible factor 1 (HIF-1) transcription factor with two subunits: HIF-1 α and HIF-1 β (6). HIF-1 α is precisely regulated by hypoxia and only expressed during hypoxic conditions as oxygen-dependent components of the HIF transcriptional complex (7). Hypoxia causes stabilization of the HIF-1 α protein and translocation of the HIF-1 complex to the nucleus. In the nucleus, HIF-1 binds to the DNA of the consensus sequence 5'-RCGTG-3' which in this mode HIF-1 allows the cells to adapt metabolism (4, 5).

Tumor suppressor protein p53 is coded by the TP53 gene and activated by various stresses, such as abnormal proliferation signals, DNA damage, hypoxia, and osmotic stress, which play a vital role in DNA damage. The p53 has been classified as a "guardian of the genome" due to its ability to coordinate multiple and diverse signaling pathways involved in this response (8). It is also considered a transcription factor that activates a variety of genes involved in DNA damage repair, cell cycle arrest, apoptosis, and many other gene clusters associated with diverse processes, such as DNA repair, transcription, cell adhesion, cell mobility, metabolism, and membrane functions. Mutation of p53 is a common occurrence in many cancers and is associated with the tumors' progression, resistance to chemotherapy, and poor prognosis (9).

Hormones play an important role in breast tumor growth. Estrogens have been shown to increase angiogenesis and genotoxic effects in experimental breast cancer and normal human breast tissues (10). Estrogens are converted to quinone metabolites, which directly bind to DNA and form adducts. Additionally, catechol estrogen metabolites undergo

redox cycling with a generation of oxygen-free radicals which damage DNA-bound guanine to form 8-OXO-guanine. The quinone adducts and 8-OXO-guanine bases are unstable and deleted from the affected DNA segments through a process called "depurination" (11). Error-prone DNA repair results in the formation of mutations at the depurinated sites. Accumulation of these mutations then contributes to the development of breast cancer (12).

This study aimed to evaluate the intracellular concentration of HIF-1 α , P53, and E2 in malignant and benign breast tissues and assess the association between these and several factors such as tumor grade, tumor size, and lymph node metastases (LNM).

2. Materials and Methods

This case-control study was carried out at Al-Hussein Teaching Hospital and Al-Habboby Teaching Hospital in AL- Nasiriyah city, Thi-Qar province, Iraq, from January to August 2021. The study sample included a total of 65 adult female patients suffering from breast mass who were admitted to the operating theater. A total of 44 (58%) out of 65 patients, in the age range of 18-42 years and the mean \pm SD age of 32.55 \pm 6.4 years were associated with the benign breast tumors diagnosed as fibroadenoma by histopathologists. The other 21 (32%) patients, in the age range of 32-80 years and the mean \pm SD age of 57 \pm 14.4 years, were associated with the breast cancer treated by mastectomy and diagnosed by histopathologists as invasive ductal carcinoma (ICD) cancer of not-otherwise-specified -type. Out of 21 breast cancer patients, the tumor tissues of 12 (32%) patients were associated with high grade (grade III) and poorly differentiated. The tumor tissues in 9 (42.9%) patients were intermediate grade (grade II) and moderately differentiated. Moreover, 5 (23.8%), 8 (38.1%), and 8 (38.1%) patients were with T1, T2, and T3 tissues, respectively. The examination of LNM showed that 8 (38%) and 13 (62%) patients had negative LNM and positive LNM, respectively.

Fresh tumor tissue samples of the breast were obtained directly after the removal of the tumor mass in

the operating theatre. Tumor samples were transported to the laboratory in sterile plain tubes (20 ml) containing ice-cold phosphate buffer saline (PBS) (0.01M, pH 7.4) in the icebox. The tumor tissues were washed twice with ice-cold PBS at the laboratory to remove the excess blood, then divided into 25 mg pieces to be homogenized by the homogenizer with PBS (1g:9ml) and sublimated with protease inhibitors (1ml:100ml) (13, 14). The homogenized tissues were then centrifuged at 4°C, 16,000 g (14,000 rpm) for 10 min. Supernatants were transferred to the new sterile tubes (1.5 ml) for further analysis and stored at -120°C until biochemical analysis. Samples were maintained on ice throughout the process (15, 16). The HIF-1 α , P53, and 17 β -estradiol (E2) were measured using the enzyme-linked immunosorbent assay method according to the manufacturer’s instructions using kits from Elabscience, USA, with code numbers: E-EL-h6066 and E-EL-H0910 for HIF-1 α and P53, respectively. The E2 kit was from Monobind INC, USA, with code number: 4925-300. The results were expressed as a picogram per milligram (pg/g). Histopathological examination data of the breast tumors were recorded in the medical records in the Histopathology unit of the hospitals.

2.1. Statistical Analysis

All data were analyzed using SPSS software (version 9). The normality of the data was assessed by the Shapiro-Wilk normality test. Chi-Square test and percentage were used to describe the clinical data. Differences were tested by a one-way analysis of variance followed by a Pearson correlation coefficient to analyze the correlation between variables. A value of $P < 0.01$ was considered statistically significant and $P > 0.05$ indicated no significant difference.

3. Results

The intracellular levels (pg/mg) of HIF-1 α , p53, and E2 were significantly higher in the IDC group compared to the fibroadenoma group (Table 1).

Table 1. Intracellular levels (pg/mg) of HIF-1 α , p53, and E2 in tumor tissues of 65 female patients

Parameters (pg/mg) mean \pm SD	Study groups		P-value
	Fibroadenoma (n=44) mean \pm SD	IDC* (n=21) mean \pm SD	
HIF1 α	65.34 \pm 2.01	742.49 \pm 19.97	0.00
P53	1009.94 \pm 5.27	1755.46 \pm 24.61	0.00
E2	220.69 \pm 1.50	339.14 \pm 15.51	0.00

* IDC: invasive ductal carcinoma

In this study, the results from malignant tumor tissues of 21 women showed a strong positive correlation between HIF-1 α and p53 ($P=0.01$), between HIF-1 α and E2 ($P=0.01$), and between p53 and E2 ($P=0.01$), as presented in figures 1- 3.

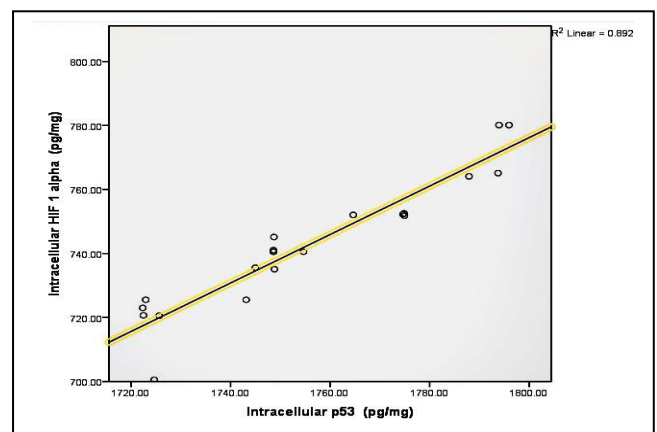


Figure 1. Correlation between intracellular HIF α 1(pg/g) and p53 pg/g in 21 malignant tumor tissues of the female patients with invasive ductal carcinoma type breast cancer

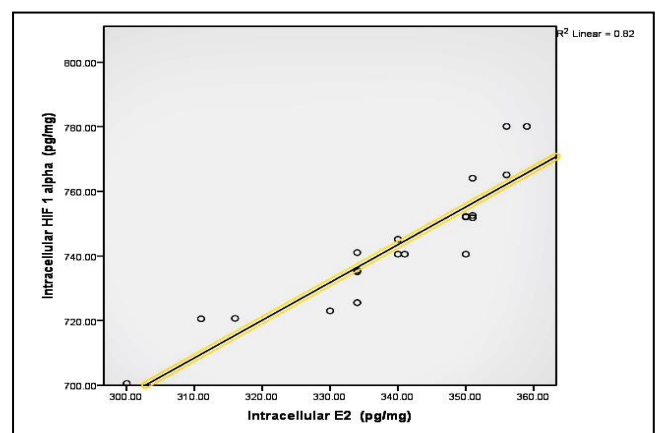


Figure 2. Correlation between levels of HIF α 1(pg/mg) and E2 (pg/mg) in malignant breast tissues of 21 adult female patients with invasive ductal carcinoma type breast cancer

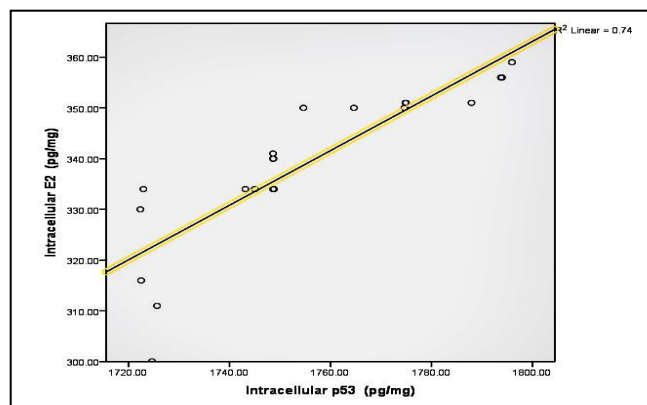


Figure 3. Correlation between levels of E2 (pg/mg) and P53 (pg/mg) in the malignant breast tissues of 21 adult female patients with invasive ductal carcinoma type breast cancer

Table 2 shows that tissue HIF α 1 and E2 levels were significantly higher in the patients with tumor grade III than in patients with tumor grade II.

According to table 3, levels of HIF α 1, p53, and E2 were significantly higher in the patients with tumor grade T3 than in patients with tumor grades T1 and T2.

The prognostic value of HIF-1 α , p53, and E2 showed a significant increase in the positive LNM subgroup compared to the negative LNM group (Table 4).

Table 2. Intracellular levels (pg/mg) of HIF-1 α , p53, and E2 in malignant breast tumors, based on the tumor grade of the breast cancer

Parameters (pg/mg) mean \pm S.D	Breast Malignant Tumor Grade Type*		P-value
	II(n=9)	III (n=12)	
HIF-1 α	725.28 \pm 11.78	755.40 \pm 14.14	0.00
P53	1733.73 \pm 12.16	1771.76 \pm 18.57	0.00
E2	325.22 \pm 12.88	349.58 \pm 6.28	0.00

*Breast malignant tumor grade type II: Moderately differentiated; type III: Poorly differentiated

Table 3. Comparison of the HIF-1 α , p53, and E2 levels (pg/mg) in malignant tumor tissues, based on tumor size of the breast cancer

Parameters (pg/mg) mean \pm SD	Breast Malignant Tumor Size Type*			P-value
	T1 (n=5)	T2 (n=8)	T3(n=8)	
HIF-1 α	723.06 \pm 2.46	734.87 \pm 14.23	762.25 \pm 12.2	0.003
P53	1727.31 \pm 8.94	1745.95 \pm 9.00	1782.57 \pm 11.73	0.000
E2	325.00 \pm 10.77	334.13 \pm 14.78	339.14 \pm 5.51	0.010

* Malignant tumor size type: T1 \leq 20 mm, T2 (>20mm-- \leq 50mm), T3>50 mm

Table 4. Levels (pg/mg) of HIF-1 α , p53, and E2, based on lymph node status of patients with the IDC¹ breast cancer

Parameters (pg/mg) mean \pm SD	lymph node metastasis ^{II}		P-value
	Negative (n=8)	Positive (n=13)	
HIF-1 α	723.31 \pm 10.89	754.49 \pm 14.11	0.00
P53	1731.87 \pm 11.55	1769.98 \pm 18.90	0.00
E2	324.13 \pm 13.32	348.38 \pm 7.41	0.00

I: Invasive ductal carcinoma

II: Lymph node metastasis: Negative: no regional lymph node metastases; Positive: metastases to movable ipsilateral level I, II axillary lymph node and more extensive.

4. Discussion

The HIF-1 α protein is continuously degraded via the ubiquitin pathway and has a short half-life (17). HIF-1 α has been also detected in many tumor types, whereas the corresponding levels of this protein in normal tissues are low to non-detectable (15). In the benign group, HIF-1 α has been detected, indicating that benign breast tumors are associated with hypoxia conditions in which HIF-1 α hydroxylation is impaired and the ubiquitination of HIF-1 α is blocked, the condition that can lead to “inflammatory hypoxia” (18, 19). Inflammation and hypoxia may be responsible for endothelial injury and are often associated with the up-regulation of several transcriptional factors including HIF-1 (15). Hypoxia was a salient feature of the most solid tumors. Some studies have shown that pro-inflammatory cytokines, such as tumor necrosis factor, regulate HIF-1 α expression in the breast tissues (20). Hypoxia is a characteristic feature of cancer, secondary to inflammation. Breast cancer usually grows very quickly and becomes insensitive to the blood flow in nearby veins. Areas of hypoxia can be found in as many as half of all the breast cancers (21) indicating that breast cancer consumes more oxygen and is more hypoxic and neovascularized than benign tumors. The expression rate of hypoxia is lower in benign breast disease than in carcinoma (22). The level of HIF-1 α in cells and the expression rate were affected by the intracellular oxygen concentration and the epigenetic control at DNA methylation status of gene regulatory regions (23). Malignant breast tumors are known to contain heterogeneously distributed hypoxic areas with a median oxygen tension of 23–28 mmHg, which is well below that for normal breast tissues (24). Therefore, these levels were significantly increased in IDC compared to the fibroadenoma samples.

In healthy cells, p53 is barely detectable since normally the p53 pathway operates in 'standby' mode and activation occurs in response to a variety of cellular stresses, such as DNA damage and expression of the activated oncogenes to prevent the outgrowth of the

aberrant cells by inducing cell cycle arrest, DNA repair, or programmed death (25). Most of the tumor cells are associated with overexpression of p53 in tissues, and mutations in the p53 gene were present in more than 50% of the patients with malignant tumors, including amino acid substitutions (26).

Increased p53 levels cause apoptosis which leads to a shorter life span; therefore, too much p53 can have negative effects. Further analyses of p53 protein accumulation (i.e. p53 dysfunction) and truncated mutant expression products of the p53 gene have shown that the mutant p53 proteins not only lose their tumor-suppressive functions but may also gain new abilities that enhance tumorigenesis (27). Extensive evidence has shown that mutation or functional inactivation of the tumor suppressor p53 is an almost universal feature of human cancer that changes the conformational structure of p53 and the production of mutant p53 proteins that loosen wild-type p53 tumor suppression functions and concomitantly acquire new oncogenic properties, such as deregulation of cell proliferation, increase of chemo-resistance, disruption of tissue architecture, promotion of migration, invasiveness, metastasis, and several other pro-oncogenic activities (28).

In fibroadenoma, E2, the dominant circulating estrogen, is believed to be stimulated by estrogen that regulates the growth of many breast tumors (29). An elevated plasma estradiol level is strongly associated with the risk of developing the disease, and the incidence of breast cancer is reported to be 2-3 times higher in women with estradiol 20-25% above the mean values (30). The role of E2 as a breast carcinogen has long been suspected and recently confirmed by epidemiological studies. Three major mechanisms are postulated to be involved in carcinogenic effects: stimulation of cellular proliferation through receptor-mediated hormonal activity, direct genotoxic effects by increasing mutation rates through a cytochrome P450-mediated metabolic activation, and induction of aneuploidy (31).

The previous studies showed a positive correlation between P53 and HIF-1 α , and it has been shown that the interplay between p53 and HIF-1 α plays a key role in the hypoxic response (32). HIF-1 α transcriptionally up-regulated p53 by binding to five response elements in the p53 promoter. In hypoxic cells, this HIF-1 α -induced p53 is transcriptionally inefficient while abundantly available for protein-protein interactions. This p53-induced chaperoning of HIF-1 α increases the synthesis of HIF-regulated genes and thus the efficiency of hypoxia-induced molecular changes (33). It has been reported that moderate p53 expression results in attenuated transcriptional activity of HIF-1 (34), and mutant p53 can promote cancer progression through its interplay with the hypoxia and HIF signaling pathway (32). It has been reported that tumors bearing p53 mutations are generally characterized by higher HIF-1 α levels and mutant p53 appears to stimulate HIF-1 α stabilization by blocking its interaction with MDM2 under the hypoxic condition (32).

On the other hand, an interaction was observed between HIF-1 α and E2 signaling pathways, and the secretion of the estrogen-responsive proteins via HIF-1 α up-regulation by breast cancer cells leads to an increase in endothelial cell migration and tubulogenesis *in vitro*. Therefore, the interaction between estrogen signaling and HIF-1 α regulation has major clinical importance (35).

Tumor hypoxia is facilitated by various factors, including tumor localization, tumor size, and blood flow, all of which affect oxygen accessibility and the rapid growth of the solid tumors, often resulting in the development of the hypoxic regions (34). The proliferation and potential association with more aggressive tumors and increase of the microvessel density lead to incessant growth and vascular abnormalities which finally leads to insufficient perfusion of the tumor mass (22). All evidence indicates an increase in HIF-1 α , p53, and E2 levels in cases associated with tumors higher than grade III and stage T3, and these results have been confirmed in

different studies (32, 35). However, some other studies showed no statistically significant differences in the detection of p53 among the poor, semi- or well-differentiated breast carcinomas (32).

The LNM, distant metastasis, and swollen lymph nodes (lymphadenopathy) have been established as standard prognostic factors for relapse-free or overall survival (35). A significant elevation in HIF-1 α , P53, and E2 has been associated with the positive LNM in which HIF-1 α is a central regulator of lymphangiogenesis and the swollen lymph nodes (36).

The prognostic value of intracellular HIF-1 α is considered to be a useful prognostic factor in IDC Iraqi women, and the combination of a HIF-1 α protein with nonfunctional p53 and estradiol tends to indicate the proliferation, invasion, and metastasis of breast tumors.

Authors' Contribution

Study concept and design: Z. A. K.

Acquisition of data: S. A. W. A.

Analysis and interpretation of data: Z. A. K.

Drafting of the manuscript: S. A. W. A.

Critical revision of the manuscript for important intellectual content: Z. A. K.

Statistical analysis: S. A. W. A.

Administrative, technical, and material support: Z. A. K.

Ethics

The current study had been evaluated and approved by the Ethics Committee at the Department of Clinical Biochemistry, College of Medicine, University of Thi-Qar, Thi-Qar, Iraq.

Conflict of Interest

The authors declare that they have no conflict of interest.

References

1. Coad J, Pedley K, Dunstall M. Anatomy and physiology for midwives e-book: Elsevier Health Sciences; 2019.

2. Ginsburg O, Yip CH, Brooks A, Cabanes A, Caleffi M, Dunstan Yataco JA, et al. Breast cancer early detection: A phased approach to implementation. *Cancer*. 2020;126:2379-93.
3. Cummins EP, Strowitzki MJ, Taylor CT. Mechanisms and consequences of oxygen and carbon dioxide sensing in mammals. *Physiol Rev*. 2020;100(1):463-88.
4. Zhou H, Guo M, Li J, Qin F, Wang Y, Liu T, et al. Hypoxia-triggered self-assembly of ultrasmall iron oxide nanoparticles to amplify the imaging signal of a tumor. *J Am Chem Soc*. 2021;143(4):1846-53.
5. Al-Ostoot FH, Salah S, Khamees HA, Khanum SA. Tumor angiogenesis: Current challenges and therapeutic opportunities. *Cancer Treat Res Commun*. 2021;28:100422.
6. Kewley RJ, Whitelaw ML, Chapman-Smith A. The mammalian basic helix-loop-helix/PAS family of transcriptional regulators. *Int J Biochem Cell Biol*. 2004;36(2):189-204.
7. Lee S-H, Golinska M, Griffiths JR. HIF-1-Independent Mechanisms Regulating Metabolic Adaptation in Hypoxic Cancer Cells. *Cells*. 2021;10(9):2371.
8. Feroz W, Sheikh AMA. Exploring the multiple roles of guardian of the genome: P53. *Egypt J Med Hum Genet*. 2020;21(1):1-23.
9. Alvarado-Ortiz E, de la Cruz-López KG, Becerril-Rico J, Sarabia-Sánchez MA, Ortiz-Sánchez E, García-Carrancá A. Mutant p53 gain-of-function: role in cancer development, progression, and therapeutic approaches. *Front Cell Dev Biol*. 2021;8:1868.
10. Maiti S, Nazmeen A. Impaired redox regulation of estrogen metabolizing proteins is important determinant of human breast cancers. *Cancer Cell Int*. 2019;19(1):1-13.
11. Yager JD, Davidson NE. Estrogen carcinogenesis in breast cancer. *N Engl J Med*. 2006;354(3):270-82.
12. Cavalieri E, Chakravarti D, Guttenplan J, Hart E, Ingle J, Jankowiak R, et al. Catechol estrogen quinones as initiators of breast and other human cancers: implications for biomarkers of susceptibility and cancer prevention. *Biochim Biophys Acta-Rev Cancer*. 2006;1766(1):63-78.
13. Kido H. Portable Systems for Sample Lysis and Homogenization. *Sample Preparation Techniques for Soil, Plant, and Animal Samples*: Springer; 2016. p. 117-23.
14. Mosher RA, Coetzee JF, Allen PS, Havel JA, Griffith GR, Wang C. Effects of sample handling methods on substance P concentrations and immunoreactivity in bovine blood samples. *Am J Vet Res*. 2014;75(2):109-16.
15. Heikal L, Ghezzi P, Mengozzi M, Ferns G. Assessment of HIF-1 α expression and release following endothelial injury in-vitro and in-vivo. *Mol Med*. 2018;24(1):1-10.
16. John B, Henry J. Clinical diagnosis and management by laboratory methods. *Clin Chem*. 2001;20(4):570-5.
17. Liu J, Zhang C, Zhao Y, Yue X, Wu H, Huang S, et al. Parkin targets HIF-1 α for ubiquitination and degradation to inhibit breast tumor progression. *Nat Commun*. 2017;8(1):1-16.
18. Corrado C, Fontana S. Hypoxia and HIF signaling: One axis with divergent effects. *Int J Mol Sci*. 2020;21(16):5611.
19. Yang Y-S, Choi JH, Rah J-C. Hypoxia with inflammation and reperfusion alters membrane resistance by dynamically regulating voltage-gated potassium channels in hippocampal CA1 neurons. *Mol Brain*. 2021;14(1):1-12.
20. Malkov MI, Lee CT, Taylor CT. Regulation of the Hypoxia-Inducible Factor (HIF) by Pro-Inflammatory Cytokines. *Cells*. 2021;10(9):2340.
21. Emami Nejad A, Najafgholian S, Rostami A, Sistani A, Shojaeifar S, Esparvarinha M, et al. The role of hypoxia in the tumor microenvironment and development of cancer stem cell: a novel approach to developing treatment. *Cancer Cell Int*. 2021;21(1):1-26.
22. Liu Z-j, Semenza GL, Zhang H-f. Hypoxia-inducible factor 1 and breast cancer metastasis. *J Zhejiang Univ Sci B*. 2015;16(1):32-43.
23. Cimmino F, Avitabile M, Lasorsa VA, Montella A, Pezone L, Cantalupo S, et al. HIF-1 transcription activity: HIF1A driven response in normoxia and in hypoxia. *BMC Med Gen*. 2019;20(1):1-15.
24. Vaupel P, Schlenger K, Knoop C, Höckel M. Oxygenation of human tumors: evaluation of tissue oxygen distribution in breast cancers by computerized O₂ tension measurements. *Cancer Res*. 1991;51(12):3316-22.
25. Bourdon J-C. p53 and its isoforms in cancer. *Br J Cancer*. 2007;97(3):277-82.
26. Bellazzo A, Sicari D, Valentino E, Del Sal G, Collavin L. Complexes formed by mutant p53 and their roles in breast cancer. *Breast Cancer* 2018;10:101.
27. Labuschagne CF, Zani F, Vousden KH. Control of metabolism by p53-cancer and beyond. *Biochim Biophys Acta-Rev. Cancer*. 2018;1870(1):32-42.

28. Shi Y, Norberg E, Vakifahmetoglu-Norberg H. Mutant p53 as a regulator and target of autophagy. *Front Oncol.* 2021;3300.
29. Estevão RAF, Nazário ACP, Baracat EC. Effect of oral contraceptive with and without associated estriol on ultrasound measurements of breast fibroadenoma: randomized clinical trial. *Sao Paulo Med J.* 2007;125(5):275-80.
30. Russo J, Russo IH. The role of estrogen in the initiation of breast cancer. *J Steroid Biochem Mol Biol.* 2006;102(1-5):89-96.
31. Kulendran M, Salhab M, Mokbel K. Oestrogen-synthesising enzymes and breast cancer. *Anticancer Res.* 2009;29(4):1095-109.
32. Zhang C, Liu J, Wang J, Zhang T, Xu D, Hu W, et al. The interplay between tumor suppressor p53 and hypoxia signaling pathways in cancer. *Front Cell Dev Biol.* 2021;9:273.
33. Madan E, Parker TM, Pelham CJ, Palma AM, Peixoto ML, Nagane M, et al. HIF-transcribed p53 chaperones HIF-1 α . *Nucleic Acids Res.* 2019;47(19):10212-34.
34. Opoku F, Bedu-Addo K, Titiloye NA, Atta Manu E, Ameh-Mensah C, Duduyemi BM. Expression profile of tumour suppressor protein p53 and its regulator MDM2 in a cohort of breast cancer patients in a Tertiary Hospital in Ghana. *Plos One.* 2021;16(10):0258543.
35. Yang J, Harris AL, Davidoff AM. Hypoxia and hormone-mediated pathways converge at the histone demethylase KDM4B in cancer. *Int J Mol Sci.* 2018;19(1):240.
36. Karataşlı V, Erkilinç S, Çakır İ, Can B, Karadeniz T, Gökçü M, et al. The effect of lymph node metastasis on overall survival and disease-free survival in vulvar cancer patients. *Ginekol Pol.* 2020;91(2):62-7.