

# PHYLOGENETIC IDENTIFICATION OF *Anaplasma phagocytophilum* IN HORSES IN BAGHDAD, IRAQ

Ahmed Noaman ALANI<sup>✉</sup> , and Afaf Abdulrahman YOUSIF<sup>✉</sup> 

Department of Internal and Preventive Veterinary Medicine, University of Baghdad, 28601 AlDawoodi, Iraq

<sup>✉</sup>Email: [ahmedana1977@covm.uobaghdad.edu.iq](mailto:ahmedana1977@covm.uobaghdad.edu.iq)

<sup>✉</sup>Supporting Information

**ABSTRACT:** This study aimed to detect *Anaplasma phagocytophilum* in horses through hematological and molecular tests. The 16S rRNA gene of the *Anaplasma phagocytophilum* parasite was amplified by polymerase chain reaction (PCR), then sequenced, and subjected to phylogenetic analysis to explore "Equine Granulocytic Anaplasmosis" (EGA) infection in three important gathering race horses areas in Baghdad governorate, Iraq. Blood samples were obtained from 160 horses of varying ages, three breeds, and both sexes, between January and December 2021. Prevalence and risk variables for anaplasmosis were analyzed using statistical odds ratio and chi-square tests. Results demonstrated that clinical anaplasmosis symptoms comprised jaundice, weight loss, paleness of mucus membrane with petechial hemorrhage in the third elides, and edema in extremities; There was no tick infestation. The hematological test did not significantly reveal decreases in red and white blood cells and platelet count. Microscopically found 11 from 160 smears (6.88%) had morulae within granulocytes, PCR results of *Anaplasma spp* primers was 32 positive amplicons (20%), and molecular sequencing results of "16S ribosomal RNA genes" confirmed 21 horses (13.13%) infected by *Anaplasma phagocytophilum* for the first time in Iraq horses. The results of the phylogenetic analysis revealed compatibility values similarity 98.81-99.76% with worldwide isolates. Mares occurred not significantly riskier; also age and breed were not illustrated risks of any group. This study is the first molecular detection of *Anaplasma phagocytophilum* in racehorses reared in Baghdad in Iraq. The outcomes of this study provide genetic data for early identification of *Anaplasma phagocytophilum* infection, treatment, and management of the illness in Iraq horses, as well as monitoring its transmission to the human population.

**Keywords:** *Anaplasma phagocytophilum*, Genetic, Mares, Phylogenetic analysis, Sequencing.

## INTRODUCTION

Horses (*Equus caballus*) are vulnerable to tick-borne infections, the most serious of which is *Anaplasma phagocytophilum*-induced "Equine Granulocytic Anaplasmosis (EGA)" (Hurtado et al., 2020; Laamari et al., 2020). It is a zoonotic illness that is responsible for "human granulocytic anaplasmosis" (Oğuz and Değer, 2021). It also infects equines, canines, and cattle (Hamidinejat et al., 2019), "A small ruminant Fever" (goats and sheep) (Aktaş et al., 2021), a wild deer (Kawahara et al., 2006), and rodents (Noaman, 2019). Many studies in Iraq diagnosed anaplasmosis by clinical, hematological and molecular methods, it has been found in sheep (Hamzah and Hasso, 2019), dogs (Al -Obaidi et al., 2020), as well as horses in Mosul city (Albadrani and Al-Iraqi, 2019), EGA in Baghdad city horses has not been confirmed via molecular or phylogenetic approaches.

Over a 28-year period, Saleem et al. (2018a) mapped the worldwide distribution of EGA and determined endemic zones. PCR technique confirmed in the united states of America (Subbiah et al., 2021; Thompson et al., 2022), in Europe (Dziegiel et al., 2013; Janzén et al., 2019), in Turkey (Oğuz, 2021), and in Iran (Noaman, 2019). Globally, ticks infest a wide variety of animal species and spread numerous illnesses, such as EGA (Narankhajid et al., 2018). Alali et al. (2022) documented distributed ticks in Iraq that transport different diseases including anaplasmosis. *Anaplasma phagocytophilum* is transmitted by Ixodidae hard ticks and proliferates in tick tissues and salivary glands (Boulanger et al., 2019). The bacterium travels transstadially but not transovarially, allowing transfer to vertebrate hosts via biting (Noaman, 2019). In animals' blood, it predominantly targets granulocytes, mainly neutrophils and eosinophils (Nelson et al., 2020), and forms morulae inside those cells, which may be utilized as a diagnostic tool for EGA identification, but "polymerase chain reaction" is the gold standard (Saleem et al., 2018b). Transplacental transmission in horses was documented (Dixon and Bedenice, 2021).

The novel species *Anaplasma phagocytophilum* comprises the old species "Ehrlichia phagocytophila, *E. equi*, and the pathogen of Human Granulocytic Ehrlichiosis (HGE)" (Dumler et al., 2001). It is a strict gram-negative, intracellular bacteria, and the microorganism is biologically linked to Rickettsia (Guzman et al., 2022).

"Equine Granulocytic Anaplasmosis" is generally a transitory illness (Shost et al., 2021), and Ordinarily in horses, self-limitation (Salvagni et al., 2010), Clinical symptoms differ from horse to horse, with the acute cases displaying pyrexia, depression, lethargy, inappetence (Sim et al., 2017), eyelid petechial hemorrhages, icterus, ventral edema, and

RESEARCH ARTICLE  
 PII: S222877012200025-13  
 Received: November 15, 2022  
 Revised: March 17, 2023  
 Accepted: March 22, 2023

death in severe cases (Salvagni et al., 2010), and less frequently, associated neurological manifestations are seen as ataxia, stiffness, and lying down (Gussmann et al., 2014; Nowicka et al., 2022). Hematological testing revealed thrombocytopenia, anemia (Albadrani and Al-Iraqi, 2019), and leukopenia (lymphopenia and neutropenia) can put the animal at risk of developing further infections (Saleem, et al., 2018a).

There has been a lack of research on these illnesses in horses, therefore only little is known regarding their occurrence (Tsachev et al., 2019), and the zoonotic feature of it make needs to monitoring of equestrian groups (Ebani, 2019), especially the duration of equine parasitemia averages just 129 days (Costa et al., 2021), as well as the diagnosis *Anaplasma phagocytophilum* in horses are required for the development of successful disease control strategies to avoid illness spread and possibly transfer to people (Seo et al., 2018). The purpose of this research would be to use nucleotide sequencing and phylogenetic analysis to investigate how prevalent *Anaplasma phagocytophilum* is in Baghdad horses.

## MATERIALS AND METHODS

### Ethical approval

Approval for this study was obtained from the committee of College of Veterinary Medicine/ University of Baghdad, Iraq. Number 39/PG on 7/1/2021.

### Animal groups and clinical examination

In the period between January and December of 2021 (with the exception of May and June, due to the coronavirus situation), 160 racehorses (60 Arabian, 75 Crossbreds, and 25 Thoroughbreds) were examined at three important equestrian facilities in Baghdad city. Iraqi Equestrian School, Alzwraa Zoo, and Alameria Equestrian Club. There were approximately ninety-one mares and sixty-nine stallions in the study, with an estimated age range of 2–25 years (Khazaeel et al., 2022). The clinical signs of animals were recorded, respiratory and heart rate, and rectal temperature, with other signs, were checked on each horse.

### Samples

Blood samples from studied horses were taken from the jugular vein and divided between a couple of three milliliters vacutainer tubes containing EDTA anticoagulant; one tube was utilized for Microscopic examination on slides, hematological investigation, and the other tube was stored in a freezer for PCR technique.

### Microscopic examination

Microscopic observation of blood films for detection of *A. phagocytophilum* morulae inside granulocytes was done according to Kerr (2008).

### Molecular genetic assay

To isolate genomic DNA from horse blood, a kit called “(Promega, USA, ReliaPrep™ Blood gDNA Miniprep System)” was used (Voytas, 2001; Badawi and Yousif, 2020). Purity and concentration of DNA measured using a NanoDrop (made by “Thermo Fisher Scientific Corporation, USA”) were found to be between 1.6 and 1.9 at 260/280 nm following the manufacturer's recommendations (Desjardins and Conklin, 2010).

### PCR protocol

For polymerase chain reaction, researchers employed a pair of primers derived from “the 16S ribosomal RNA genes” were used for the detection of *Anaplasma spp* in length 1469 bp that are EC9 forward “5' TACCTGTACGACTT 3'” and EC12 reverse “5' TGATCCTGGCTCAGAACGAACG 3'”(Kawahara et al., 2006).

Guidelines from Promega Corporation (2018) state that the volume of PCR reaction 25µl should contain 12.5µl of “(Promega, USA, 2X GoTaq® G2 Green Master Mix) that consist of Buffer (pH 8.5), 3 mM MgCl<sub>2</sub>, a mixture of 400 M each of dATP, dTTP, dCTP, and dGTP, and 50 units/mL of Taq DNA polymerase”, with 7.5µl of nuclease-free water, Three microliters of template DNA, one micro-liter of each *Anaplasma spp* primers previously described in 10 pmol concentration.

A thermocycling protocol begins with initial denaturation with a ten-minute heat-up to 94 °C, followed by forty cycles (denaturation via forty seconds heat-ups at 94 °C and annealing at 51.5 °C, extension for thirty seconds heat-ups at 72 °C, final extension with a ten-minute of 72 °C), and holding at 4 °C for a few hours. After being electrophoresed on agarose gel (1.5% concentration) using “(Promega, USA, Diamond™ Nucleic Acid Dye)”, amplified DNA fragments were most easily seen under UV light (Green and Sambrook, 2019).

### Sequencing, phylogenetic analyses

The 16S rRNA gene of *Anaplasma spp* was sequenced by (Macrogen lab, Korea) using EC9 and EC12 primers; the results were analyzed using BLAST of “the NCBI database [http://www.ncbi.nlm.nih.gov/BLAST]” (Hall, 1999), and recorded in international Gene bank as Iraqi reference attainment number. The “Molecular Evolutionary Genetics Analysis (MEGA 11)” program was used to construct phylogenetic trees, It was then contrasted with information on the same gene derived from sequencing projects throughout the world (Tamura et al., 2013)

### Hematological examinations

Includes leukocytes count, the estimate of thrombocytes, and, the counting of erythrocytes, measuring hemoglobin and hematocrit, and assessing anemia morphologically (based on the Wintrobe Index) (Walton and Lawson, 2021).

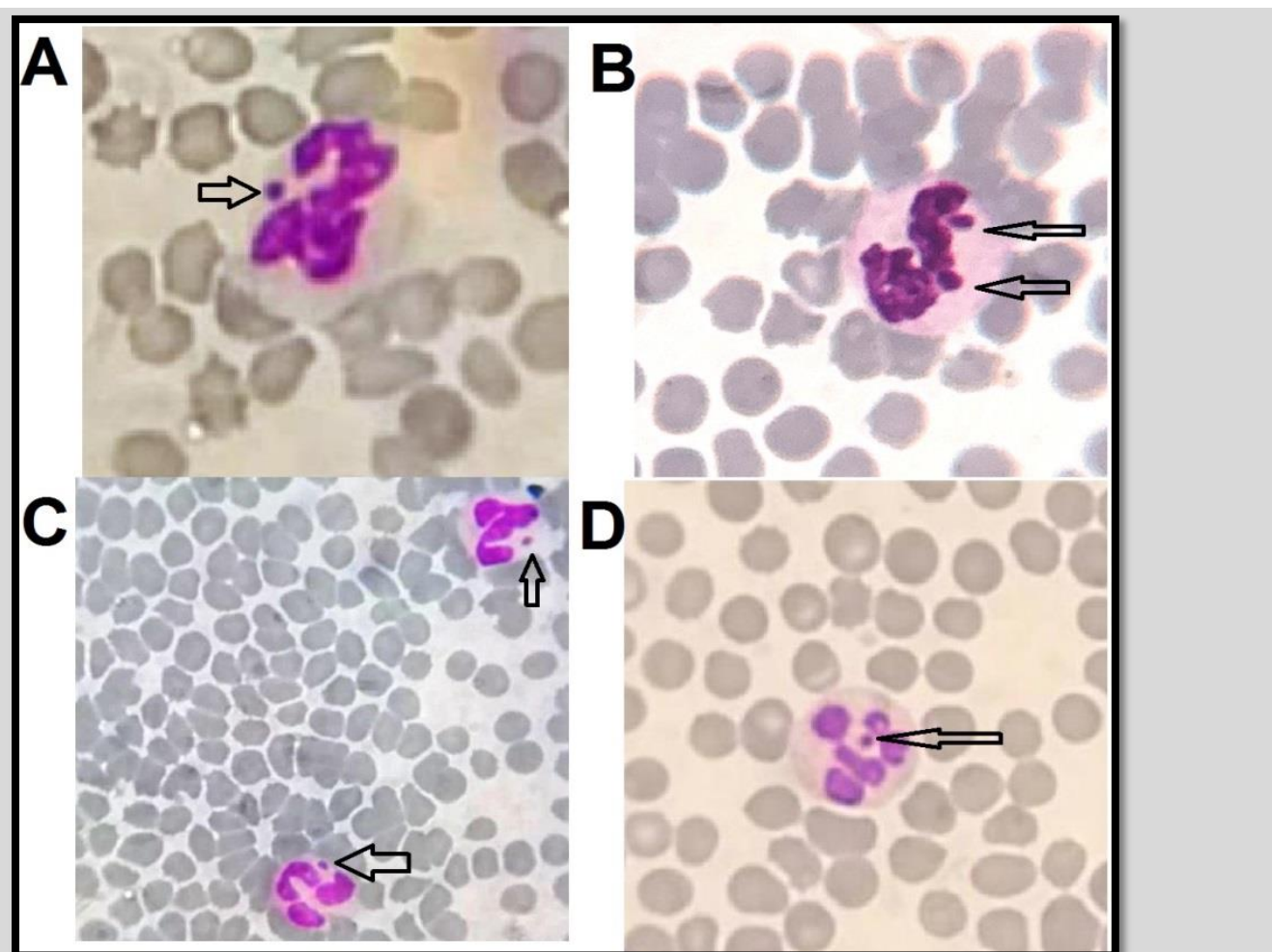
### Analytical statistics

Significant Results (at levels  $p < 0.05$ ) suggest a possible risk of infection, as determined by statistical analysis using the application “Statistical Package for the Social Sciences (SPSS) version 26.0 (IBM Corp., Chicago, USA)” (Bluman, 2012).

## RESULTS

### Microscopic examination

Microscopic examination revealed *A. phagocytophilum* morulae inside granulocytes were observed microscopically in eleven horses (6.875%) mostly in neutrophils as large rounded intra-cytoplasmic inclusion bodies after Romanowsky\_stained blood smears (Figure 1).



**Figure 1-** Horse blood with Intra-cytoplasmic inclusion bodies of *Anaplasma phagocytophilum*. A, C, and D: single large rounded (morulae) inside neutrophils, B: double large rounded (morulae) inside neutrophils. X100, Romanowsky\_stained blood smears.

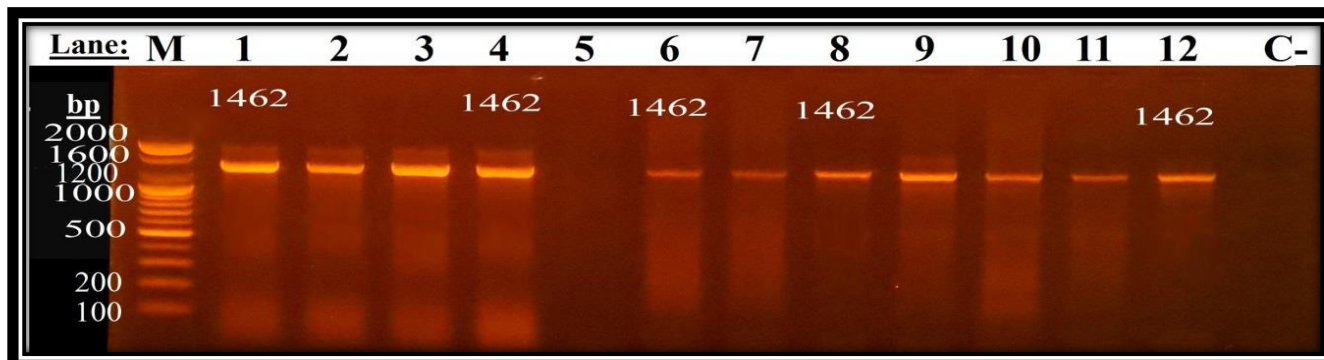
### Molecular study

The first stage of the Molecular study depend on “the 16S ribosomal RNA genes” PCR results of *Anaplasma spp* primers, it recorded 32 positive amplicons (20%) for *Anaplasma* species from 160 studying horse blood samples (Figure 2). Then sequenced for “16S ribosomal RNA” genes and BLAST results to recorded in “the National Center for Biotechnology Information (NCBI) Gene bank” which confirmed only 21 samples (13.125%) had positive *Anaplasma phagocytophilum* for the first time in horses in Baghdad, under accessions numbers: ON872233.1 to ON872235.1, ON872238.1 to ON872241.1, ON872243.1, ON872246.1 to ON872248.1, and OP218075.1 to OP218086.1. There was no significant association between microscopic and molecular results, chi-square( $X^2$ ) = 3.472222;  $df = 1$ ;  $P$  value = 0.062407; ( $P \leq 0.05$ ). The phylogenetic tree in **figure 3** showed these isolates had the highest similarity 98.81-99.76% sequence identity to isolates from Japan, China, Taiwan, dogs in Iraq, Belarus, Estonia, South Africa, Norway, Turkey, Austria, Russia, Sweden, South Korea, and Croatia, with 99-100% site coverage.

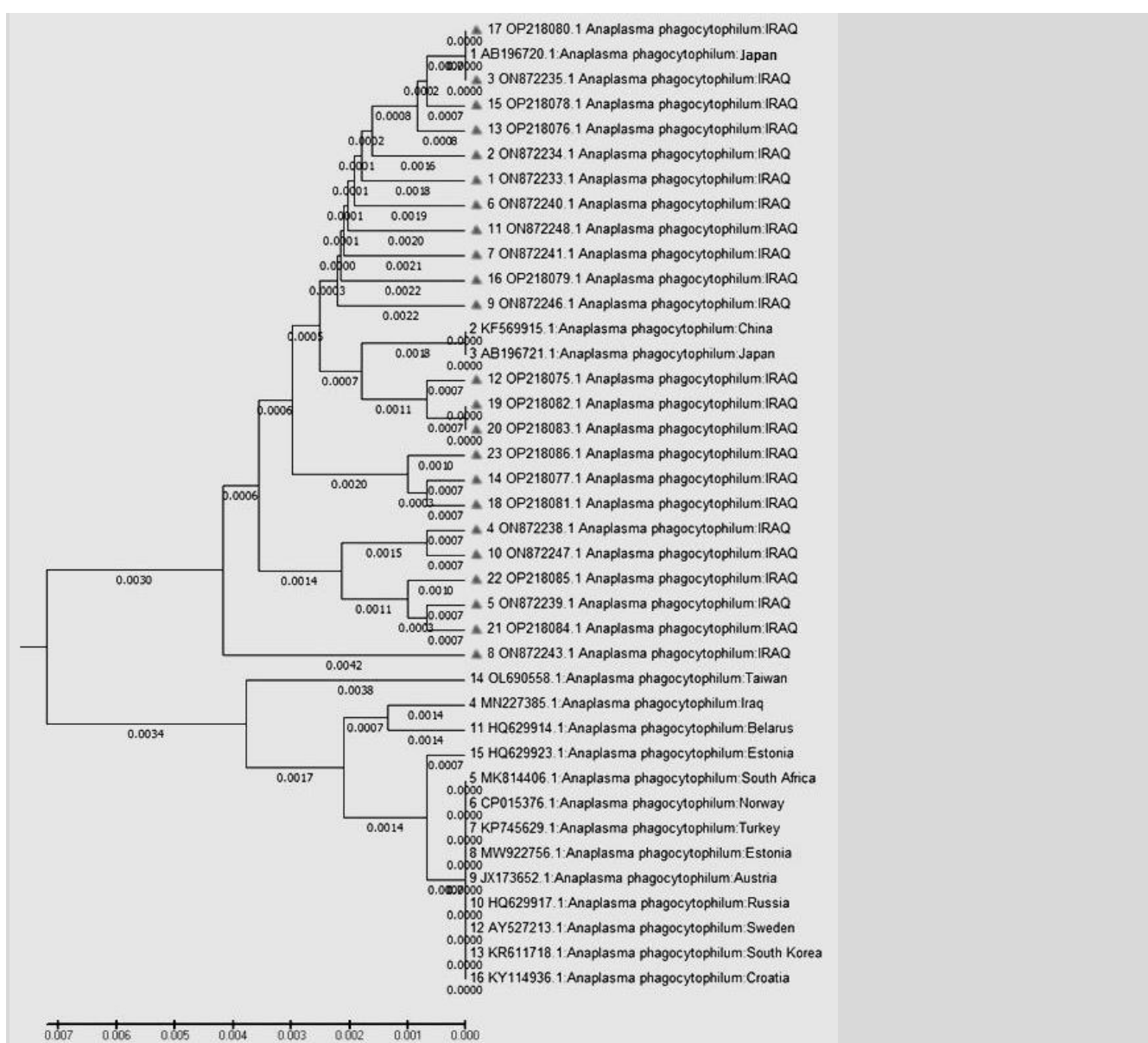


### Clinical signs of affected horse with *A. phagocytophilum*

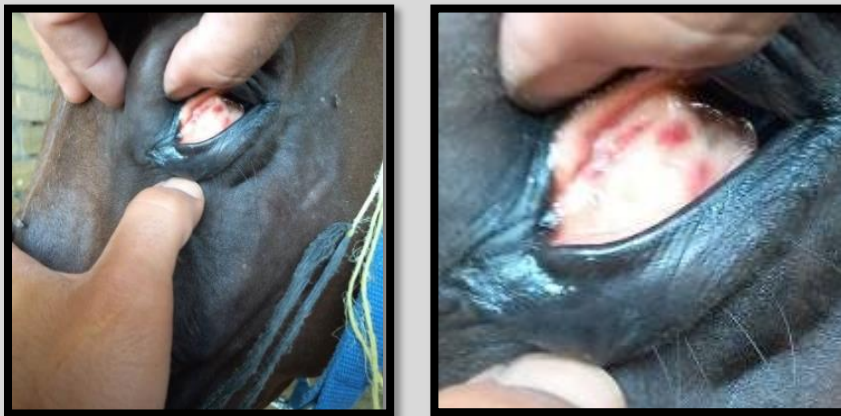The clinical symptoms of 21 affected horses were documented in Table 1 such as jaundice as the major signs occurred, Weight loss, paleness of mucus membrane with petechial hemorrhage in the third eyelids Figure 4, and edema in extremities. All horses revealed normal temperature ranged from 37.1 - 38.3Co on average 37.66Co, Nonetheless, there was a remarkable rise in the means of heart rate (40.05) (30-54 beats per minute), and respiratory rate was 17.9 (14-30 breath per minute).



**Figure 2-** Agarose gel cast loaded with PCR products and screened amplicons of *Anaplasma spp* 16S ribosomal RNA genes, at 1462bp, Stained by “Diamond™ Nucleic Acid Dye”, isolated from horses blood. Lane M: ladder 100 - 2000 bp, Lane 1-4 and 6-12: Positives amplicons of *Anaplasma spp*, Lane C-: control Negative, and Lane 5: Negative sample.



**Figure 3 -** Phylogenetic Scheme build with partial sequences of *Anaplasma phagocytophilum* isolates from “16S ribosomal RNA” genes. Horses Samples of Iraqi in this study marked by Gray Triangles.



**Figure 4 - Horse suffered paleness of mucus membrane with petechial hemorrhage in the third eyelids.**

#### Heamatological study

Table 2 showed non-significant differences between three parameters red, white blood cells, and platelets count in the 21 infected horses with *A. phagocytophilum* in comparison to 139 non-affected horses. Anemia occurred in five of the 21 horses infected with *Anaplasma phagocytophilum*, and was classified as (one macrocytic hypochromic and four Normocytic normochromic), leukopenia occurred in one case, and no thrombocytopenia was discovered.

#### Rate of infection according to predisposing factors

*Anaplasma phagocytophilum* infection demonstrated predisposing factors in Baghdad racehorses Table 3. Mares are more infected but without significant differences (1.2708 odd ratios) than stallions 13 and 8, respectively. Arabian and crossbred horses had equal susceptibility (13.33%) to infection and a non-significant (1.1282 odds ratio) than Thoroughbred horses (12%). Four years old horses had the highest percentage of infection (18.75%) and four folded (4.8462 odds ratio) than young horses in their second year, who had the lowest percentage of infection (4.55%), but were statistically insignificant.

**Table 1 - Clinical sings related to infection with *Anaplasma phagocytophilum***

Clinical sings	Affected horses with <i>Anaplasma phagocytophilum</i>		Clinical sings	Affected horses with <i>Anaplasma phagocytophilum</i>	
	(21)	(No.) %		(21)	(No.) %
Extremities edema	(1)	4.76%	Petechial hemorrhage in 3rd eyelid	(2)	9.52%
jaundice	(6)	28.57%	Wight loss	(3)	14.29%
Pale Mucus Membrane	(2)	9.52%	Poor performance	(1)	4.76%

**Table 2 - Erythrocytes, leukocytes, and thrombocytes counts in molecular positive and molecular negative horses.**

Parameters	Values in	Horses affected with <i>Anaplasma phagocytophilum</i> ( 21)	non affected horses (139)
RBCs count (10 <sup>12</sup> /L)		8.89+0.475 (4.9 - 12.9)	9.182 +0.175 (4.99 - 13.41)
Platelets count (10 <sup>9</sup> /L)		260.05+15.324 (145 - 389)	278.91+7.071 (128 - 642)
Total WBC count (10 <sup>9</sup> /L)		10.498 +0.649 (5.25 - 17.3)	11.17 +0.294 (5 - 25.4)

**Table 3 - Predisposition of race horses breeds, sex, and age to infected by *Anaplasma phagocytophilum*.**

Factor	Total Horses (160)	Number of infected horses (21)	%	(Odds Ratio) Confidence interval 95%
Sex	Stallions	8	11.59%	(1.2708)
	Mares	13	14.29%	0.4953 to 3.2608
Breed	Arabian Horses	8	13.33%	(1.1282) 0.2844 to 4.4748
	Thoroughbred	3	12 %	
	Crossbreds	10	13.33%	
Age	2 years	1	4.55%	(4.8462) 0.5403 to 43.464
	3 years	4	16.67%	
	4 years	6	18.75%	
	5 years	3	12%	
	6 -10 years	5	14.71%	
	<11 years	2	8.7%	

## DISCUSSION

Microscopic examination of Romanowsky-stained blood smears from 11 horses (6.88%) revealed the presence of *Anaplasma phagocytophilum* morulae within granulocytes (often in neutrophils) as large, round inclusion bodies inside the cytoplasm. It was equivalent to the results of 7.26% in the Europe study and 0% morulae in Chile (Dziegiel et al., 2013; Hurtado et al., 2020), in contrast, a higher percentage of 28.9% in Mosul City Iraq (Albadrani and Al-Iraqi, 2019). First time in horses in Baghdad, Sequenced the positive 16S rRNA gene samples and BLAST it in the NCBI database to confirmed the detection of *Anaplasma phagocytophilum* in horses in Iraq, with (99-100% site coverage) 98.81-99.76% identity to (AB196721) Japan (Kawahara et al., 2006), (KF569915) China, (OL690558) Taiwan, (MN227385) dogs in Iraq (Al -Obaidi et al., 2020), (HQ629914) Belarus (Katargina et al., 2012), (MW922756) Estonia (Vikentjeva et al., 2021), (MK814406) South Africa (Kolo et al., 2020), (CP015376) Norway (Crosby et al., 2022), (KP745629) Turkey (Aktaş and Özübek, 2015), (JX173652) Austria (Dyachenko et al., 2013), (HQ629917) Russia (Katargina et al., 2012), (AY527213) Sweden (Franzén et al., 2005), (KR611718) South Korea (Oh et al., 2012), (KY114936) Croatia (Huber et al., 2017) isolates.

Microscopic findings of *Anaplasma phagocytophilum* were around half times as confirmed by molecular sequencing results (21 horses, 13.13%) but this was not statistically significant, this molecular dominant agreed with 17.9% in the Europe study and 13.6% in Chile (Dziegiel et al., 2013; Hurtado et al., 2020), Baghdad's sequencing results nearly resampled other study results as 13% in Tunisia (Mghirbi et al., 2012), 7% in Pennsylvania (Thompson et al., 2022), 6.4% in Turkey (Oğuz, 2021), but higher than 1.8% in Poland (Teodorowski et al., 2021), and lower than 45% in Brazil (Salvagni et al., 2010). This illustrated the stability of molecular technique results that make it a better tool to diagnose *Anaplasma phagocytophilum* and disparity in microscopic results may due to differences in laboratory protocols and/or the presence of morulae related to another nonpathogenic *Anaplasma* spp.

This study of 21 molecular-positive horses for *A. phagocytophilum* revealed different symptoms, jaundice, and emaciation, only two cases had pale and petechial hemorrhages in 3rd eyelids, non-significant increased heart rates, nonspecific sings or asymptomatic infections this resemble the results of (Fielding et al., 2018) and (Ebani, 2019), on other hand affected horses with Anaplasmosis located in horses in Mosul city Iraq revealed fever, depression, and ataxia in addition to the signs (Albadrani and Al-Iraqi, 2019), and the same signs in horses located in united states (Subbiah et al., 2021). Ticks infestation was recorded in most research but not detected in these molecular-positive horses, this agreed with some studies in Algeria, Chile and Turkey (Hurtado et al., 2020; Laamari et al., 2020; Oğuz, 2021), the intense care with racehorses as daily washing and grooming may lead to the disappearance of a tick, and periodic medical checks prevent the development of severe signs in this investigation.

Hematological data demonstrated that 21 Molecular Positive *Anaplasma phagocytophilum* horses had a low average of Red, White, and platelet cell counts, with no significant changes compared to 139 Molecular Negative horses, One horse had macrocytic hypochromic anemia, whereas four horses had normocytic normochromic anemia; one had leukopenia, and none had thrombocytopenia. Similar CBC count average results were recorded in horses affected with *Anaplasma phagocytophilum* in Chile and Pakistan (Saleem, et al., 2018b; Hurtado et al., 2020), in divergence Mosul horses established anemia; leukopenia and thrombocytopenia (Albadrani and Al-Iraqi, 2019), in addition, Croatia (Gotić et al., 2017), Others found leukopenia and thrombocytopenia (Deane et al., 2021) (Fielding et al., 2018), and only leukopenia was detected in other research (Razzaq et al., 2015). Most positive cases revealed no specific clinical sings or remarkable hematological abnormality with a complete absence ticks infestation that indicated asymptomatic or transient or recovered from mild infection.

Risk factors not revealed any significant differences between mares and stallions, and between Arabian and thoroughbred or crossbred horses, in addition, any horse ages group. This outcome is parallel with other's (Mghirbi et al., 2012; Razzaq et al., 2015; dos Santos et al., 2019; Laamari et al., 2020; Drážovská et al., 2021; Oğuz, 2021), the females occurred slight more susceptible that disagreed with Pakistan research showed significant increase in males (Saleem, et al., 2018b).

## CONCLUSION

This study is the first molecular detection of *Anaplasma phagocytophilum* in racehorses reared in Baghdad in Iraq. The clinical signs were observed and found vital signs within reference limits and jaundice which were the major signs that occurred in 28.57% of molecular-positive horses. The results provide evidence that a large number of horses are exposed to *A. phagocytophilum* and that this bacterium is present in this area. Examined blood smears microscopically which revealed 6.875% *Anaplasma phagocytophilum* morulae inside granulocytes mostly in neutrophils as large rounded intracytoplasmic inclusion bodies. Hemtologically analyzed blood samples and illustrated parameters of red, white blood cells, and platelets count were non-significant differences in the 21 molecularly infected horses and anemia occurred in five cases. Susceptible to infection occurred higher in Mares at 14.29%, 4 years old at 18.75% and Arabian breed at 13.33%. PCR results were 21 samples (13.125%) had positive *Anaplasma phagocytophilum*, and the recording Phylogenetic tree had the highest similarity 98.81-99.76% to global isolates. Compatibility of our outcomes to global isolates with similar prevalence rates will facilitate applying universal protocols of control and treatment trials and using PCR techniques for early detection of infection, and management of the illness in horses in Iraq, as well as monitoring its transmission to the human population.



## DECLARATIONS

### Corresponding author

Ahmed Noaman ALANI; Department of Internal and Preventive Veterinary Medicine, University of Baghdad, 28601 AIDawoodi, Iraq; E-mail: ahmedana1977@covm.uobaghdad.edu.iq;  ORCID: <https://orcid.org/0000-0003-4804-8217>

### Authors' contribution

All authors have seen and confirmed the authenticity of all the raw data and contributed equally to the details of this manuscript.

### Conflict of interests

The authors have not declared any conflict of interests.

### Acknowledgements

Not applicable.

### Consent to publish

All authors agree to publish the article "Phylogenetic Identification of *Anaplasma phagocytophilum* in Horses in Baghdad, Iraq" in an online journal of animal and feed research.

## REFERENCES

- Aktaş M, and Özübek S (2015). Bovine anaplasmosis in Turkey: First laboratory confirmed clinical cases caused by *Anaplasma phagocytophilum*. *Veterinary Microbiology*, 178(3–4): 246–251. <https://doi.org/10.1016/j.vetmic.2015.05.021>
- Aktaş M, Özübek S, and Uluçesme M C (2021). Molecular detection and phylogeny of *Anaplasma phagocytophilum* and related variants in small ruminants from Turkey. *Animals*, 11(3):1–11. <https://doi.org/10.3390/ani11030814>
- Al –Obaidi S S A, Khalaf Al-Ani J M, and Al-Shammari N B (2020). Molecular Detection of Some *Anaplasma* Species in Blood of Dogs in Baghdad Province, Iraq. *The Iraqi Journal of Veterinary Medicine*, 44(1): 39–45. <https://doi.org/10.30539/ijvm.v44i1.933>
- Alali F, Jawad M, and AL-obaidi Q T (2022). a Review of Endo- and Ecto-Parasites of Equids in Iraq. *Journal of Advances in VetBio Science and Techniques*, 7(1): 115–129. <https://doi.org/10.31797/vetbio.940901>
- Albadrani B A, and Al-Iraqi O M (2019). First detection of equine anaplasmosis and hemoplasmosis of horses in Mosul City, Iraq. *Advances in Animal and Veterinary Sciences*, 7(2): 106–111. <https://doi.org/10.17582/journal.aavs/2019/7.2.106.111>
- Altschul S F, Gish W, Miller W, Myers E W, and Lipman D J (1990). Basic local alignment search tool. *Journal of Molecular Biology*, 215(3): 403–410. [https://doi.org/10.1016/S0022-2836\(05\)80360-2](https://doi.org/10.1016/S0022-2836(05)80360-2)
- Badawi N M, and Yousif A A (2020). *Babesia canis* spp. In dogs in Baghdad Province, Iraq: First molecular identification and clinical and epidemiological study. *Veterinary World*, 13(3): 579–585. <https://doi.org/10.14202/vetworld.2020.579-585>
- Boulanger N, Boyer P, Talagrand-Reboul E, and Hansmann Y (2019). Ticks and tick-borne diseases. *Medecine et maladies infectieuses*, 49(2):87-97. <https://doi.org/10.1016/j.medmal.2019.01.007>
- Bluman A G (2012). *Elementary statistics: a step by step approach* (8th ed.). McGraw-Hill [https://www.google.iq/books/edition/Elementary\\_Statistics/EXGskgAACAAJ?hl=ar](https://www.google.iq/books/edition/Elementary_Statistics/EXGskgAACAAJ?hl=ar)
- Costa S C L, de Souza Freitas J, Carvalho F S, Pereira M J S, Cordeiro M D, da Fonseca A H, and et al. (2021). Frequency and factors associated of potential zoonotic pathogens (*Borrelia* spp., *Rickettsia* spp., *Leishmania* spp., and *Anaplasma phagocytophilum*) in equids in the state of Bahia, Brazil. *Parasites and Vectors*, 14(1): 1–10. <https://doi.org/10.1186/s13071-021-04777-4>
- Crosby F L, Eskeland S, Bø-Granquist E G, Munderloh U G, Price L D, Al-Khedery B, and et al. (2022). Comparative Whole Genome Analysis of an *Anaplasma phagocytophilum* Strain Isolated from Norwegian Sheep. *Pathogens*, 11(5): 601. <https://doi.org/10.3390/pathogens11050601>
- Deane E L, Fielding C L, Rhodes D M, and Howard E J (2021). Upper respiratory signs associated with *Anaplasma phagocytophilum* infection in two horses. *Equine Veterinary Education*, 33(3): e58–e61. <https://doi.org/10.1111/eve.13128>
- Desjardins P, and Conklin D (2010). NanoDrop microvolume quantitation of nucleic acids. *Journal of Visualized Experiments*, e2565(45): 1–4. <https://doi.org/10.3791/2565>
- Dixon C E, and Bedenice D (2021). Transplacental infection of a foal with *Anaplasma phagocytophilum*. *Equine Veterinary Education*, 33(3): e62–e66. <https://doi.org/10.1111/eve.13233>
- dos Santos T M, Roier E C R, Pires M S, Santos H A, Vilela J A R, Peckle M, and et al. (2019). Molecular evidence of *Anaplasma phagocytophilum* and *Theileria equi* coinfection in horses from Rio de Janeiro, Brazil. *Veterinary and Animal Science*, 7: 100055. <https://doi.org/10.1016/j.vas.2019.100055>
- Drážovská M, Vojtek B, Mojžisová J, Kolenicová S, Kofvek F, Prokes M, and et al. (2021). The first serological evidence of *Anaplasma phagocytophilum* in horses in Slovakia. *Acta Veterinaria Hungarica*, 69(1): 31–37. <https://doi.org/10.1556/004.2021.00007>
- Dumler J S, Barbet A F, Bekker C P J, Dasch G A, Palmer G H, Ray S C, and et al. (2001). Reorganization of genera in the families Rickettsiaceae and Anaplasmataceae in the order Rickettsiales: Unification of some species of Ehrlichia with Anaplasma, Cowdria with Ehrlichia and Ehrlichia with Neorickettsia, descriptions of six new species combi. *International Journal of Systematic and Evolutionary Microbiology*, 51(6): 2145–2165. <https://doi.org/10.1099/00207713-51-6-2145>
- Dyachenko V, Geiger C, Pantchev N, Majzoub M, Bell-Sakyi L, Krupka I, and et al. (2013). Isolation of canine *Anaplasma phagocytophilum* strains from clinical blood samples using the *Ixodes ricinus* cell line IRE/CTVM20. *Veterinary Microbiology*, 162(2–4): 980–986. <https://doi.org/10.1016/j.vetmic.2012.10.021>
- Dziegiel B, Adaszek L, Winiarczyk M, Garcia-Bocanegra I, Carbonero A, Debiak P, and et al. (2013). Comparative analysis of 16S RNA nucleotide sequences of *Anaplasma phagocytophilum* detected in the blood of horses from various parts of Europe. *Journal of Medical Microbiology*, 62(PART 12): 1891–1896. <https://doi.org/10.1099/jmm.0.058636-0>
- Ebani V V (2019). Serological evidence of *Anaplasma phagocytophilum* and spotted fever group *Rickettsia* spp. exposure in horses from central Italy. *Pathogens*, 8(3):88. <https://doi.org/10.3390/pathogens8030088>

- Fielding C L, Rhodes D M, Howard E J, and Mayer J R (2018). Evaluation of potential predictor variables for PCR assay diagnosis of *Anaplasma phagocytophilum* infection in equids in Northern California. *American Journal of Veterinary Research*, 79(6): 637–642. <https://doi.org/10.2460/ajvr.79.6.637>
- Franzén P, Aspan A, Egenvall A, Gunnarsson A, Åberg L, and Pringle J (2005). Acute Clinical, Hematologic, Serologic, and Polymerase Chain Reaction Findings in Horses Experimentally Infected with a European Strain of *Anaplasma phagocytophilum*. *Journal of Veterinary Internal Medicine*, 19(2): 232–239. <https://doi.org/10.1111/j.1939-1676.2005.tb02687.x>
- Gotić J, Brkljača Bottegare N, Kiš I, Crnogaj M, Mrljak V, and Beck R (2017). A first case of equine granulocytic anaplasmosis in Croatia - A case report. *Veterinarski Arhiv*, 87(1): 113–120. <http://intranet.vef.hr/vetarhiv/papers/2017-87-1-11.pdf>
- Green M R, and Sambrook J (2019). Analysis of DNA by agarose gel electrophoresis. *Cold Spring Harbor Protocols*, 2019(1): 6–15. <https://doi.org/10.1101/pdb.top100388>
- Gussmann K, Czech C, Hermann M, Schaarschmidt-Kiener D, and von Loewenich F D (2014). *Anaplasma phagocytophilum* infection in a horse from Switzerland with severe neurological symptoms. *Schweizer Archiv Für Tierheilkunde*, 156(7): 345–348. <https://doi.org/10.1024/0036-7281/a000605>
- Guzman N, Yarrarapu S N S, and Beidas S O (2022). *Anaplasma Phagocytophilum* (Anaplasmosis). StatPearls, Treasure Island (FL). <http://www.ncbi.nlm.nih.gov/pubmed/30020713>
- Hall T (1999). BioEdit: a user friendly biological sequence alignment editor and analysis program for Windows 95/98/NT. *Nucleic Acids Symp Serie*, 41(8): 95–98. <https://cir.nii.ac.jp/crid/1572261549883338880>
- Hamidinejat H, Bahrami S, Mosalanejad B, and Pahlavan S (2019). First molecular survey on *Anaplasma phagocytophilum* revealed high prevalence in rural dogs from Khuzestan province, Iran. *Iranian Journal of Parasitology*, 14(2): 297–302. <https://doi.org/10.18502/ijpa.v14i2.1142>
- Hamzah K J, and Hasso S A (2019). Molecular prevalence of *Anaplasma phagocytophilum* in sheep from Iraq. *Open Veterinary Journal*, 9(3): 238–245. <https://doi.org/10.4314/ovj.v9i3.8>
- Huber D, Reil I, Duvnjak S, Jurković D, Lukačević D, Pilat M, and et al. (2017). Molecular detection of *Anaplasma platys*, *Anaplasma phagocytophilum* and *Wolbachia* sp. but not *Ehrlichia canis* in Croatian dogs. *Parasitology Research*, 116(11): 3019–3026. <https://doi.org/10.1007/s00436-017-5611-y>
- Hurtado C, Torres R, Pérez-Macchi S, Sagredo K, Uberti B, de Souza Zanatto DC, and et al. (2020). Serological and molecular detection of *Anaplasma phagocytophilum* in Thoroughbred horses from Chilean racecourses. *Ticks and Tick-borne Diseases*, 11(4):101441. <https://doi.org/10.1016/j.ttbdis.2020.101441>
- Janzén T, Petersson M, Hammer M, Aspán A, and Dinnétz P (2019). Equine Granulocytic Anaplasmosis in Southern Sweden: Associations with coniferous forest, water bodies and landscape heterogeneity. *Agriculture, Ecosystems and Environment*, 285(June): 106626. <https://doi.org/10.1016/j.agee.2019.106626>
- Katargina O, Geller J, Alekseev A, Dubinina H, Efremova G, Mishaeva N, Vasilenko V, Kuznetsova T, Järvekülg L, Vene S, Lundkvist Å, and Golovljova I (2012). Identification of *Anaplasma phagocytophilum* in tick populations in Estonia, the European part of Russia and Belarus. *Clinical Microbiology and Infection*, 18(1): 40–46. <https://doi.org/10.1111/j.1469-0691.2010.03457.x>
- Kawahara M, Rikihisa Y, Lin Q, Isogai E, Tahara K, Itagaki A, Hiramitsu Y, and Tajima T (2006). Novel genetic variants of *Anaplasma phagocytophilum*, *Anaplasma bovis*, *Anaplasma centrale*, and a novel *Ehrlichia* sp. in wild deer and ticks on two major islands in Japan. *Applied and Environmental Microbiology*, 72(2): 1102–1109. <https://doi.org/10.1128/AEM.72.2.1102-1109.2006>
- Kerr M G (2008). *Veterinary Laboratory Medicine: clinical Biochemistry and haematology* (2nd ed.). Wiley-Blackwell. <https://www.wiley.com/en-us/Veterinary+Laboratory+Medicine%3A+Clinical+Biochemistry+and+Haematology%2C+2nd+Edition-p-9780470779958>
- Khazaeel K, Pesarakli H, Mashhadi A G, and Borujeni M P (2022). Age estimation of Arabian mares by incisors morphometry and dentition changes. *Veterinary Research Communications*, 46(2): 405–417. <https://doi.org/10.1007/s11259-021-09865-5>
- Kolo A O, Collins N E, Brayton K A, Chaisi M, Blumberg, L, Freaun J, and et al. (2020). *Anaplasma phagocytophilum* and other *Anaplasma* spp. in various hosts in the mniisi community, Mpumalanga Province, South Africa. *Microorganisms*, 8(11): 1–21. <https://doi.org/10.3390/microorganisms8111812>
- Laamari A, Azzag N, Tennah S, Derdour S Y, China B, Bouabdallah R, and et al. (2020). Seroprevalence of antibodies against *Anaplasma phagocytophilum* and *Borrelia burgdorferi* in horses (*Equus caballus*) from northern Algeria. *Journal of Veterinary Research (Poland)*, 64(3): 413–419. <https://doi.org/10.2478/jvetres-2020-0045>
- Mghirbi Y, Yach H, Ghorbel A, and Bouattour A (2012). *Anaplasma phagocytophilum* in horses and ticks in Tunisia. *Parasites and Vectors*, 5(1): 1–7. <https://doi.org/10.1186/1756-3305-5-180>
- Narankhajid M, Yeruult C, Gurbadam A, Battsetseg J, Aberle S W, Bayartogtokh B, Joachim A, and Duscher G G (2018). Some aspects on tick species in Mongolia and their potential role in the transmission of equine piroplasms, *Anaplasma phagocytophilum* and *Borrelia burgdorferi* L. *Parasitology Research*, 117(11): 3557–3566. <https://doi.org/10.1007/s00436-018-6053-x>
- Nelson C M, Herron M J, Wang X R, Baldrige G D, Oliver J D, and Munderloh U G (2020). Global Transcription Profiles of *Anaplasma phagocytophilum* at Key Stages of Infection in Tick and Human Cell Lines and Granulocytes. *Frontiers in Veterinary Science*, 7(March): 1–17. <https://doi.org/10.3389/fvets.2020.00111>
- Noaman V (2019). A review on *Anaplasma phagocytophilum* as a zoonotic agent: review article. *Tehran University Medical Journal*, 76(12): 778–785. [https://tumj.tums.ac.ir/browse.php?a\\_id=9413&sid=1&slc\\_lang=en](https://tumj.tums.ac.ir/browse.php?a_id=9413&sid=1&slc_lang=en)
- Nowicka B, Polkowska I, Adaszek Ł, Łopuszynski W., Komsta R, Korolczuk A, and et al. (2022). Horse anaplasmosis as a cause of CNS infections and the use of computed tomography as a diagnostic imaging tool to present of its cerebral form: literature review supplemented with a clinical case. *Medycyna Weterynaryjna*, 78(5): 239–243. <https://doi.org/10.21521/MW.6651>
- Oğuz B (2021). First Molecular Detection and Phylogenetic Analysis of *Anaplasma phagocytophilum* in Horses in Mus Province of Turkey. *Kocaeli Üniversitesi Sağlık Bilimleri Dergisi*, 7(3): 312–318. <https://doi.org/10.30934/kusbed.895438>
- Oğuz B, and Değer M S (2021). Current Status of Zoonotic Pathogen *Anaplasma phagocytophilum* in Türkiye: A Molecular Approach. *International Journal of Medical Parasitology and Epidemiology Sciences*, 2(4): 79–80. <https://doi.org/10.34172/ijmpes.2021.22>
- Oh SS, Chae JB, Hur MJ, Cho YK, and Chae JS (2012). Isolation of *Anaplasma phagocytophilum* from *Apodemus agrarius* in Korea. *Korean Journal of Veterinary Science*, 55(1): 168–169. <https://scholar.kyobobook.co.kr/article/detail/4050026778126>
- Razzaq F, Khosa T, Ahmad S, Hussain M, Saeed Z, Khan M A, and et al. (2015). Prevalence of *Anaplasma phagocytophilum* in horses from Southern Punjab (Pakistan). *Tropical Biomedicine*, 32(2): 233–239. <http://www.ncbi.nlm.nih.gov/pubmed/26691251>
- Saleem S, Ijaz M, Farooqi S, Ghaffar A, Ali A, Iqbal K, and et al. (2018a). Equine Granulocytic Anaplasmosis 28 years later. *Microbial Pathogenesis*, 119(June 2020): 1–8. <https://doi.org/10.1016/j.micpath.2018.04.001>
- Saleem S, Ijaz M, Farooqi S H, Rashid M I, Khan A, Masud A, Aqib A I, Hussain K, Mehmood K, and Zhang H (2018b). First molecular evidence of equine granulocytic anaplasmosis in Pakistan. *Acta Tropica*, 180: 18–25. <https://doi.org/10.1016/j.actatropica.2017.12.032>



- Salvagni C A, Dagnone A S, Gomes T S, Mota J S, Andrade G M, Baldani C D, and et al. (2010). Serologic evidence of equine granulocytic anaplasmosis in horses from central West Brazil. *Revista Brasileira de Parasitologia Veterinaria*, 19(3): 135–140. <https://doi.org/10.1590/s1984-29612010000300002>
- Seo M G, Ouh I O, Choi E, Kwon OD, and Kwak D (2018). Molecular detection and phylogenetic analysis of anaplasma phagocytophilum in horses in Korea. *Korean Journal of Parasitology*, 56(6): 559–565. <https://doi.org/10.3347/kjp.2018.56.6.559>
- Shost N, Russell A, Lopez L, Bechelli J, and Suagee-Bedore J K (2021). 147 Serological and molecular detection of Anaplasma in East Texas horses. *Journal of Equine Veterinary Science*, 100: 103610. <https://doi.org/10.1016/j.jevs.2021.103610>
- Sim RR, Joyner PH, Padilla LR, Anikis P, and Aitken-Palmer C (2017). Clinical Disease Associated With Anaplasma Phagocytophilum Infection In Captive Przewalski's Horses (Equus Ferus Przewalskii). *Journal of Zoo and Wildlife Medicine*, 48(2): 497–505. <https://doi.org/10.1638/2016-0247R.1>
- Subbiah M, Thirumalapura N, Thompson D, Kuchipudi S V, Jayarao B, and Tewari D (2021). Detection of Anaplasma Phagocytophilum in Horses With Suspected Tick-Borne Disease in Northeastern United States by Metagenomic Sequencing. *Frontiers in Veterinary Science*, 8(673193): 1–7. <https://doi.org/10.3389/fvets.2021.673193>
- Tamura K, Stecher G, Peterson D, Filipski A, and Kumar S (2013). MEGA6: Molecular evolutionary genetics analysis version 6.0. *Molecular Biology and Evolution*, 30(12), 2725–2729. <https://doi.org/10.1093/molbev/mst197>
- Teodorowski O, Kalinowski M, Winiarczyk D, Janecki R, Winiarczyk S, and Adaszek Ł (2021). Molecular surveillance of tick-borne diseases affecting horses in Poland—Own observations. *Veterinary Medicine and Science*, 7(4): 1159–1165. <https://doi.org/10.1002/vms3.451>
- Thompson D, Thirumalapura N R, and Tewari D (2022). Prevalence of Anaplasma phagocytophilum and Borrelia burgdorferi infection in horses from Pennsylvania (2017-2019) using antibody and organism-based detection. *Journal of the American Veterinary Medical Association*, , 260(14), 1834–1838. <https://doi.org/10.2460/javma.22.06.0232>
- Tsachev I, Baymakova M, and Pantchev N (2019). Seroprevalence of Anaplasma phagocytophilum, Ehrlichia spp. And Borrelia burgdorferi infections in horses: First report from northern Bulgaria – Short communication. *Acta Veterinaria Hungarica*, 67(2): 197–203. <https://doi.org/10.1556/004.2019.021>
- Vikentjeva M, Bragina O, and Geller J (2021). Ticks and tick-borne pathogens in popular recreational areas in {Tallinn}, {Estonia}: an underestimated risk of tick-borne diseases. pp. 1–15. <https://www.researchsquare.com/article/rs-543083/v1> ; <https://doi.org/https://doi.org/10.21203/rs.3.rs-543083/v1>
- Voytas D (2001). Agarose gel electrophoresis. *Current Protocols in Molecular Biology*, 51(2): 2.5A.1-2.5A.9. <https://doi.org/10.1002/0471142727.mb0205as51>
- Walton R M, and Lawson C A (2021). Equine Hematology. In R. M. Walton, R. L. Cowell, and A. C. Valenciano (Eds.), *Equine hematology, cytology, and clinical chemistry* (2nd ed., p. 348). John Wiley and Sons. <https://doi.org/10.1002/9781119500186>