



Study the Effect of Zinc Oxide Nanoparticles on Regeneration of Damaged Sciatic Nerve in Rabbits Model

Hussein H. Nahi^{*1}, Muntadher Salman Ashour² and Omar A. Bader³

¹Department of Surgery and Obstetrics, College of Veterinary Medicine, Al-Qasim Green University, Babylon, Iraq.

²Department of Biology, College of Education for Pure Sciences Ibn Al-Haitham, University of Baghdad, Baghdad, Iraq.

³Department of Surgery and Theriogenology, College of Veterinary Medicine, University of Mosul, Mosul, Iraq.

THIS study was conducted on 20 rabbits were divided into control and treated groups (8 and 16 weeks) for each groups. Animals were anesthetized then left sciatic nerves were compressed for 30 seconds with artery forceps. Zinc oxide nanoparticles have been used in treated groups 56 days of daily monitoring. Improved gait and absent knuckling were observed at days 20 and 28 post-operatively. Muscle was strong contraction and modest atrophy during day 56 PO, while the treated group's animals displayed notable sensory responses ($p \leq 0.05$). In the treated group the highest ratio of relative gastrocnemius muscle weight measurement (RGMWM) were (0.74) and (0.71) at weeks 16th and 8th, respectively, and (0.54) in the control group on day 112 PO. On day 56 PO, there was a no significant decrease in RGMW values in the control group at 16 and 8 ws (30 and 25)% respectively and 25% in the treated group. The conductive velocity at 8 weeks PO showed non-significant differences between all groups, the latency value of the treated group was 3 ms and 4 ms in the left and right limb, respectively, and amplitude values in the left and right limbs in each treated and control groups were (3.5 and 6.9) Mv and (2.83 and 5.2) Mv respectively. In the treated group histopathological examinations showed advantage in quality and quantity of nerve fibrous formatting in a period of 16 weeks PO. We witnessed that ZnO-NP were a vital and essential for enhancing nerve regeneration.

Keywords: Schiatic nerve, Zinc oxide Nanoparticles, regeneration.

Introduction

According to studies, traditional Chinese medicine (TCM) may influence peripheral nerve regeneration by encouraging the growth of Schwann cells and elevating the production of a number of neurotrophic factors [1] be decreased nerve fibre regeneration [2,3].

Nanotechnology has revolutionized various fields, ranging from public health to synthetic materials. The main product of nanotechnology, that is, nanoparticles (NPs), can be defined as materials having at least one unit distance in the nanometer range (1-500 nanometers) [4]. In order to produce these NPs, the biological pathway has received more awareness due to many important features such as environmental safety, a friendly deal with less toxic

byproducts, the need for a gentle reaction state, and the use of limited and normal agents. Thus, the nanoparticle agents produced through the biological approach are relatively constant and safer, with a much greater variety in size and shape. The most widely utilized biological assay for creating NPs is to employ pure plant extracts to prepare environmentally friendly NPs, reducing harmful chemicals [5]. Plant-augment synthesis of NPs results in synthesizing NPs of specific shapes and sizes. Researchers are also designated to employ an aqueous medium containing an emulsifier solution for potentially suspending and stabilizing materials at nanoscale size [6,7]. ZnO NPs have also been noted to augment the generation of reactive oxygen species (ROS), especially hydrogen peroxides. ZnO's many important applications involve clear stimulation,

*Corresponding author: Hussein H. Nahi, E-mail: husseinsur85@vet.uoqasim.edu.iq . Tel.: 07726808395 (Received 23/11/2023, accepted 31/12/2023)

DOI: 10.21608/ejvs.2023.250656.1679

©2024 National Information and Documentation Center (NIDOC)

anti-fungal photochemicals, and anti-bacterials. Also, the UV-filtering capabilities of ZnO NPs impart them into the spot of exploring interdisciplinary.

The current study focuses on ZnO NPs phytosynthesis use. Distinct biological examinations were performed involving antimicrobial, antioxidant, and antiproliferative experiments. Using natural extracts has the advantage of synthesizing ZnO nanoparticles by coating nanoparticles with pharmacologically different biomolecules on the surface of metallic oxide, permitting the coupling of the nanoparticles with the bacterial membrane receptors [8]. Molecules such as flavones, amides, aldehydes, polysaccharides, and synthesized green nanoparticles have better biomedical efficacy than synthesized chemicals.

This study's goal had been to evaluate the effect of zinc oxide on nerve regeneration in a compressed sciatic nerve experimental model utilizing a variety of evaluations, which includes functional tests like the walking test and electrophysiological checks, the degree of muscle atrophy, and histomorphometric measurements of the nerves.

Material and Methods

Ethical approve

The ethical committee of Al-Qasim Green University's/College of Veterinary Medicine's/Department of Surgery and Obstetrics, approved the protocol of this study, which adhered to the tenets of the declaration of Helsinki and HIPAA. As it was a retrospective study, informed consent was viewed by ethical committee of Al-Qasim Green University's/College of Veterinary Medicine's.

Design of experimental animals

Twenty adult, healthy male rabbits weighing between 1.5 and 2.5 kg were used in this study. The animals were kept in separate cages and given access to unlimited amounts of food and water. Prior to the procedure, the animals were acclimated for 10 days in their separate cages. Ceftriaxone (20 mg/kg) was injected intramuscularly once daily for five days. On the first day and day 14 of acclimatization, anthelmintic injections of 0.2 mg/kg Ivermectin (Ivomec, Holland) and 0.4 ml/kg SC were administered..

Rabbits were randomly divided into two equal groups (n=10). The sciatic nerve of the left side in

all animals was induced by compressing with artery forceps for 30 seconds. Only the sciatic nerve was hurt in the first group (control), whereas in the second group, the compressed sciatic nerve was treated with zinc oxide nanoparticles. The animals were then euthanized, and the compressed nerves of each subgroup were re-examined at weeks 8 and 16 post operations (PO), respectively.

Surgical Protocol

To produce anesthesia, a mixture of 35mg/kg ketamine hydrochloride (Kepro[®], Holland) and 25mg/kg xylazine hydrochloride (Xyla[®], Holland) has been administered intramuscularly [9].

Hair on the skin of the animal was trimmed from the lateral and caudal part of the left hindlimb, from the level of the iliac wing dorsally to the level of the sacrum caudally, and ventrally to the level of the stifle joint. Heparin (Hexatane 20[®], Jordan), isopropyl alcohol (70%) (Manufactured by Jaya Pelita Pharma. SDN). BHD and iodine tincture (Lebanon) were used for skin disinfection.

The limb was kept out of the surgical area and from the stifle joint to the distal extremity by covering it with a latex glove and attaching it to the limb with adhesive tape. A sterile skin towel had been employed for wrapping the glove (Sempermed[®], Austria), and towel clips were used to secure it to the limb. The animal was facing right in lateral recumbency The fenestrated drape's aperture, which was placed at the location of the planned surgery, was draped over the left hind limb.

The stifles had been used as markers and the greater trochanter of the femur had been palpated. On the posterior-lateral thigh, the greater trochanter was situated at the level of the distal femur, and skin was incised there utilizing scalpel blade 21.

Employing scalpel blade 15, the subcutaneous tissue and fascia lata were then excised along the same line. The biceps femur muscle has been divided cranially, and the semitendinosus muscle was separated posteriorly by blunt dissection using Mayo scissors in order to expose the sciatic nerve and cut it free from the surrounding tissues [10,19]. The nerve had been gently compressed through putting a wooden tongue depressor under it while employing artery forceps (Figure 1).

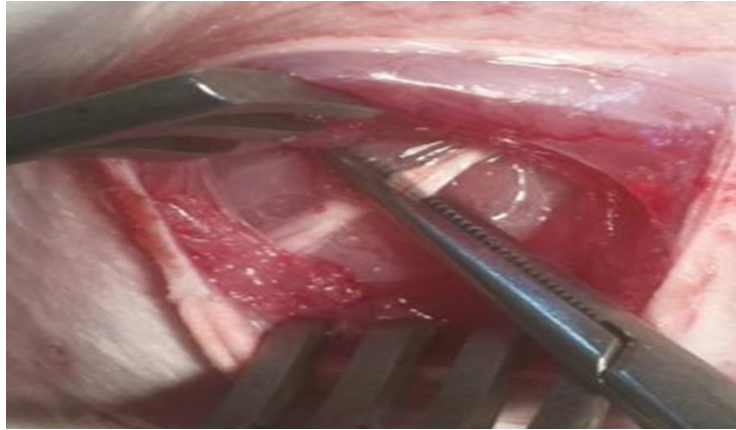


Fig. 1. The compressed section of the sciatic nerve

Preparation of nanoparticles

Green synthesis of ZnO nanoparticles

To synthesize nanoparticles of ZnO, the green method was applied. For this purpose, mg zinc acetate was utilized as a precursor. The extract solutions were subsequently filtered, and the eluted extract solution was isolated for use in the subsequent production of zinc oxide (ZnO). The direct synthesis of ZnO or the concentration of solid extracts might both be done using the eluent solution. Following that, reactions between zinc precursors and plant extracts were conducted at various pH and temperature levels.

The nine parts of 100 mg of pure extract were added to 10 mg of 0.45 Molar (M) zinc acetate dihydrates and 10 mL of 0.45 M NaOH, respectively. The three complex mixtures were then stirred constantly for 2 hours at 900 rpm using a magnetic stirrer until a yellow precipitate was formed. Then, Tocopheryl Polyethylene Glycol Succinate (TPGS) surfactant at a concentration of 0.05 was added to the mixture to provide coating and stability to the product and reduce the particle size, and it was steered for 60 min. Next, the solution was transferred to probing sonication at altitude 80 at cycle 1:1. The suspension was centrifuged at 12000 rpm for 30 min. The pellet was resuspended in water. The ZnO nanoparticle suspension was filtered into precipitates in a glass cylinder with Whatman filter paper, washed with distilled water and then with ethanol to remove the impurities, and oven-dried at 50°C for 2 hours. The yellow powder obtained was ground manually using a mortar and pestle [11].

The optimal concentration of 5 mg per ml was prepared by dissolving 50 mg of zinc nanoparticles in 0.5 ml of Dimethyl Sulfoxide (DMSO) and then adding de-ionized water to reach 10 ml. In addition, only 0.5 of the solution was used to flush the area of the damaged nerve.

Clinical Signs Evaluation

From the beginning of the study through day 112 PO, clinical motor and sensory sciatic nerve reflexes were assessed every day.

Motor Function Evaluation

All animals were inspected every day from the start of the study until day 112 PO, when the study came to a conclusion, using the grading criteria. We noted when the animals started to walk and their capacity to do so. The different gaits were categorized as normal, crouching, or heel-crawling. Grades for knuckling included normal, mild, moderate, and severe. The strength of a muscle contraction was classified as mild, moderate, or powerful. Grades of muscular atrophies were normal, mild, moderate, and severe [12].

Sensory Function Evaluation

Beginning at the end of the third week and continuing until study completion on day 84 PO, nerve sensory functioning were monitored on a weekly basis. The presence or absence of the toe spreading reflex, lateral aspect leg sensation, toe pinch, and toe prick were used to grade sensory functions and clinical symptoms. Foot withdrawal and vocalization tests were assessed using the lateral aspect leg feeling, toe pinch, and toe prick tests; successful outcomes indicating recovery were noted.

Electrophysiological analysis (EMG)

We carried out electrophysiological examinations 8 weeks after the nerve injury. The sciatic nerve had been removed from the body and separated from it by about 3 cm. It was then placed in an AD instrument chamber that was filled with buffer solution, and stimulation electrodes as well as negative and positive clamping (recording) electrodes were attached to it. We calculated the conductive velocity by dividing the distance between recording electrodes (by mm) by the time difference between capacity proximal and capacity distal stimulations at a frequency of two pulses per second.

The amplitude in microvolts (V) is measured from the electric baseline to the peak of the negative phase of the motor response, and the latency time in milliseconds (ms) is measured from the shock artifact to the initial negative peak deflection of the response from the video display apparatus's electric baseline.

Relative gastrocnemius muscle weight measurement (RGMWM)

The skin-overlying gastrocnemius muscle was dissected away through a longitudinal incision on the posterior aspect of the operated limb. After making an incision, the gastrocnemius muscles were immediately weighed. In order to control for differences in weight between different rabbits, the contralateral muscle was also removed.

The proportion of muscle mass loss was then determined for each muscle using a separate 0.0001g weight (denervated muscle weight vs. contralateral muscle weight). The muscle weight has been expressed as a ratio of the operated limb (left) to the unoperated right limb (negative control) in order to calculate the relative gastrocnemius muscle weight (RGMW). The percentage of the test side's muscle weight to the muscle weight used as a negative control and one of the factors for the recovery of motor function is known as the RGMW.

Histopathological Examinations

Nerve biopsies were taken on 8 and 16 weeks PO. Biopsies were fixed in 10% buffered formalin, then routinely processed with alcohol and embedded in

paraffin [13]. After blocking, the block was trimmed at 5-6 micrometer, stained by hematoxylin and eosin, and finally examined under a light microscope.

Statistical Analysis

The data has been analyzed and means and standard deviations (MSD) were calculated. SPSS stands for Statistical Package for the Social Sciences. To statistically compare the groups, 16.0 software, non-parametric tests, Kruskal-Wallis, and Mann-Whitney tests were employed. P values 0.05 were regarded as significant.

Results

Clinical Assessment of Motor and Sensory Nerve Functions

All animals in the two groups showed signs of dysfunction characterized by flaccid paralysis of the operated hind limb movement from day 1 to day 4 PO. The animals were reluctant to flex their limbs from the hock joint and below and remained crouched on the floor of the cage.

Treated group (8 weeks)

The gait and knuckling improved to normal on days 20 and 29 PO, respectively. Muscle force contraction was strong, and muscle mass atrophy became moderate, Table 1. The toe spread, lateral aspect leg feeling, toe pinch, and toe prick all appeared on days 35, 39, 46, and 48 after the operation on the operated left hind limb, respectively Table 2.

TABLE 1. Motor clinical observations for all groups on day 112 PO

Clinical signs	Control Group	Treated Group 8ws	Treated Group 16ws
Onset	1.3±0.3 ^C	2.7±0.2 ^B	4.1±0.2 ^A
Walk			
Crouch	1±0.0 ^A	0.3±0.25 ^B	0.3±0.2B ^c
Crawl	2±0.0 ^A	0.9±0.45 ^B	0.5±0.3B ^c
Normal	3±0.0 ^A	3±0.0 ^A	3±0.0 ^A
	Knuckling		
Severe	1±2.6 ^A	0.5±0.26B	0.2±0.3 ^C
Moderate	2±0.1 ^A	1.3±0.45B	0.4±0.5 ^{Bc}
Mild	3±0.0 ^A	1.3±0.75B	0.5 ±0.7 ^{Bc}
Normal	0.0±0.0 ^C	1.7±0.77B	3±0.0 ^A
	Muscle Contraction Force (MCF)		
Strong	3±0.0 ^C	3±0.0 ^b	3±0.0 ^A

a,b,c Values with comparable superscripts in the same row of (MSD, n=5) are not significant at (p≤ 0.05)

TABLE 2. Clinical sensory observations for all groups on day 112 PO

Sensory Signs	Control	Treated 8ws	Treated 16ws
Toe spread	0±0 ^B	1±0 ^A	1±0 ^A
Lateral leg sensation	0±0 ^B	1±0 ^A	1±0 ^A
Toe pinch	0±0 ^B	1±0 ^A	1±0 ^A
Toe prick	0±0 ^b	1±0 ^A	1±0 ^A

Treated group (8 ws)

On day 38 PO, we saw the animals regaining their capacity to walk normally. Knuckling was modest throughout the research and remained so till the end. The muscular contraction force increased significantly on day 24 PO Table1. By the end of the research, skin sensation had gradually moved from the foot to the fetlock joint. The lateral leg sensation, toe pinch, and toe prick sensations were all still missing Table 2.

Control Group (8 weeks)

A significant finding was that all animals had normal gaits on day 28 PO. The knuckling disappeared on day 27 PO, and the muscle force contraction became strong on day 47 PO Table 1. The toe-spread sensation was observed on day 43 PO. Lateral aspect leg response appeared on day 50 PO, and toe pinch and toe prick were present on day 53 PO (Table 2). The gait and knuckling improved to normal on days 40 and 58 PO, respectively. Muscle force contraction was strong, and muscle mass atrophy became moderate Table 1. The toe spread, lateral aspect leg feeling, toe pinch, and toe prick all appeared on days 70, 78, 93, and 95 after the operation on the operated left hind limb, respectively Table 2.

Treated group (16 weeks)

On day 77 PO, the animals' ability to walk normally was restored. Mild knuckling persisted until the study's conclusion. On day 48 PO (Table 1), the muscular contraction force increased significantly. By the end of the research, skin sensation had gradually moved from the foot to the fetlock joint.

The lateral leg sensation, toe pinch, and toe prick sensations were all still absent Table2.

Control Group (16 weeks)

The fact that all animals walked normally on day 56 PO was a noteworthy discovery. On day 57 PO, the knuckling stopped, and on day 47 PO, the muscle power contraction became strong Table1. The toe spread sensation was observed on day 85 PO. Lateral aspect leg response appeared on day 99 PO, and toe pinch and toe prick were present on day 105 PO Table 2.

Clinical Sensory Observations

Sensory clinical signs, including toe spread, lateral leg sensation, toe pinch, and toe prick, did not show sensory reflexes. Animals in the control group showed significant sensory reflexes ($p \leq 0.05$) compared to the control group on day 56 PO Table 3.

Relative gastrocnemius muscle weight measurement (RGMWM)

The highest RGMWM ratio and less muscle atrophy were observed in the treated group (0.74) and (0.71) at weeks 16th and 8th, respectively. On the other hand, the smallest RGMWM ratio (0.54) was observed in the control group on day 112 PO Table 3. A comparison of the relative gastrocnemius muscle weight means showed that the gastrocnemius muscle started to atrophy after sciatic nerve injury. However, on day 112 PO, the RGMW values in the control group were significantly lower ($p \leq 0.05$) than in the control groups after 16 weeks (30%) and 8 weeks (25%) Table 3.

TABLE 3. Analysis of the relative gastrocnemius muscle weight measurements at the control, 16-week, and 8-week treatment levels using statistical methods.

Time	Control 16 ws %	Treated 8 ws %	Treated 16 ws%
112 days	54.3±1.7 ^C	71.4±0.6 ^B	74.8±0.8 ^A

LSN: left sciatic nerve; RSN: right sciatic nerve .The similar superscript letters denote non-significant differences at $p < 0.05$.

Electrophysiological analysis

The electrophysiological studies were carried out by isolation nerve procedures. Electromyography was done after 8 weeks.

Conductive velocity at 8 weeks PO:

The conductive velocity at 8 weeks PO showed non-significant differences between the treated 16 (53.44 ± 3.56 Aa) and the control group (47.48 ± 2.77 Aa) at $P < 0.05$ but showed substantial variations in the same group between the left sciatic nerve (OP) and the right sciatic nerve. This study showed that the values of latency in the left limb were 3 meters (ms) and 4 ms in the right limb in the treated group. While in the control group, the values of latency were 3.3 ms in left limb and 5.2 ms in the right limb at 8 weeks PO. The values of amplitude were 3.5 Millivolt (Mv) in the left limb and 6.9 Mv in the right limb in the treated group, while in the control group they were 2.83 Mv in the left limb and 5.2Mv in the right limb.

Motor Clinical Observations

According to the study's findings, animals in the treated group began moving their limbs and walked more quickly than those in the control group. The animals' gait returned to normal in all groups, although they did so more quickly in the treatment groups (40 days) and (56 days) than in the control group (77 days). Knuckling disappeared in the treated groups after 57 and 58 days, with a significant difference ($p < 0.05$), but it persisted in the control group until the end of the trial. All groups had substantial muscle contraction forces, although in the treatment (43.6 days) and (47 days) groups, contraction began earlier than in the control group (48 days). According to the study's findings, animals in the treated group began moving their limbs and walked more quickly than those in the control group. This study showed that regression of knuckling severity did not last in the treated group on day 57 but persisted in the control group until the end of the study on day 112 PO.

Sensory Clinical Observations

The current investigation shown that in each group of treatment, sensory clinical indications are suggestive of the progression of sensation. The absence of sensation and the presence of knuckling, especially when it is severe and the animal walks on the dorsum of the foot, help in the development of the atrophic ulcer. Furthermore, continuous cleaning

of the foot by licking, in the absence of sensation, makes it worse and were more worse in the control group. The toe-spreading reflex was the key clinical indicator that aided in the assessment and restoration of sensory function. Early on, it wasn't present in either of the groups, but as time went on, it appeared in both treatment groups on day 112 PO. Foot drop was noticeable right away after the nerve was transacted, and it frequently disappeared or lessened before the muscles were reinnervated. Observations of the gait alone are not sufficient to determine the precise commencement of the response since the symptoms of sciatic nerve injury are distinct. A reliable evaluation of the beginning and development of recovery is achieved by restricting observations to the muscle area directly innervated by the sciatic (peroneal) nerve

Histopathological Examination

Treated Group

Histopathological examination of the damaged sciatic nerve in the control and treated groups revealed basophilic nuclei of dividing Schwann cells with a thick layer of myelin, excellent orientation, myelination of nerve fibers, and little fibrous tissue at the epineurium (Figure 2).

At 16 weeks PO, there was a recognizable node of Ranvier, a large diameter of dense axon population with a thick myelin sheath, proliferation of Schwann cells, and robust angiogenesis (Figure3).

Histopathological findings in this study showed highly vascularized injured sciatic nerves due to blood supply efficacies brought about by the presence of neurotrophic factors capable of angiogenesis through affected endothelial cells.

Control Group

The injured sciatic nerve in the control group had Wallerian degenerative nerve fibers with few Schwann cell nuclei, fibrous connective tissue, and inflammatory cells, including macrophages and lymphocytes, eight weeks after the lesion (Figure 2), while at 16 weeks post-injury, regenerative nerve fibers were found to be disoriented. The nerve fiber displayed circular, clogged blood channels, vacuolar degeneration, inflammatory cell infiltration, and a lack of differentiated labeling, few Schwann cells, and inflammatory cell infiltration. Collagen fiber growth in nerve fascicles and Schwann cell degeneration (Figure 3).

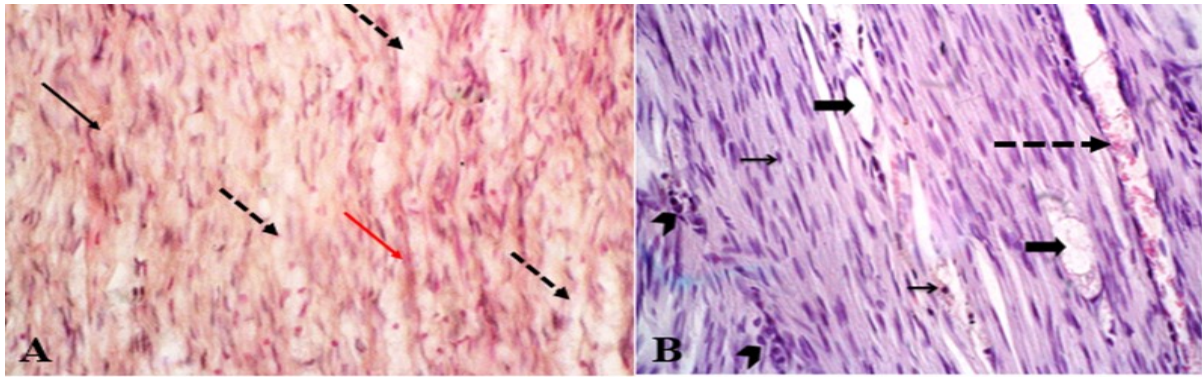


Fig. 2. Light micrographs of sciatic nerve at 8 weeks PO A: control group showing mild Schwann cells proliferation (black row), a mild contentious nerve fiber myelination (red row) with moderate nerve fiber demyelination (black dot row), B: treated group showing thick bundle nerve fiber myelination with severe Schwann cells proliferation (black row), eosinophilic debris of myelin and axonal disintegration (black dot row), axon reveal swelling and vacuolated (black short row) with multifocal infiltration of mononuclear cells (head row) (20X H & E).

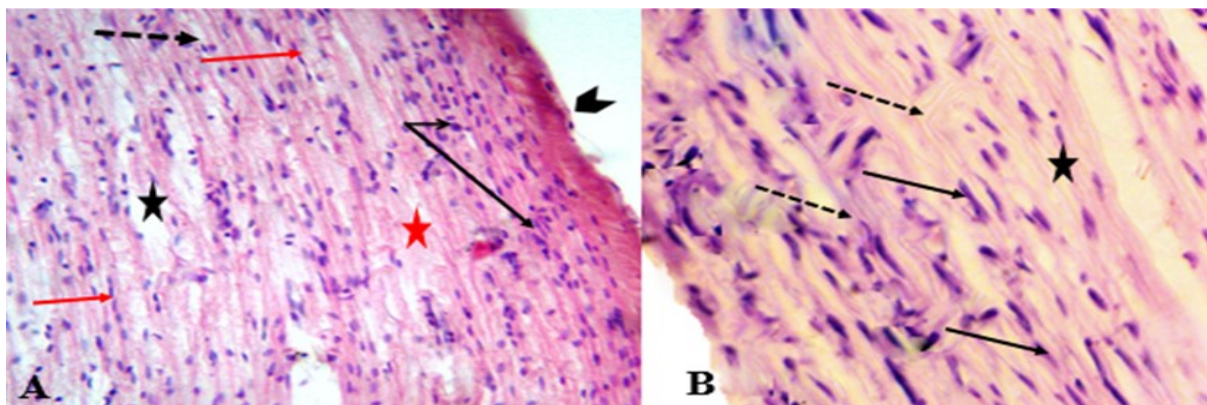


Fig. 3. Light micrographs of sciatic nerve at 16 weeks PO A: control group: showing moderate schwann cells proliferation arranged along nerve fiber (red row), a moderate nerve fiber myelination (red star), mild nerve fiber demyelination (black star), axonal vacuolated (black dot row) and infiltration of mononuclear cells (black row) with epineurium (black head row), B: treated group showing mild Schwann cells proliferation forming nendoneurial tube (black row), eosinophilic thick bundles packed contentious nerve fibers (black star) with consertraction of neuilemma – nodes Ranvier (black dot row) (40x H & E)

Discussion

Motor Clinical Observations

The animals' gait returned to normal in all groups, although they did so more quickly in the treatment groups (40 days) and (56 days) than in the control group (77 days). Knuckling disappeared in the treated groups after 57 and 58 days, with a significant difference ($p \leq 0.05$), but it persisted in the control group until the end of the study. All groups had substantial muscle contraction forces, although in the treatment (43 days) and (47 days) groups, contraction began earlier than in the control group (48 days).

Clinically, degeneration acts as impaired supplementation, leading to the electrophysiological

recovery of sensory conduction and evoked potentials [14].

This study showed that regression of knuckling severity did not last in the treated group on day 57 but persisted in the control group until the end of the study on day 112 PO. This interesting result on walking improvement in all animals in the treated group could be due to the role played by zinc oxide nanoparticles, which had an impact on blood supply and reduced functional recovery and innervation of the injured sciatic nerve. Comparing animals in the control group to those in the treated groups, the current study found that the damaged sciatic nerve in the Treated group quickly recovered its functional state. Zinc oxide nanoparticles are thought to damage peripheral nerve injury in two different ways. In order to reduce fill endoneurial sheaths and prevent

the formation of longitudinal columns, also known as bands of Bungner, zinc oxide nanoparticles were thought to act on Schwann cell proliferation through inhibiting neuronal cell production and directional axonal growth [15]. Because zinc oxide nanoparticles promote the differentiation and proliferation of Schwann cells, the levels of nerve growth factor (NGF), neurotrophic factors, cytokines, and other substances had been raised. The latter is crucial in reducing Schwann cell migration and adherence to axonal projections and encouraging neuronal death in diminished response to damage [16].

It is important to notice from the current research that, in comparison to the control groups, the muscle contraction force of the treated group of animals quickly increased. The progression of the sciatic nerve's motor function is shown by the force of muscle contraction and the atrophy of muscle mass, which are related to muscular denervation and muscle disuse. Early muscle hypertrophy and force contraction are reduced by sciatic nerve neurotmesis [17].

Sensory Clinical Observations

The current study showed that clinical signs of sensation were suggestive of sensory progression in each treatment group. The absence of sensation and the presence of knuckling, especially when it is severe and the animal walks on the dorsum of the foot, help in the development of the atrophic ulcer. Foot drop was noticeable right away after the nerve was transacted, and it frequently disappeared or lessened before the muscles were reinnervated. Observations of the gait alone are not sufficient to determine the precise commencement of the response since the symptoms of sciatic nerve injury are distinct. An reliable evaluation of the beginning and development of recovery is achieved by restricting observations to the muscle area directly innervated by the sciatic nerve. Favorable markers of the onset of motor function include movements that can be evoked by reflexes (18), who documented the healing and reflex movements in rabbits following sciatic nerve injuries, including the spreading of three toes on the hind limbs. In the midst of this action, the animals spread their toes reflexively in an attempt to enlarge the surface area of their feet for a safer landing [19,20].

Relative gastrocnemius muscle weight measurement (RGMWM)

A comparison of the relative gastrocnemius muscle weight means showed that the gastrocnemius muscle started to atrophy after sciatic nerve injury. However, on day 112 PO, the RGMW values in the control group were significantly lower ($p \leq 0.05$) than in the control groups after 16 weeks (30%) and 8 weeks (25%). Airaksinen [21] found that muscle weight regains after the reinnervation of motor target

organ and cutaneous afferents. The muscle gradually regains mass depending on the degree of reinnervation [21], which is related to the maximum force of contraction.

Gastrocnemius muscle is the immediate peripheral target organ of the sciatic nerve. Following nerve transection and treatment, measuring the relative weight of this muscle overtime gave an indicator of the sciatic nerve's capacity for regeneration. As soon as a nerve was damaged, atrophy set in, reducing the weight of the muscular target organ. When comparing groups, the treated group, followed by the control 8 week group, had the lowest relative muscle weight ratio. Confirmed regain of muscle weight when reinnervation of the motor target organ and cutaneous afferents were reestablished was reported by. The muscle gradually regains mass depending on the degree of reinnervation [21] which is related to the maximum force of contraction.

Electrophysiological analysis:

The conductive velocity at 8 weeks PO showed non-significant differences between the treated 16 and the control group showed substantial variations in the same group between the left sciatic nerve (OP) and the right sciatic nerve

The factor influencing peripheral nerve regeneration was the degree of nerve tension at the repair site. After careful alignment of both nerve stumps, single epineural sutures were applied along the circumference of the nerve. Failure to do so would lead to swelling of the nerve end brought about by postoperative edema. Additionally, the coaptation of the nerve ends must not be fixed under tension. Following sciatic nerve transection and repair, endoneurial pressure changes markedly, mainly due to impaired neuronal blood and axoplasmic flow [22]. Increased tension at the site of coaptation of the sciatic nerve is usually associated with nerve elongation and decreased blood flow. This is confirmed by Dumitrescu-Ionescu, who found that the nerve blood flow and conduction velocity might decrease when the nerve tension increases. The limitation of peripheral nerve elongation is 8-10% and the point at which blood flow decreases by 50%. Elongation of 15% leads to stagnation of endoneurial lymphatic flow, followed by increased endoneurial fluid pressure, decreased oxygenation, and cessation of axonal transport, resulting in axonal degeneration [23,24].

A study by Sonawane [25] demonstrated that full-range motion mobilization significantly impedes functional recovery due to increasing endoneurial collagenous connective tissue and decreased neural angiogenesis at the nerve suture site, which blocks the advancement of nerve neurite sprout regeneration [24]. In the present study, after neurorrhaphy, the

animals were placed in cages without immobilization of the operated limb, contrary to [25].

Sonawane [25], who recommended the duration of immobilization after reconstruction of the sciatic nerve to be from 8 days to 6 weeks, while another study [26] mentioned that the operated limb is immobilized with a splint for 2-3 weeks.

Histopathological Examination

Histopathological examination of the damaged sciatic nerve in the control and Treated groups revealed basophilic nuclei of dividing Schwann cells with a thick layer of myelin, excellent orientation, myelination of nerve fibers, and little fibrous tissue at the epineurium (Figure3).

Histopathological findings in this study showed highly vascularized injured sciatic nerves due to blood supply efficacies brought about by the presence of neurotrophic factors capable of angiogenesis through affected endothelial cells. Previous studies mentioned that nerve growth factors (NGF) is able to stimulate the migration and proliferation of endothelial cells, remodeling of the extracellular matrix, and functional maturation of newly formed blood vessels [27]. The primary supporting components that are crucial to the regeneration of peripheral nerves are Schwann cells [28]. Findings from the present study are consistent with the results of previous studies, which examined the essential roles played by Schwann cells in guiding neural outgrowth after injury in injured nerves, inhibition of Schwann cell proliferation, and reduced axon growth [27]. Experimentally, when the number of nerve cells and, consequently, the number of nerve fibers in a region of the peripheral nervous system are reduced, the number of Schwann cells populating that region is correspondingly reduced. Hence, a high concentration of Schwann cells might indicate a high number of surviving neurons [28].

The reduced angiogenic and neurotrophic factors in the above results from the histopathological findings indicated that the degeneration impaired the sensory and autonomic neurons in the dorsal root ganglia and motor neurons in the ventral horn of spinal cord regeneration which could be due to decreased neurotrophic factors that protected the neurons survival and regeneration in spite of the fact that axon regeneration was still not connected with target organs. This outcomes has been inconsistent with that of Dolan *et al.* [29], who reported that axonal injury, which disrupted the contact between cell bodies and the peripheral organ led to the death of up to 35% of the sensory neurons because of the loss of neurotrophic factors from target organs[30].

The present study showed that histopathologically, there was impairment in the control group, as evidenced by a decrease in the number of Schwann cells leading to reduced myelin

sheath. A decrease in the number of Schwann cells in the stump due to impaired remyelination of regenerated axons [30].

When a peripheral nerve is injured, an inflammatory response occurs that results in increased vascular permeability and intraneural edema [27]. The polymorphonuclear leucocytes that invade the lesion site are able to produce harmful oxygen metabolites such superoxide anion, hydrogen peroxide, and hydroxyl radicals as a result of local ischemia in the tissue. Neutrophils emit cytokines and free radicals that can cause cell damage (31,32). Through its antioxidant properties, it can indirectly aid in the decrease of oxidative stress (33). Experimental studies have shown that the induction caused by compression of neural nerve in rabbits not only increased the oxidative injury of the muscle cells but also elevated the formation of edema in these cells [34,35].

Conclusions

The conclusions drawn from this study are based on clinical, electrophysiological examinations, as follows:

1. Clinically, the clinical signs may disappear early in the treated group compared with the control group, with delayed nerve regeneration sometimes and failure at other times.
2. Motor and sensory reflexes improved earlier in the treated group compared to the control group.
3. Gastrocnemius muscle atrophy was low in the treated group compared with the control group.

Acknowledgement:

I would like to express my deepest gratitude and thankful for Al-Qasim Green University/college of Veterinary Medicine for their support and assistance in doing this the study. I would also like to express my gratitude to my colleague Dr. Adnan M. Jassm (College of Veterinary Medicine, Department of Pharmacology for his cooperation.

Conflict of Interest:

There was no conflict of interest

Funding statement:

All authors contributed equally to this work

Author`s contributions:

The current study was financially supported by own author.

References

1. Piao, Y. and Liang, X. Chinese medicine in diabetic peripheral neuropathy: experimental research on nerve repair and regeneration. *J. Evid. Based Complementary Altern. Med.*, **2012**,1-13 (2012).

2. Fu, J., Li, X., Jin, F., Dong, Y., Zhou, H., Alhaskawi, A. and Lu, H. The potential roles of dental pulp stem cells in peripheral nerve regeneration. *Frontiers in Neurol.*, **13**, 1098857(2023).
3. Maita, K. C., Garcia, J. P., Avila, F. R., Torres-Guzman, R. A., Ho, O., Chini, C. C. and Forte, A. J. Evaluation of the aging effect on peripheral nerve regeneration: a systematic review. *J. Surg. Res.*, **288**, 329-340 (2023).
4. Wang, J., Lu, S., Yuan, Y., Huang, L., Bian, M., Yu, J. and Zhang, J. Inhibition of Schwann Cell Pyroptosis Promotes Nerve Regeneration in Peripheral Nerve Injury in Rats. *Mediators of Inflammation*, **20**(23), 1-12 (2023).
5. Yousif, T. and Naje, A.N. Enhancement of Photoconductive Detector Based on Carbon Nanotubes Decorated with Silver Nanoparticles by Adding Conductive Polymer. *Iraqi J. Phys.*, **19**(50), 84-293 (2021).
6. Abbasi, B. H., Shah, M., Hashmi, S. S., Nazir, M., Naz, S., Ahmad, W., Khan, I. U. and Hano, C. Green Bio-Assisted Synthesis, Characterization And Biological Evaluation Of Biocompatible ZnO Nps Synthesized From Different Tissues Of Milk Thistle (*Silybum Marianum*). *Nanomaterials*, **9**, 1171 (2019).
7. Kadhim, H.J., Al-Mumen, H., Nahi, H.H. and Hamidi, S.M. Tunable plasmon induced transparency in one-dimensional gold nano-grating as a new kind of neuro-transmitter sensor. *Optik.*, **269**, 169907(2022).
8. Jeevanandam, J., Kiew, S. F., Boakye-Ansah, S., Lau, S. Y., Barhoum, A., Danquah, M. K. and Rodrigues, J. Green approaches for the synthesis of metal and metal oxide nanoparticles using microbial and plant extracts. *Nanoscale*, **14**(7), 2534-2571 (2022).
9. Flecknell, P. Anesthesia of rodent and rabbits. In: Veterinary anesthesia and analgesia. McKelvey, D and Hollingshead, K. 3rd ed. St. Louis, Missouri U.S.A. pp. 350-386(2003).
10. Essa, H.H., Jasim, H.S. and Kadhim, H.A. Immunological and Hematological Response to Local Transplantation of Stem Cells in Injured Radial Nerve of Dogs. *Iraqi J. Vet. Med.*, **44** (2), 45-55(2020).
11. Jasim, A. M., Hasan, H. F. and Awady, M. J. Preparation of Voropaxar loaded with Vitamin E TPGS and PVA emulsified PLGA nanoparticles In vitro studies. *Research Journal of Pharmacy and Technology*, **12**, 4503-4510 (2019).
12. Schmidhammer, R., Zandieh, S., Hopf, R., Mizner, I., Pelinka, L.E., Kroepfl, A. and Redl, H. Alleviated tension at the repair site enhances functional regeneration: the effect of full range of motion mobilization on the regeneration of peripheral nerves: histologic, electrophysiologic, and functional results in a rat model. *Journal of Trauma*, **56**, 571-584(2004).
13. Abd Al-Maseeh, Z.T. and Eesa, M.J. Comparative study of three methods of esophageal anastomosis in dogs. *Iraqi J Vet Sci.*, **23**(2), 45-50(2009).
14. Khaleel, I.M. and Baker, A.R. Anatomical and Histomorphological Study of the Trachea and Lung in Indigenous Guinea Pigs (*Caviaporcellus*). *Inter. J Vet. Sci.*, **7**(4), 210-215(2018).
15. Tiwari, V., Kuhad, A. and Chopra K. Tocotrienol ameliorates behavioral and biochemical alterations in the rat model of alcoholic neuropathy. *Pain*, **145**, 129-135(2009).
16. Mutschler, C., Fazal, S. V., Schumacher, N., Loreto, A., Coleman, M. P. and Arthur-Farraj, P. Schwann cells are axo-protective after injury irrespective of myelination status in mouse Schwann cell–neuron cocultures. *Journal of Cell Sci.*, **136**(18), 26-155 (2023).
17. Boyd, J.G. and Gordon, T. Neurotrophic factors and their receptors in axonal regeneration and functional recovery after peripheral nerve injury. *Mol Neurobiol.*, **27**, 277-323(2003).
18. Burnett, M. and Zager, E. Pathophysiology of peripheral nerve injury: a brief review. *Neurosurg Focus*, **16**, 1-7 (2004).
19. Sarikcioglu, L., Demirel, B.M. and Utuk, A. Walking track analysis: an assessment method for functional recovery after sciatic nerve injury in the rat. *Folia Morphol.*, **68**, 1-7(2008).
20. Langley, B. and Ratan, R.R. Oxidative stress-induced death in the nervous system: cell cycle dependent or independent. *J. Neurosci. Res.*, **77**, 621-629(2004).
21. Airaksinen, G.R., Masu, Y., Helbig, C., Wolf, E., Brem, G., Toyka, K.V., Thoenen, H. Meyer, M. M.S. and Koltzenburg, M. Lewin Specific subtypes of cutaneous mechanoreceptors require neurotrophin-3 following peripheral target innervation. *Neuron*, **16**, 287-295(1996).
22. Bertelli, J.A. and Mira, J.C. The grasping test: a simple behavioral method for objective quantitative assessment of peripheral nerve regeneration in the rat. *J. Neurosci. Methods*, **58**, 151-155(1995).
23. Al-Faris, A. A., Sawad, A. A. and Zebon, S. H. Radiological and histopathological study of diabetes mellitus effect on bone healing in late stages in dogs. *Int. J. Sci. Technol. Res.*, **143**(2492), 1-8(2015).
24. Zhang, Y., Zhao, Q., Chen, Q., Xu, L. and Yi, S. Transcriptional control of peripheral nerve regeneration. *Molecular Neurobiology*, **60**(1), 329-341(2023).
25. Sonawane, K., Dixit, H., Thota, N., Mistry, T., Balavenkatasubramanian, J. and Thota, N. R. Knowing It Before Blocking It, the ABCD of the Peripheral Nerves: Part B (Nerve Injury Types, Mechanisms, and Pathogenesis). *Cureus*, **15**(8), 222-245(2023).
26. Solomevich, S. O., Oranges, C. M., Kalbermatten, D. F., Schwendeman, A. and Madduri, S. Natural polysaccharides and their derivatives as potential medical materials and drug delivery systems for the treatment of peripheral nerve injuries. *Carbohydrate Polymers*, **12**(9)34-37 (2023).

27. Lin, J. S. and Jain, S. A. Challenges in nerve repair and reconstruction. *Hand Clinics*, **39**(3), 403-415(2023).
28. Chen, R. N., Ho, H. O., Tsai, Y. T. and Sheu, M. T. Process development of an acellular dermal matrix (ADM) for biomedical applications. *Biomaterials*, **25**(13), 2679-2686(2004).
29. Dolan, C. P., Yan, M., Zimmel, K., Yang, T. J., Leininger, E., Dawson, L. A. and Muneoka, K. Axonal regrowth is impaired during digit tip regeneration in mice. *Dev. Biol.*, **445**(2), 237-244(2019).
30. Jessen, K. R. and Mirsky, R. The Success and Failure of the Schwann Cell Response to Nerve Injury. *Front. cell Neurosci.*, **13**, 33(2019).
31. Yang, Q., Su, S., Liu, S., Yang, S., Xu, J., Zhong, Y. and Liang, F. Exosomes-loaded electroconductive nerve dressing for nerve regeneration and pain relief against diabetic peripheral nerve injury. *Bioactive Materials*, **26**, 194-215(2023).
32. Kurtoglu, Z., Ozturk, A.H., Bagdatoglu, C, Turac, A., Camdeviren, H., Uzmsansel , D. and Aktekin, M. Effects of trapedil on the sciatic nerve with crush injury: a light microscopic study. *Neuroanat.*, **3**, 54-58(2004).
33. Aydemir, O., Celebi, S., Yilmaz, T., Yekeler, H. and Kukner, A.S. Protective effects of vitamin E forms (alphatocopherol, gamma-tocopherol and d-alpha-tocopherol polyethylene glycol 1000 succinate) on retinal edema during ischemia-reperfusion injury in the guinea pig retina. *Int. Ophthalmol.*, **25**, 283-289(2004).
34. Silva, M.G., Castro, A.A., Ramos, E.A.G., Peixoto, E., Miranda, F., Pitta, G.B.B., Costa, R.F.B. and Juliano, Y. Histological and biochemical serum effects of alpha-tocopherol on ischemia/reperfusion-related injuries induced in the pelvic limb of the rat. *Acta Cir. Bras.*, **20**, 375-381(2005).
35. Al-Timmemi, H.A., Ibrahim, R., Zuki, A.Z. and Azmi, T.I. Bone marrow stromal cells implantation and suture repair of peripheral nerve: a comparative study of functional, hispathological, morphometric and relative gastrocnemius muscle weight in rabbits. *Afr. J. Bio.*, **10**, 8976-8983(2012).

دراسة تأثير جزيئات أكسيد الزنك النانوية على تجديد العصب الوركي التالف في نموذج الارانب

¹حسين هادي ناھي ، ²منتظر سلمان عاشور و ³عمر عادل بدر

¹قسم الجراحة والتوليد - كلية الطب البيطري - جامعة القاسم الخضراء - بابل - العراق.

²قسم الاحياء - كلية التربية للعلوم الصرفة ابن الهيثم - جامعة بغداد - بغداد - العراق.

³قسم الجراحة وعلم تناسل الحيوان - كلية الطب البيطري - جامعة الموصل - الموصل - العراق.

أجريت هذه الدراسة على 20 أرنباً قسمت إلى مجموعتي السيطرة والعلاج (8 و 16 أسبوعاً) لكل مجموعة. تم خدرت الحيوانات ثم سحق العصب الوركي اليسار لمدة 30 ثانية باستخدام ملقط الشريان. تم استخدام جزيئات أكسيد الزنك النانوية في مجموعات العلاج مع المراقبة اليومية لمدة 56 يوماً. لوحظ تحسن المشي واختفاء العرج في اليومين 20 و 28 بعد العملية الجراحية. وكان تقلص العضلات قوي مع ضمور متوسط عند اليوم 56 بعد العملية، بينما ينت حيوانات مجموعة العلاج استجابات حسية ملحوظة ($P \leq 0.05$). في المجموعة المعالجة وكانت أعلى نسبة لقياس وزن عضلة الساق النسبي (0.74) و (0.71) في الأسبوعين 16 و 8 على التوالي، و (0.54) في المجموعة سيطرة في اليوم 112 بعد العملية. في اليوم 56 بعد العملية لم يكن هناك انخفاض معنوي في قيم نسبة وزن العضلة في مجموعة السيطرة (30 و 25)٪ عند الأسبوعين 16 و 8 على التوالي و 25٪ في مجموعة العلاج. أظهرت سرعة التوصيل عند الأسبوع الثامن بعد العملية فروقاً غير معنوية بين جميع المجموعات، كانت قيمة المدى لمجموعة العلاج 3 مللي ثانية و 4 مللي ثانية في الطرف الأيسر والأيمن على التوالي عند الأسبوع الثامن بعد العملية، وكانت قيم السعة في الأطراف اليسرى واليمنى في كل من مجموعة العلاج ومجموعة السيطرة (3.5 و 6.9) و (2.83) و (5.2) ملفولط على التوالي. أظهرت الفحوصات النسجية أفضلية في جودة وكمية التكوين الليفية العصبي في مجموعة العلاج في فترة 16 أسبوع بعد العملية. وبهذا نؤكد بان اوكسيد الزنك النانوي عامل حيوي و اساسي لتسريع تجديد الأعصاب.

الكلمات الدالة: العصب الوركي، جزيئات أكسيد الزنك النانوية، التجديد.