

# CAN HYALURONIC ACID GEL ENHANCE WOUND HEALING FASTER THAN ADVANCED PLATELETS RICH FIBRIN FOLLOWING SURGICAL REMOVAL OF IMPACTED MANDIBULAR THIRD MOLARS? A RANDOMIZED CONTROLLED TRIAL

Document Type : Original Article, Doi: <https://doi.org/10.33762/bsurg.2023.141332.1055>

[Thoufokar Shokor Alsaadi](#) <sup>1</sup> [Ahmed Fadhel Al-Quisi](#) <sup>2</sup>

<sup>1</sup> University of Baghdad / college of dentistry

<sup>2</sup> Oral and Maxillofacial Surgery Department, College of Dentistry, University of Baghdad, Iraq.  
Oral and Maxillofacial Surgeon at Al-Kindy Teaching Hospital, Baghdad, Iraq.

Corresponding Author: Thoufokar Shokor Al-Saadi

E-Mail: [thoufokarsh@gmail.com](mailto:thoufokarsh@gmail.com)

Article ID: BSURG-2306-1055

Receive Date: 28 June 2023

Revise Date: 28 August 2023

Accept Date: 27 September 2023

Publish Date: 30 December 2023

## Abstract

**The aim of this study:** To assess the efficacy of advanced platelet-rich fibrin (A-PRF) and 1% hyaluronic acid gel (HA ) as a regenerative biomaterial for wound healing after impacted third molar extractions.

**Materials and methods:** This study was a randomized controlled trial carried out in the oral surgery unit of the dental teaching hospital. Furthermore, the participants were randomly assigned into three different groups. The patient's surgical site was left without adding any material in group A. While in group B (study group), the patient's surgical site was treated by applying a mixture of 1 cc HA gel with a one gel foam sponge. In group C (study group), the surgical site was treated by placing an A-PRF clot inside the surgical site. The first follow-up visit was 24 hours after the surgery to assess the soft tissue healing, with subsequent assessment visits on the third and seventh postoperative days.

**Results:** Hyaluronic acid and A-PRF groups, when compared with the control group, showed significant improvement in early wound healing scores. However, the A-PRF group had a statistically significant improvement over the hyaluronic acid group only during the first and third postoperative days.

**Conclusion:** Hyaluronic acid gel and A-PRF effectively enhanced early soft tissue healing following the surgical removal of the impacted lower third molar. with the upper hand for the A-PRF in the 1st and the 3rd postoperative days disappears in the 7th day.

Thus, the ease of availability of the Hyaluronic acid gel makes it an attractive alternative to the A-PRF.

**Keywords:** Early wound healing score, Hyaluronic acid, Platelet-rich fibrin, Third molar.

## Introduction

**P**artially or Completely impacted third molars are related to various complications, such as pericoronitis, pain, trismus, abscesses, cysts, and arch crowding. As a result, impacted third molars, whether symptomatic or asymptomatic, are commonly extracted to avoid the previously mentioned clinical problems. However, several postoperative complications, including discomfort, edema, alveolar osteitis, trismus, and infection linked to the surgical removal of these teeth<sup>1</sup>.

Platelet-rich fibrin (PRF), the second generation of platelet concentrates, has a large amount of growth factors that aid in wound healing<sup>2</sup>. Choukroun et al. described PRF as a second-generation platelet concentrate obtained by a simplified processing technique<sup>3</sup>.

Choukroun recently developed A-PRF, a modified variation of PRF. Compared to PRF, A-PRF clots are softer and include a significantly higher amount of autologous cells, including neutrophils and macrophages, and have been used to aid in wound healing and bone generation<sup>4&5</sup>.

Lowering the centrifugation speed promotes the formation of fibrin net persistence, this is related with more efficient cells and cytokines throughout centrifugation and

influences the gradual release of the hosted growth factors<sup>6&7</sup>.

The platelet-rich plasma had a poor ability to achieve sustained release of its growth factors after preparation. On the other hand, A-PRF could release growth factors over one to four weeks, ensuring healing stimulation lasts longer. Furthermore, A-PRF promotes healing, stimulates angiogenesis, and reduces the recipient site's inflammation risk. It lessens the severity of postoperative complications<sup>8</sup>.

Regarding hyaluronic acid (HA), numerous studies have shown that it is an excellent choice for enhancing wound healing by encouraging the development of granulation tissue, preventing harmful inflammation, and promoting re-epithelialization and angiogenesis<sup>9</sup>.

Hyaluronic acid is a naturally-derived polymer biomaterial. It is a vital component of the extracellular matrix (ECM) and may be found in all mammalian tissues and fluids<sup>10</sup>. It regulates chemotaxis, proliferation, and mesenchymal cell differentiation and hence plays an essential role in the regeneration and repair of tissue<sup>11</sup>.

However, evidence comparing the beneficial effects of A-PRF and HA gel in soft tissue wound healing is currently limited. A correctly designed randomized clinical trial is

needed to compare their benefits after surgical extraction of impacted lower wisdom teeth. As a result, the current study aims to assess and compare their effects on early wound healing following surgical extraction of the impacted wisdom teeth.

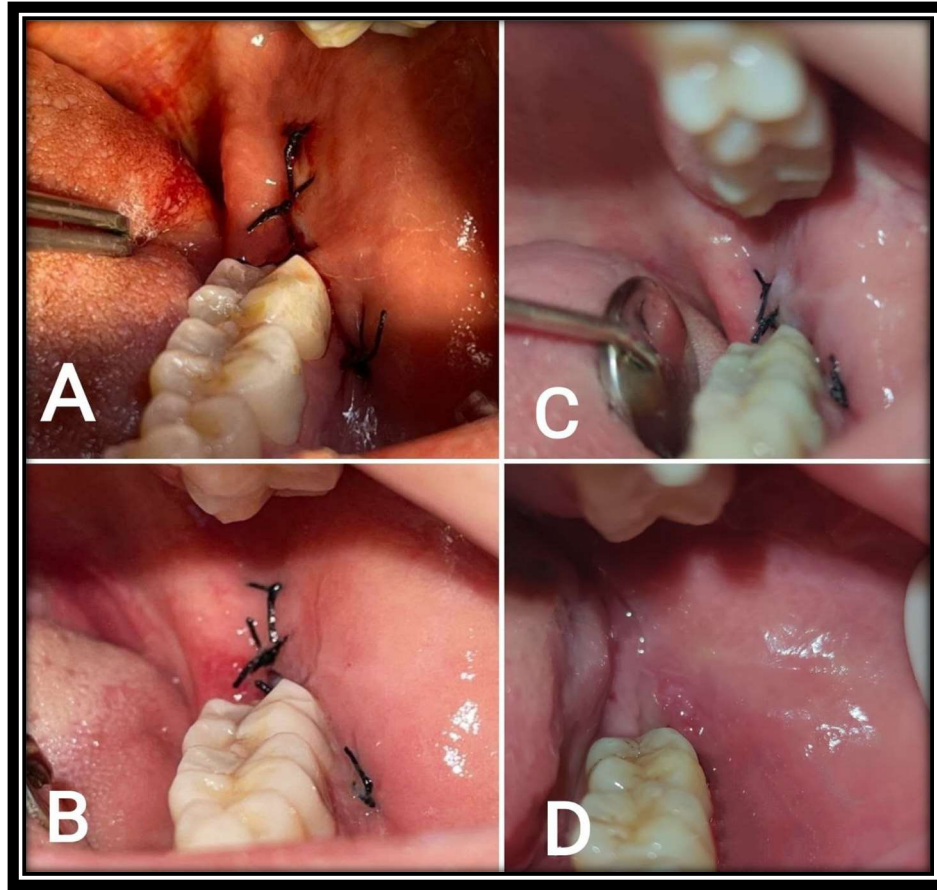
## 2. Patients and Methods

This study was a randomized control trial, and it was carried out in the dental teaching hospital's oral surgery unit under the Declaration of Helsinki and its subsequent amendments. The Thai Clinical Trial Registry (TCTR) assigned this study registration number 20220602008.

Any healthy nonsmoker patient with mesioangular and horizontal impacted mandibular third molar teeth according to the winter classification and degrees of impaction according to the Pell and Gregory category (level A or B, class I or II) were included in this study and randomly assigned into one of the three groups by using Microsoft Excel 2013 block randomization to assure that the number of patients in each group was equal. In group A (control group), patient's surgical site was left without adding

any material. While in group B (study group), the patient's surgical site was treated by applying one cc of HA gel (periokin) mixed with one gel foam sponge. In group C (study group), the surgical site was treated by placing an A-PRF clot inside the surgical site. G-power software was used to calculate the sample size for this study. An independent Maxillofacial Surgeon assessed pain, edema, and trismus, and he was blinded to the type of material utilized during the surgery.

The first follow-up visit was 24 hours after the surgery to assess the soft tissue healing according to the early wound healing score (EHS)<sup>12</sup>, with subsequent assessment visits on the 3rd and 7th postoperative days. The EHS is composed of three elements: clinical signs of re-epithelialization (CSR), clinical signs of hemostasis (CSH), and clinical signs of inflammation (CSI). In the case of suppuration, the EHS received a score of 0, regardless of the ratings for the 3 single parameters. The EHS for optimal wound healing was 10 score, and the worst possible score was 0 score points .as shown in **Fig (1)**.



**Figure (1):** Intraoral views after the surgical removal of the impacted lower wisdom tooth (A) Immediately after suturing (B) 1-day post-operative show 7 points of EHS (3 CSR, 2 CSH, and 2 CSI) (C) 3-day post-operative show 9 points of EHS (6 CSR, 1CSH and 2 CSI) (D) 7-day post-operative show 10 points of EHS (6 CSR, 2 CSH and 2 CSI)

The first follow-up visit was 24 hours after the surgery to assess the soft tissue healing, with subsequent assessment visits on the third and seventh postoperative days.

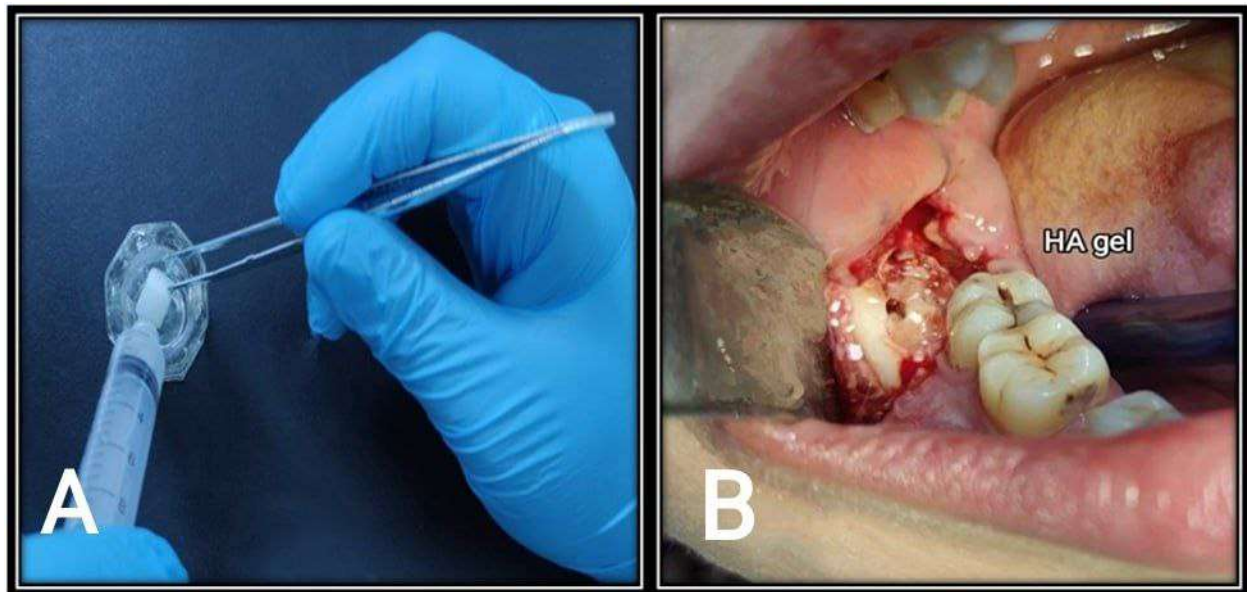
The surgical procedure started with a triangular-shaped incision followed by a full-thickness mucoperiosteal flap reflection. The osteotomy was performed using a round bur set on a low-speed surgical handpiece. After the wisdom tooth extraction, The patient's

surgical site was left without adding any material in group A. While in group B (study group), the patient's surgical site was treated by applying a mixture of 1 cc HA gel with a one gel foam sponge, as seen in Fig (2). In group C (study group), the surgical site was treated by placing an A-PRF clot inside the surgical site Fig (3) . Moreover, A-PRF was prepared by drawing 10 milliliters of the patient's venous blood from the median

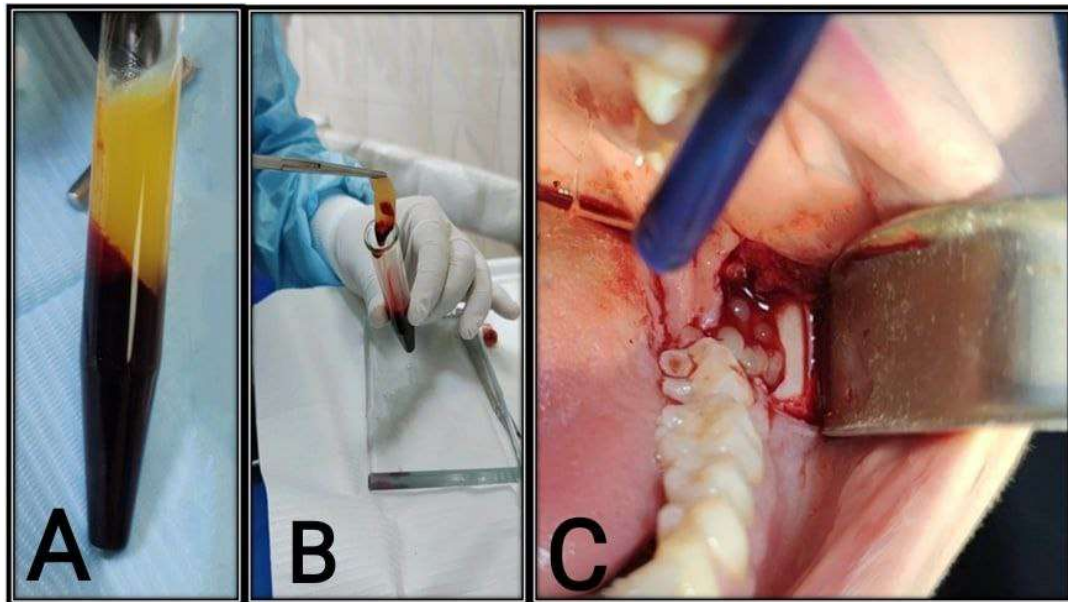
cubital vein into dry, anticoagulant-free, glass-coated plastic tubes for 14 minutes at 1500 rpm<sup>13</sup>. all wounds are then sutured with simple interrupted sutures.

The Statistical Package for Social Science software (SPSS version 21) was used in this study. The Shapiro-Wilk test assessed the

normality of the distribution of the study's data. The Chi-square test was used to test the association between two qualitative variables. In contrast, the Kruskal-Wallis test and Dunn Bonferroni Method were used to measure the difference in mean rank of the EHS between the groups.



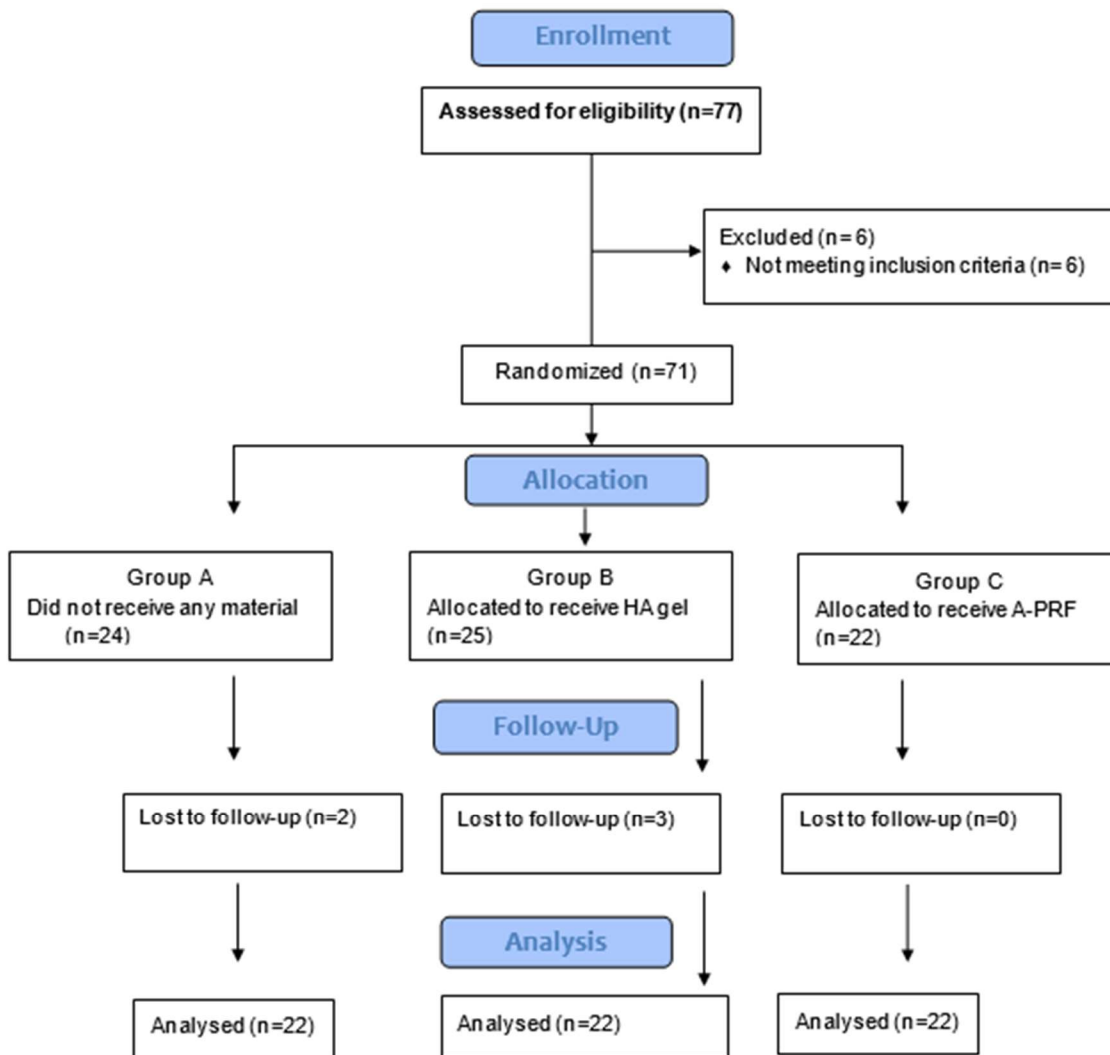
**Figure (2):** Hyaluronic acid gel mixed with the gel foam (A) one cc of the gel (periokin® )mixed with one gel foam sponge (Spongostan®, Denmark) by using dental tweezer (B) Insertion of the mixture by dental tweezer into the socket.



**Figure (3):** (A) A-PRF tube obtained after centrifugation of 10 ml of the blood from the patient, the yellowish layer represents A-PRF and the dark layer at the bottom represent red blood cell (B) A-PRF separated from the red blood cell (C) Insertion of A-PRF into the surgical socket.

## Results

This study included 77 patients, and only 66 of whom fit the eligibility criteria underwent surgical removal of impacted lower wisdom teeth and were randomly assigned into the three different groups as seen in **Fig (4)**



**Figure (4):** The flow chart illustrating the basic steps of the study

A total of 37 females and 29 males with a range of age from 18 to 29 years were included in this study; statistical analysis showed no significant differences regarding the age, gender, angle, and side of an impaction among groups, as seen in Table I

**Table I: A detailed demographic characteristic for all groups**

Vars.		Groups						Chi-square	P value
		Control		HA		A-PRF			
		Mean= 23.3 SD= ±3.5		Mean=23.05 SD= ±2.9		Mean= 22.9 SD= ±2.9			
		N	%	N	%	N	%		
Age (years)	18-23	11	16.66	12	18.18	13	19.69	0.121	0.941
	24-29	11	16.66	10	15.15	9	13.65		
Gender	Female	10	15.15	14	21.21	13	19.69	1.599	0.449
	Male	12	18.18	8	12.12	9	13.65		
Side of impaction	Left	11	50.00	10	45.45	10	45.45	0.122	0.941
	Right	11	50.00	12	54.55	12	54.55		
Winter Classification	Horizontal	13	59.09	10	45.45	12	54.55	0.852	0.653
	Mesio angular	9	40.91	12	54.55	10	45.45		
Pell and Gregory Classification	Class 1 Level A	4	18.18	5	22.73	5	22.73	0.756	0.993
	Class 1 Level B	4	18.18	5	22.73	5	22.73		
	Class 2 Level B	7	31.82	7	31.82	7	31.82		
	Class 2 Level A	7	31.82	5	22.73	5	22.73		

On the other hand, Kruskal –Wallis test showed a significant increase in EHS score in the A-PRF group on the postoperative days, followed by the Hyaluronic acid group, and the least increase was found in the Control group, as shown in Table II



**Table II: Descriptive and statistical test of EHS among groups during the postoperative days by using Kruskal –Wallis test.**

Vars.	Groups													
	Control				HA				A-PRF				KW	p
	Min.	Max.	Median	MR <sup>2</sup>	Min.	Max	Media n	MR <sup>2</sup>	Mi n.	Ma x.	Median	MR <sup>2</sup>		
<b>1-day</b>	0	5	2	19.27	0	6	5	31.11	3	7	6	50.11	30.12	<b>0.00**</b>
<b>3-day</b>	2	5	5	15.32	3	10	6	35.20	6	10	10	49.98	37.96	<b>0.00**</b>
<b>7-day</b>	4	9	5	18.41	4	10	9	36.05	7	10	10	46.05	25.04	<b>0.00**</b>

KW=Kruskal-Wallis, MR2= mean rank among the groups, \*\*highly significant

While Multiple pairwise (Dunn-Bonferroni method) showed significant differences between every two groups through all postoperative days except between A-PRF and HA groups on the 7 postoperative day, as seen in Table III.

**Table III: Comparisons of EHS between every two groups by using the Dunn-Bonferroni method.**

Period	EHS
<b>First postoperative day</b>	<b>HA-Control=0.037*</b>
	<b>A-PRF-Control=0.000**</b>
	<b>A-PRF-HA=0.002**</b>
<b>Third postoperative day</b>	<b>HA-Control=0.000**</b>
	<b>A-PRF-Control=0.000**</b>
	<b>A-PRF-HA=0.027*</b>
<b>Seventh postoperative day</b>	<b>HA-Control=0.005**</b>
	<b>A-PRF-Control=0.000**</b>
	<b>A-PRF-HA=0.221</b>

\* Significant, \*\*highly significant

## Discussion

The Early Wound Healing Score (EHS) was used to measure soft tissue wound healing in the three groups on the 1st, 3rd, and 7th postoperative days following surgical removal of the impacted lower wisdom tooth. Marini et al.<sup>12</sup> employed this scoring system in a recent study to accurately assess the early wound healing of periodontal soft tissues by primary intention.

No previous study has compared the beneficial effects of the A-PRF and 1% HA gel on incisional wound healing utilizing EHS after surgical removal of an impacted lower wisdom tooth.

This study found a statistically significant improvement in the EHS score in the A-PRF group, followed by the HA group on the 1, 3, and 7 postoperative days compared with the Control group. This efficacy of HA could be attributed to two critical factors; first, it provides a temporary framework during the healing process. Second, and possibly most essential, it promotes cell proliferation and migration, promoting oral wound healing and increasing leukocyte diapedesis and fibroblast proliferation<sup>14</sup>. A-PRF efficacy in enhancing early wound healing could be attributed to the release of large amounts of

growth factors; these factors are chemotactic towards various cell types, including monocytes, fibroblasts, endothelial cells, stem cells, and fibroblasts, influencing progenitor cell proliferation and differentiation<sup>15&16</sup>.

This study contradicts the findings of Aebli et al.<sup>17</sup>, who found that HA did not affect wound healing or repair capability, as well as Pereira et al.<sup>18</sup>, who found that the application of A-PRF does not affect the repair of lower third molar post-extraction sockets and these results can be related to the limited sample size employed in these research.

Furthermore, the results showed that the A-PRF group had a statistically significant improvement over the hyaluronic acid group only during the first and third postoperative days, with no significant difference on the seventh postoperative day; this could be attributed to the fact that the HA gel prolongs the bleeding time between periods of (2-3 days) after extraction of impacted lower wisdom tooth removal as high concentrations of HA inhibit platelet aggregation and adhesion<sup>14</sup>, and this may affect on the EHS scores in the early postoperative day. Despite these early results, on the 7th day, no

significant difference between A-PRF and HA was noted.

In Conclusion, Hyaluronic acid gel and A-PRF effectively enhanced early soft tissue healing following the surgical removal of the impacted lower third molar. with the upper

hand for the A-PRF in the 1st and the 3rd postoperative days disappears in the 7th day.

Thus, the ease of availability of the Hyaluronic acid gel makes it an attractive alternative to the A-PRF.

## Reference:

1. He Y, Chen J, Huang Y, Pan Q, Nie M. Local application of platelet-rich fibrin during lower third molar extraction improves treatment outcomes. *Journal of Oral and Maxillofacial Surgery*. 2017; 75(12):2497-2506. <https://doi.org/10.1016/j.joms.2017.05.034>
2. Bao M, Du G, Zhang Y, Ma P, Cao Y, Li C. Application of platelet-rich fibrin derivatives for mandibular third molar extraction related post-operative sequelae: a systematic review and network meta-analysis. *Journal of Oral and Maxillofacial Surgery*. 2021; 79(12):2421-2432. <https://doi.org/10.1016/j.joms.2021.07.006>
3. Choukroun J, Adda F, Schoeffler C, Vervelle A. Une opportunité en paro-implantologie: le PRF. *Implantodontie*. 2001; 42(55):e62.-
4. AL-SAADY, T. S. & AL-QUISI, A. F. 2023. The Influence of the Hyaluronic Acid Gel on the Postoperative Sequelae following Surgical Removal of the Impacted Mandibular Third Molar in Comparison with the A-PRF: A Randomized Controlled Trial. *International Journal of Biomaterials*, 2023. <https://doi.org/10.1155/2023/1883460>
5. Al-Mahdi AH, Abdulrahman MS, Al-Jumaily HAH. Evaluation of the effectiveness of using platelet rich fibrin (PRF) with bone graft in the reconstruction of alveolar cleft, a prospective study. *Journal of Craniofacial Surgery*. 2021; 32(6):2139-2143. <https://doi.org/10.1097/SCS.00000000000007486>
6. STARZYŃSKA, Anna, et al. The Growth Factors in Advanced Platelet-Rich Fibrin (A-PRF) Reduce Postoperative Complications after Mandibular Third Molar Odontectomy. *International Journal of Environmental Research and Public Health*, 2021, 18.24: 13343. <https://doi.org/10.3390/ijerph182413343>
7. Choukroun J, Diss A, Simonpieri A, Girard M-O, Schoeffler C, Dohan SL, et al. Platelet-rich fibrin (PRF): a second-generation platelet concentrate. Part V: histologic evaluations of PRF effects on bone allograft maturation in sinus lift. *Oral Surgery, Oral Medicine, Oral Pathology, Oral Radiology, and Endodontology*. 2006; 101(3):299-303. <https://doi.org/10.1016/j.tripleo.2005.07.012>
8. Brancaccio Y, Antonelli A, Barone S, Bennardo F, Fortunato L, Giudice A. Evaluation of local hemostatic efficacy after dental extractions in patients taking antiplatelet drugs: A randomized clinical trial. *Clinical Oral Investigations*. 2021; 25:1159-1167. <https://doi.org/10.1007/s00784-020-03420-3>

Alsaadi, T., Al-Quisi, A. Can Hyaluronic acid gel enhance wound healing faster than Advanced Platelets Rich Fibrin following surgical removal of impacted mandibular third molars? A Randomized Controlled Trial. *Basrah Journal of Surgery*, 2023; 29(2): 12-24. doi: 10.33762/bsurg.2023.141332.1055

9. Koray M, Ofluoglu D, Onal E, Ozgul M, Ersev H, Yaltirik M, et al. Efficacy of hyaluronic acid spray on swelling, pain, and trismus after surgical extraction of impacted mandibular third molars. *International journal of oral and maxillofacial surgery*. 2014; 43(11):1399-1403. <https://doi.org/10.1016/j.ijom.2014.05.003>-

10. Radhi IH, Al-Ghaban NM. Evaluation the effect of hyaluronic acid on bone healing process in rabbits (Immunohistochemical study for TGF- $\beta$ ). *Journal of baghdad college of dentistry*. 2015; 27(1):111-116. <https://doi.org/10.12816/0015030>-

11. Mohammad MH, Al-Ghaban NM. Histological and histomorphometric studies of the effects of hyaluronic acid on osseointegration of titanium implant in rabbits. *Journal of baghdad college of dentistry*. 2018; 30(2):10-6. <https://doi.org/10.12816/0049745>-

12. MARINI, Lorenzo, et al. Early Wound Healing Score: a system to evaluate the early healing of periodontal soft tissue wounds. *Journal of Periodontal & Implant Science*, 2018, 48.5: 274-283. <https://doi.org/10.5051/jpis.2018.48.5.274>-

13. Shah R, Thomas R, Mehta D. An Update on the Protocols and Biologic Actions of Platelet Rich Fibrin in Dentistry. *The European journal of prosthodontics and restorative dentistry*. 2017; 25(2):64-72. .-

14. GOCMEN, G., AKTOP, S., TUZUNER, B., GOKER, B. & YARAT, A. 2017. Effects of hyaluronic acid on bleeding following third molar extraction. *Journal of Applied Oral Science*, 25, 211-216. <https://doi.org/10.1590/1678-77572015-0187>-

15. CLARK, D., RAJENDRAN, Y., PAYDAR, S., HO, S., COX, D., RYDER, M., DOLLARD, J. & KAO, R. T. 2018. Advanced platelet-rich fibrin and freeze-dried bone allograft for ridge preservation: a randomized controlled clinical trial. *Journal of periodontology*, 89, 379-387. <https://doi.org/10.1002/JPER.17-0466>-

16. MIRON, R. J., FUJIOKA-KOBAYASHI, M., BISHARA, M., ZHANG, Y., HERNANDEZ, M. & CHOUKROUN, J. 2017. Platelet-rich fibrin and soft tissue wound healing: a systematic review. *Tissue Engineering Part B: Reviews*, 23, 83-99. <https://doi.org/10.1089/ten.teb.2016.0233>-

17. AEBLI, N., STICH, H., SCHAWALDER, P., THEIS, J. C. & KREBS, J. 2005. Effects of bone morphogenetic protein-2 and hyaluronic acid on the osseointegration of hydroxyapatite-coated implants: An experimental study in sheep. *Journal of Biomedical Materials Research Part A: An Official Journal of The Society for Biomaterials, The Japanese Society for Biomaterials, and The Australian Society for Biomaterials and the Korean Society for Biomaterials*, 73, 295-302. <https://doi.org/10.1002/jbm.a.30299>-

18. PEREIRA, D. A., MENDES, P. G. J., PRISINOTO, N. R., DE REZENDE BARBOSA, G. L., SOARES, P. B. F. & DE OLIVEIRA, G. J. P. L. 2022. Advanced platelet-rich-fibrin (A-PRF+) has no additional effect on the healing of post-extraction sockets of upper third molars. A split mouth randomized clinical trial. *Oral and Maxillofacial Surgery*, 1-9. <https://doi.org/10.1007/s10006-022-01075-w>-

---

**Acknowledgements:** None

**Funding:** None

**Conflict of interest :** Authors declare no conflict of interest

---

**Authors' Contributions:**

**1. Thoulfokar Shokor Alsaadi; 2. Ahmed Fadhel Al-Quisi**

Concept and design: 1,2

Data collection and analysis: 1

Responsibility for statistical analysis: 1,2

Writing the article: 1,2

Critical review: 1,2

Final approval of the article: 1,2

Each author believes that the manuscript represents honest work and certifies that the article is original, is not under consideration by any other journal, and has not been previously published.

**Availability of Data and Material:** The corresponding author is prompt to supply datasets generated during and/or analyzed during the current study on wise request.

---

This is an open access article under the CC BY 4.0 license: <http://creativecommons.org/licenses/by/4.0/>

---

**Cite this article:** Alsaadi, T., Al-Quisi, A. Can Hyaluronic acid gel enhance wound healing faster than Advanced Platelets Rich Fibrin following surgical removal of impacted mandibular third molars? A Randomized Controlled Trial. *Basrah Journal of Surgery*, 2023; 29(2): 12-24. doi: 10.33762/bsurg.2023.141332.1055

---