



# Prospective Descriptive Study of Radiological and Functional Outcomes of Volar Barton's Fracture Fixed by Volar Locked Plate

Haider O. Hayat Ali Al-Faily<sup>1</sup>, Hussein Ali Nasir<sup>2</sup>, Thaer Rasim Mohammed<sup>3</sup>, Mohammed Al-Edanni<sup>1\*</sup> 

<sup>1</sup>Department of Surgery, Al-Kindy College of the Medicine, University of Baghdad, Baghdad, Iraq; <sup>2</sup>Department of Surgery, Wasit Teaching Hospital, Wasit, Iraq; <sup>3</sup>Department of Surgery, Al-Yarmouk Teaching Hospital, Baghdad, Iraq

## Abstract

**Edited by:** Ksenija Bogoeva-Kostovska

**Citation:** Al-Faily HOHA, Nasir HA, Mohammed TR, Al-Edanni M. Prospective Descriptive Study of Radiological and Functional Outcomes of Volar Barton's Fracture Fixed by Volar Locked Plate. Open-Access Maced J Med Sci. 2022 Feb 21; 10(B):1271-1275. https://doi.org/10.3889/oamjms.2022.8615

**Keywords:** Volar Barton's fracture; Volar locked buttress plate; Functional and anatomical evaluation

\***Correspondence:** Mohammed Sh. Al-Edanni, Al-Kindy College of the Medicine, University of Baghdad, Baghdad, Iraq. Mobile: 009647801876946. E-mail: mohammedshihab@kmc.uobaghdad.edu.iq

**Received:** 12-Jan-2022

**Revised:** 06-Feb-2022

**Accepted:** 11-Feb-2022

**Copyright:** © 2022 Haider O. Hayat Ali Al-Faily, Hussein Ali Nasir, Thaer Rasim Mohammed, Mohammed Al-Edanni

**Funding:** This research did not receive any financial support

**Competing Interest:** The authors have declared that no competing interest exists

**Open Access:** This is an open-access article distributed under the terms of the Creative Commons Attribution-NonCommercial 4.0 International License (CC BY-NC 4.0)

**BACKGROUND:** Volar Barton's fracture is a shearing mechanism of injury that results in fracture and subluxation of distal end radius in which volar rim of the distal radius is displaced with hand and carpus. Open reduction and volar plate fixation ensure more stable change of displacement, preservation of reduction, and early mobilization.

**AIM:** This study aims to assess the functional and radiological outcome results of volar Barton's fracture treated by volar buttress plate using the demerit points system of Gartland and Werley.

**PATIENTS AND METHODS:** This study is a prospective descriptive observational study on 32 patients who were treated with ORIF by volar buttress plate for isolated volar Barton's fractures between February 2018 and June 2020 in Alkindy teaching hospital/Baghdad/Iraq. All volar Barton's fracture cases satisfying the inclusion criteria which included patient over 18 years, isolated fracture, medically fit, and <5 days old injuries, while fractures extend to radius shaft, compound fractures, and associated with other injuries were excluded from the study. All fractures are fixed by volar locked plate followed up for 12 week's duration for functional and radiological assessment using the Demerit points system of Gartland and Werley.

**RESULTS:** Most cases were in the age group below 40 years, average age 38 years (range 19–64 years), male patient was 69%, side of involvement was right wrist in 75% of cases, falling on an outstretched hand account 50%, while roads traffic accidents in 37.5%, fall from a height in 6.25%, and direct trauma in 6.25%. The final sequel of the results was average volar tilt was 11.1°, the radial shortening average was 4 mm, the radial inclination average was 19.9°, and the ulnar variance was 0.3 mm. Functional outcomes depending on Gartland and Werley's score were 50% as excellent results, 43.75% as good results, 6.25% as fair results, and no poor results in this study.

**CONCLUSIONS:** Volar locking buttress plate provides fracture stability and early mobilization, therefore, recovery of daily live activity in a short time.

## Introduction

Barton's fracture is an intra-articular distal radius fracture with subluxation or dislocation of the radiocarpal joint, two types of this fracture either dorsal or volar, the latter being more common [1].

The fractures of the distal radius regarding as the most common type of fractures in the body, accounting about 20% including the intra-articular fractures in adult patients [2], [3].

Falling on an outstretched hand and road traffic accidents are the most common causes of distal radius fractures. Distal radioulnar joint injury, radial styloid process fractures, ligaments, and soft-tissue injuries such as triangular fibrocartilage, scapholunate, and lunotriquetral ligaments are the most common associated injuries [2], [3], [4], [5].

Many classifications for lower end radius such as AO classification [3] and Fernandez classification [2] explain better the shear type of injury and treatment option.

Normal radiological parameters of the distal radius are radial height (length) 10–13 mm, radial inclination 21–25°, volar (radial) tilt 11° (range of 2–20°), and ulnar variance (–4.2–+ 2.3 mm) [6].

Several methods of management have been labeled in the literature, including POP cast after closed reduction, percutaneous pinning, external fixation, and plating using buttress plate [7], [8].

Barton's fracture required about 6 weeks to unite and wrist exercise can be started even in the absence of radiological evidence of bony union [1].

The standard method of treatment in such fractures is open reduction and volar locking compression plate [9].

Gartland and Werley's scoring system is used for wrist and hand function evaluation (Table 1) [10].

## Aim of study

This study aims to assess the outcomes of volar Barton's fracture treated by volar plating on basis

of radiological and functional outcomes using Gartland and Werley's scores.

## Patients and Methods

A prospective descriptive observational study on 32 patients was treated with ORIF by volar buttress plate for isolated volar Barton's fractures (not combined with ulnar fractures) between February 2018 and June 2020 in Al-Kindy Teaching Hospital/Baghdad/Iraq followed up for 12 week's duration for the functional and radiological assessment using Gartland and Werley's scoring system.

Informed consent for surgery followed up for a minimum period of 12 weeks.

The inclusion criteria including:

1. Isolated volar Barton's fracture
2. Age 18 years and older
3. Medically fit patients and willing for surgery, and
4. Less than 5 days old fracture.

The exclusion criteria including:

1. Medically unfit for surgery
2. Compound fractures
3. Patients associated with multiple fractures, and
4. Bilateral volar Barton's fractures.

The wrist was immobilized in below-elbow backslab during a period of patient preparation (1–2) days and elevation, the pain and inflammation were managed by analgesia and NSAIDs.

Radiographic assessments include volar tilt, radial shortening, radial inclination, ulnar variance, and joint line stepping.

PA and lateral wrist X-ray views were examined preoperatively, immediate post-operative (Figure 1), and the assessment of the radial shortening, radial inclination, volar tilt, and ulnar variance preoperatively before and after 3 months (Figures 2 and 3).

General anesthesia was used for all patients and a pneumatic tourniquet was applied in upper arm for all cases to provide bloodless field during surgery. The fracture site was exposed through distal part of volar approach of Henry. The plane between radial artery and flexor carpi radialis muscle, the pronator quadratus muscle should be elevated using an L-shaped incision. The horizontal limb is placed at the watershed line. This lies a few mm proximal to the joint line; the position of the joint line can be determined by a hypodermic needle placed in the joint.

After reduction of the fracture, position the volar plate (locked plate) under fluoroscopic guidance and insert a screw into the gliding hole first to permit proximal-distal correction. Fracture reduction was performed by a 3.5 mm T-buttress plate (locked plate), we do index and middle finger traction and wrist dorsiflexion, after successful fracture reduction, position the volar plate under fluoroscopic guidance and insert a screw into the oblong (gliding) hole first to allow proximal-distal adjustment. Use a 2.7 mm drill bit to drill into the center of the oblong hole and insert a self-tapping 3.5 mm screw. Use a 2.7 mm drill bit to drill the distal holes. Measure the holes for screw length and insert 3.5 nm locking screws. Use a screw that is 2 mm shorter than the measured length to avoid having a prominent distal screw perforate the dorsal cortex.

Once the first screw is inserted, distal traction on the fingers can be released because the fracture usually is appropriately reduced and fixed. Because of the fixed angle design, the screws may perforate into the radiocarpal joint if the plate is placed too far distally. Obtain fluoroscopic views tangential to the subchondral bone in both the coronal and sagittal planes to assess for intra-articular penetration. After placement of the distal screws, place the remaining proximal screws. Reattach the pronator quadratus with braided absorbable sutures. Median nerve not released in the surgery. Release of tourniquet, cauterization, insert Redivac drain, suturing in layers, dressing, and below-elbow backslab.

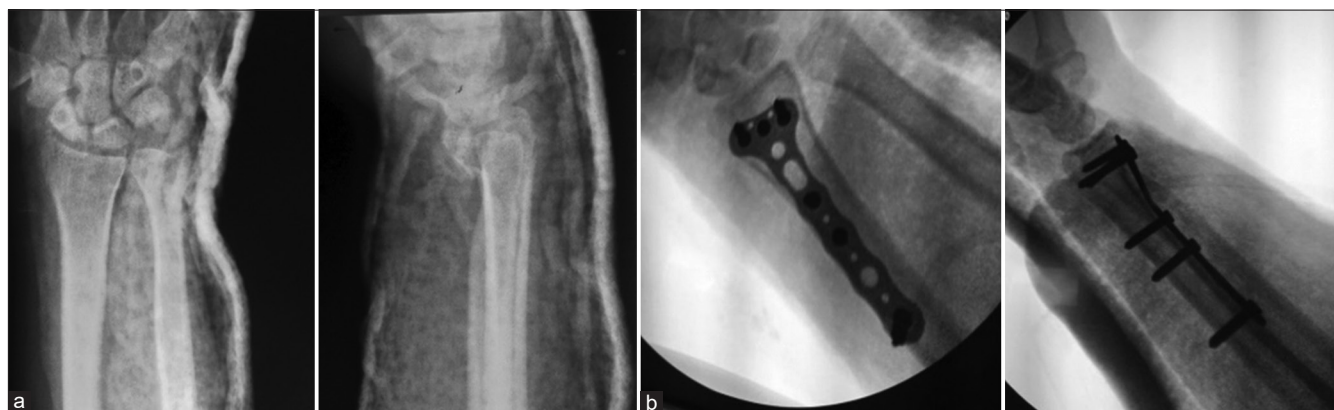

Figure 1: X-rays of the right wrist, PA view and lateral view. (a) Pre-operative and (b) post-operative

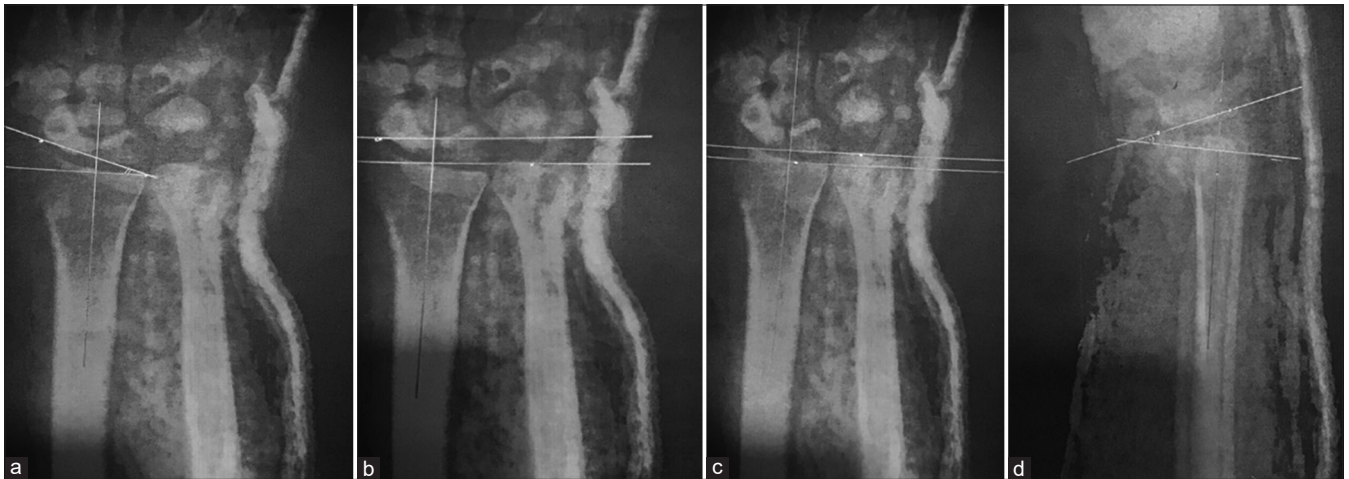

Figure 2: Pre-operative measurement. (a) Radial inclination 20°, (b) radial height 8°, (c) ulnar variance 4 mm, and (d) volar tilt 18°

Table 1: Demerit point system of Gartland and Werley [10]

Results	Point
Residual deformity (range, 0–3 points)	
Prominent ulnar styloid	1
Residual dorsal tilt	2
Radial deviation of hand	2 or 3
Subjective evaluation (range, 0–6 points)	
Excellent: No pain, disability, or limitation of motion	0
Good: Occasional pain, slight limitation of motion, and no disability	2
Fair: Occasional pain, some limitation of motion, feeling of weakness in wrist, no particular disability if careful, and activities slightly restricted	4
Poor: Pain, limitation of motion, disability, and activities more or less markedly restricted	6
Objective evaluation* (range, 0–5 points)	
Loss of extension	5
Loss of ulnar deviation	3
Loss of supination	2
Loss of flexion	1
Loss of radial deviation	1
Loss of circumduction	1
Pain in distal radioulnar joint	1
Grip strength: 60% or less than on the opposite side	1
Loss of pronation	2
Complications (range, 0–5 points)	
Arthritic change	
Minimum	1
Minimum with pain	3
Moderate	2
Moderate with pain	4
Severe	3
Severe with pain	5
Nerve complications (median)	1–3
Poor finger function due to cast	1 or 2
Final results (ranges of points)	
Excellent	0–2
Good	3–8
Fair	9–20
Poor	≥ 21

### Post-operative protocol

Post-operative pain relievers by nonsteroidal anti-inflammatory drugs and post-operative X-rays were taken (PA and lateral views). Backslab below elbow used for 10 days.

All patients were given intravenous ceftriaxone vial 1 g once daily for 3 days. The wound was inspected on the 3<sup>rd</sup> post-operative day and the Redivac drain is removed then patients were discharged. Sutures were removed on the 14<sup>th</sup> post-operative day. All patients were followed up after 3 weeks, 6 weeks, and 12 weeks.

Active fingers exercise and elbow movement are encouraged after surgery, active wrist movement for 3 weeks, active and passive movement started 6 weeks after surgery.

Outcomes were assessed at 12 weeks using the demerit points system of Gartland and Werley based on subjective and objective criteria, remaining deformity, and complications.

### Results

In this study, the majority of fractures occur in age 30–39 years old, with males predominant, more on the right side, and half of the cases are due to fall on an outstretched hand (Table 2).

Table 2: Age, sex, side of involvement, and mode of injury

Variables	No. of cases	Percentage
Age in years		
19–29	6	19
30–39	12	37.5
40–49	8	25
50–59	4	12.5
>60	2	6
Sex		
Male	22	69
Female	10	31
Side		
Right side	24	75
Left side	8	25
Mechanism of injury		
Fall on an outstretched hand	16	50
Road traffic accident	12	37.5
Fall from height	2	6.25
Direct trauma	2	6.25

The objective evaluation of wrist and forearm range of motion after 12 weeks is summarized in Table 3 with the majority with a good range of movement apart from the pain in distal radioulnar joint in 25% of cases and grip weak in 12.5%.

Table 3: Objective evaluation of wrist and forearm range of motion after 12 weeks

Movement within the normal functional range	No. of cases	Percentage
Wrist dorsiflexion (45°)	30	94
Wrist palmar flexion (30°)	32	100
Radial deviation (15°)	30	94
Ulnar deviation (15°)	32	100
Pronation (50°)	32	100
Supination (50°)	32	100
Pain in DRUJ	8	25
Grip (less than the opposite side)*	4	12.5q

\*Grip strength measured by asking the patient to squeeze a partially inflated sphygmomanometer cuff (normally, a pressure of 150 mmHg can be achieved easily) [1]

**Table 4: Radiographic evaluation**

Follow-up	Volar	Tilt	Radial	shortening	Radial	Inclination	Ulnar variance (mm)
Pre-operative	0° 2 (6.25%)	1–10° 4 (12.5%)	<6 mm 4 (12.5%)	6–10 mm 16 (50%)	10° 6 (18.75%)	11–15° 20 (62.5%)	Average (± SD) 2.8 (± 1.1)
Post-operative (day 1)	0 (0%)	12 (37.5%)	20 (62.5%)	8 (25%)	0 (0%)	6 (18.75%)	0.1 (± 1.5)
Follow-up (12 weeks)	0 (0%)	12 (37.5%)	28 (87.5%)	4 (12.5%)	0 (0%)	0 (0%)	0.3 (± 0.6)

Radiographic evaluation of pre-operative, post-operative, and final follow-up is summarized in Table 4.

The outcome results according to Gartland and Werley scores after 12 weeks show 93.7% excellent to a good result. (Table 5).

**Table 5: Outcome results of Gartland and Werley's scores after 12 weeks**

Results	No. of cases	Percentage
Excellent	16	50
Good	14	43.75
Fair	2	6.25
Poor	0	0
Total	32	100

All fractures were consolidated in a mean period of 7.6 weeks (range 6–10 weeks).

None of the cases developed non-union, wound infection, or hardware breakage.

## Discussion

The chief aim of surgical treatment of Barton's fracture is to achieve the accurate restoration of the disturbed anatomy and permit the rapid reoccurrence of hand and wrist function without problems [11], [12].

Fernandez classification was used for classification. Internal fixation of volar Barton's fracture by buttress plate (locking type) has been performed in all our cases, the incidence of male patients (69%) was more than female patients (31%) because of the greater outdoor activity.

Our patients are followed for 12 week's period and evaluated by criteria of the demerit points system of Gartland and Werley's. Sixteen cases had excellent outcomes (50%), 14 cases had a good outcome (43.75%), 2 (6.25%) cases had fair results, and no one in our study had a poor outcome, which similar to Bradway and Cooney study (1989) [13]. Their study on 16 patients with intra-articular distal radius fractures with a mean follow-up of 5.7 years. The assessment was based on the same score criteria. They had 56% excellent, 25% good, 19% fair, and no poor result, with a high percentage of excellent results with no poor results.

In our study, the average age was 39.6 years old (19–65 years), 18 patients were below the age of 40 years and 14 patients were above 40 years of age.

In Bradway and Cooney series (1989) [13], the average age of the 16 patients was 40 years,

the youngest was 28 years and the oldest was being 75 years.

In this study, 12 patients (75%) had right side involvement and 4 patients (25%) had left side involvement, this may be due to the fact that the dominant extremity reaches out first to respond to the first impact of trauma, which against to series of Bradway and Cooney (1989) [13], showed equal involvement of both wrists but in Jupiter and Fernandez series (1997) [14] had increased involvement of the right wrist which was the same of our study.

Regarding the mode of injury, we found that half of our patients fall on the outstretched hand, RTA in 12 patients (37%) which was the same in Bradway and Cooney series [13] that the most common mode of injury was fall on outstretched hand seen in 11 patients (69%) and RTA was seen in 4 patients (31%). While Madhukar *et al.* (2016) [15] reported 75% of cases injured by RTA, 11% by a fall on the outstretched hand, extensive use of two-wheelers, poor roads conditions, and lack of adherence to traffic rules seem to have contributed to high prevalence to road traffic accidents as a causative factor [15].

The final results in this study after an average follow-up of 12 weeks revealed that 50% had excellent, 43.75% had good, and 6.25% had fair results.

This study is comparable in terms of outcome to Bradway *et al.* (1989) [13], Bhattacharya *et al.* (2015) [16], Madhukar *et al.* (2016) [15], and Satveer *et al.* (2018) [17] (Table 6).

**Table 6: Gartland and Werley scoring system**

Study	Excellent (%)	Good (%)	Fair (%)	Poor (%)
Bradway <i>et al.</i>	56	25	19	0
Bhattacharya <i>et al.</i>	40	50	5	5
Madhukar <i>et al.</i>	57	33	7	3
Satveer <i>et al.</i>	47	40	10	3
Present study	50	43.75	6.25	0

In this study, all fractures were united uneventfully. The fracture healing process is not delayed because of its cancellous bone and thus high success rate.

Postoperatively, no case complains of altering median nerve function, hence, we recommend that the release of the median nerve is not mandatory for ORIF of volar Barton fracture.

Regarding complications in our study, only one patient had mild deformity due to malunion, which put her into fair class due to the limit of wrist range of motion and reduced grip strength.

In recent years, volar locked plating is gained popularity because of stable fixation for periarticular

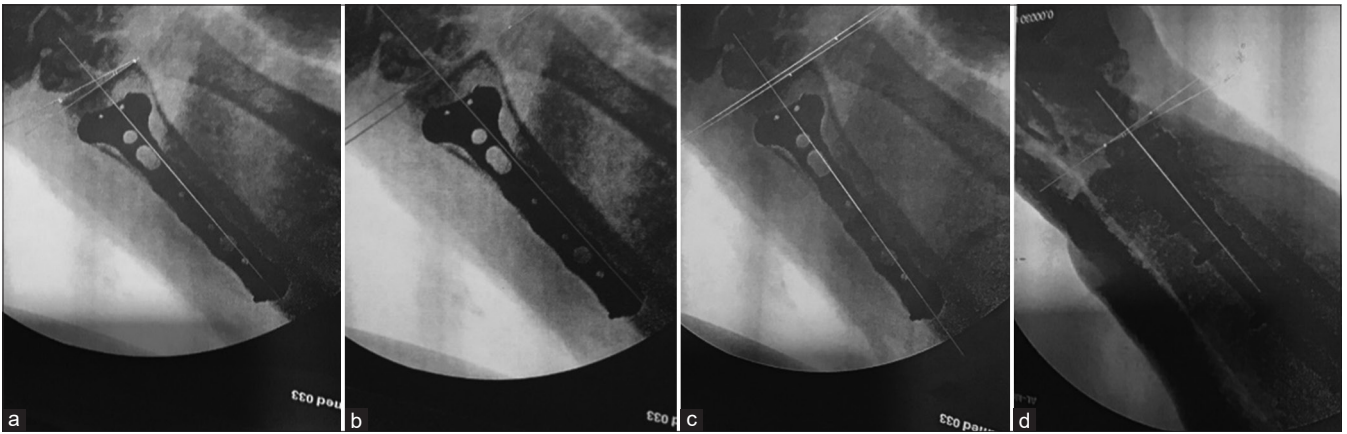


Figure 3: Post-operative measurement. (a) Radial inclination 15°, (b) radial height 9°, (c) ulnar variance 1 mm, and (d) volar tilt 8°

fractures despite osteopenia and ability to facilitate early motion and rehabilitation, in addition, variable angle locking plate and screws provide great versatility. These plates are low profile, pre-contoured providing less soft-tissue irritations compared with conventional plate.

## Conclusions

Buttress locking plate provides fracture stability and early mobilization; therefore, joint movement and daily activities are improved in a short period, and the pre-operative plan and evaluation are a must for a good outcome.

### Limitation of the study

Small number of patients and short follow-up period are the main limitation of the study, thus further studies with large number of patients can give more insight in these type of unstable fracture management.

## References

- Bloom A, Warwick D, Whitehouse MR. Apley and Solomon's System of Orthopedics and Fractures. 10<sup>th</sup> ed. Milton Park, Abingdon-on-Thames: Taylor and Francis Group; 2018. p. 407-711.
- Derek Moore. Wrist Trauma; 2019. Available from: <https://www.orthobullets.com> [Last accessed on 2019 Feb 25].
- Azar FM, Beaty JH, Canale ST. Campbell's Operative Orthopaedics. 13<sup>th</sup> ed. Maryland Heights, Missouri: MOSBY Elsevier; 2017. p. 2990-9.
- Keith M, Agur A, Arthur D. Clinically Oriented Anatomy. 7<sup>th</sup> ed. Lippincott Williams and Wilkins; 2013. p. 446.
- Zemel NP. The prevention and treatment of complications from fractures of distal radius and ulna. *Hand Clin.* 1987;3(1):1-11. PMID:3818803
- Smithius R, van Delden O. Radiology Assistant Musculoskeletal System; 2019.
- Westphalia T, Piatek S, Schubert S, Winckler S. Outcome after surgery of distal radius fracture: No difference between external fixation and ORIF. *Arch Orthop Trauma Surg* 2005;30:289-99.
- Vasenius J. Operative treatment of distal radius fractures. *Scand J Surg* 2008;97:290-6.
- Harness N, Ring D, Jupiter JB. Volar Barton's fractures with a concomitant dorsal fracture in older patients. *J Hand Surg Am.* 2004;29(3):439-45. <https://doi.org/10.1016/j.jhsa.2003.12.009> PMID:15140487
- Kwok IH, Leung F, Yuen G. Assessing results after distal radius fracture treatment: A comparison of objective and subjective tools. *Geriatr Orthop Surg Rehabil.* 2011;2(4):155-60. <https://doi.org/10.1177/2151458511422701> PMID:23569685
- Tang Z, Yang H, Chen K, Wang G, Zhu X, Qian Z, et al. Therapeutic effects of volar anatomical plates versus locking plates for volar Barton's fractures. *Orthopedics.* 2012;35(8):e1198-203. <https://doi.org/10.3928/01477447-20120725-19> PMID:22868605
- Aggarwal AK, Nagi ON. Open reduction and internal fixation of volar Barton's fractures: A prospective study. *J Orthop Surg (Hong Kong).* 2004;12:230-4. <https://doi.org/10.1177/230949900401200218> PMID:15621913
- Bradway JK, Amarion PC, Cooney WP 3<sup>rd</sup>. Open reduction internal fixation of displaced comminuted intraarticular fracture of the distal end of the radius. *J Bone Joint Surg.* 1989;71A(6):839-47. PMID:2745480
- Jupiter JB, Fernandez DL. Comparative classification for fractures of the distal end of the radius. *J Hand Surg Am.* 1997;22(4):563-71. [https://doi.org/10.1016/S0363-5023\(97\)80110-4](https://doi.org/10.1016/S0363-5023(97)80110-4) PMID:9260608
- Madhukar, Srinivasan N, Pugazhendhi G, Vijayanarasimhan, Sivakumar A, Venkatachalam K. Functional outcome of volar Barton's fracture treated with volar plate osteosynthesis. *Sch Acad J Biosci.* 2016;4(3B):237-43.
- Bhattacharya P, Choudhury FA, Khanna A. Treatment outcome of locking compression plates in volar Barton's fracture. *Int J Med Phar Sci.* 2015;5(5).
- Sing S, Nelofar M, Dave JK. Prospective study of evaluations of functional outcome of volar Barton's fractures of distal radius treated by volar plating. *Int J Sci Res.* 2018;7(6):439-44. <https://doi.org/10.21275/ART20182922>