

Morphologic Evaluation of the Permanent Mandibular First Molar within an Iraqi Population Using Cone Beam Computed Tomography (Retrospective Study)

Duaa M Shihab, Anas F Mahdee*

Department of Restorative and Aesthetic Dentistry, College of Dentistry, University of Baghdad, Bab Al-Muhaadam, Medical Centre Campus, Baghdad, Iraq

ABSTRACT

Purpose: To evaluate morphologic features of permanent mandibular first molars within an Iraqi population using Cone Beam Computed Tomography (CBCT).

Materials and methods: 384 CBCT images of Iraqi people aged 15-45 years old and obtained between 2016-2021 were collected from four different geographic regions of the country. Mandibular first molars were examined in three different planes to identify canal number and configuration (vertucci classification) for each root and tooth anomalies, including Middle Mesial Canal (MMC), Middle Distal Canal (MDC), Radix Entomolaris (RE), Radix Paramolaris (RP) and C-Shaped Canal (CSC).

Results: The predominant canal number in the mesial root was two (86%), configured either class IV or II. In the distal root, one canal with class I configuration was most frequently observed (66%). Regarding tooth anomalies, MMC was the most frequently recorded (13.22%), followed by RE (5.64%), MDC (5.48%) and CSC (0.64%). Majority of these parameters showed statistical relations with geographical region and patient sex.

Conclusion: Mandibular first molars have root canal complexities, with several anomalies that showed regional and gender differences in prevalence. CBCT is applicable method in diagnosing root canal complexity, but with caution on risks of radiation.

Key words: CBCT, Mandibular first molar, Root morphology, Root canal configuration

HOW TO CITE THIS ARTICLE: Duaa M Shihab, Anas F Mahdee, Morphologic Evaluation of the Permanent Mandibular First Molar within an Iraqi Population Using Cone Beam Computed Tomography (Retrospective Study), J Res Med Dent Sci, 2023, 11 (08): 069-077.

Corresponding author: Dr. Anas F Mahdee

E-mail: a.f.mahde@codental.uobaghdad.edu.iq

Received: 24-Jun-2022, Manuscript No. JRMDS-22-67558;

Editor assigned: 27-Jun-2022, PreQC No. JRMDS-22-67558 (PQ);

Reviewed: 11-Jul-2022, QC No. JRMDS-22-67558;

Revised: 11-Aug-2023, Manuscript No. JRMDS-22-67558 (R);

Published: 18-Aug-2023

INTRODUCTION

The successful outcome of endodontic treatment relies on both technical and biological factors [1,2] and it is recognized that even contemporary methods of root canal debridement and filling are limited by the anatomical complexity of the root canal system. For this reason, studies of root canal anatomy and common variants within defined populations are justified [3].

The mandibular first molar is usually recognized to have mesial and distal roots, which are flattened mesiodistally [4]. It is the first permanent tooth to erupt in the oral cavity, with complex occlusal anatomy and plaque retentive features, which make it susceptible to caries during early life. These factors may increase risks of pulp

inflammation and the potential need for endodontic treatment [5]. Numerous anatomical variation has been described within the pulp system of the mesial and distal roots such as the presence of extra canals [6,7]. Variations in root number were also reported including smaller distolingual, middle lingual, or bucco-mesial roots. All roots may also be attenuated into a single C-shaped root with aberrant canal anatomy. These morphological variations have been reported to be associated with patient ethnicity, origin, sex and age [8-13].

The diverse geographic nature of Iraqi lands can be categorized into four distinct regions: The north mountainous region, namely Kurdistan, mainly inhabited by Kurdish and to a lesser extent by people of Arabs and Turkmen [14]. The western north hilled area, the alluvial plains in the middle and south parts, in addition to the western deserts' region are populated mostly by people of Arabic origin [15].

Among all clinical and laboratory methods for the investigation of 3-dimensional root canal morphology, CBCT has proved, simple, efficient and cost-effective

method. It can provide acceptable precision and non-destructive detection of root canal systems in three dimensions [16].

This paper aims to assess the anatomical complexity of the mandibular first permanent molar in a previously unstudied Iraqi population, using CBCT archives of previously exposed cases. The aim was to examine root morphology, canal configurations and anomalies within each root of this tooth, and identify associations between anatomical variation, patient sex and geographic origin within a mixed Iraqi population. In addition, this report presents the correlation between the shape of root cross sections and the number of canals at different axial levels coronally-apically.

MATERIALS AND METHODS

This retrospective cross-sectional study was prepared in compliance with the Strengthening the Reporting of Observational studies in Epidemiology (STROBE) checklist for cross-sectional studies [17-18].

Population estimation and sample size calculation

The study population consisted of 15 to 45 years old individuals, representing 42% of the total Iraqi population (approximately 45 million). The following formulas were used for sample size calculation:

$$n = Z^2 P(1-P) / d^2$$

Where,

n (calculated sample size)

Z (confidence interval at 95%)=1.96,

P (expected prevalence)=0.5,

d (error margin)=0.05

True sample size=(sample size × population)/(sample size+population-1)

The calculated sample size was 384, which was proportionally distributed according to the percent of population densities in different geographic areas of Iraq.

This number was multiplied by 5 to allow for 20% valid number of measurements and avoid possible drop out of the sample, which was previously estimated from a pilot study using the following formula [19].

$$N = n / (1 - (z/100))$$

Where N (total collected samples)

z (expected attrition rate 80%)

Therefore, the total collected samples were (384 × 5=1920).

Sample selection

CBCT scans of 384 patients of Iraqi origin were collected from four different geographic regions (mountains, hills, alluvial lands, and deserts) with proportions depending on the population density for each region (Figure 1). Additionally, comparable sample sizes were collected for

other variables (sex and tooth side) within each region of the study. Scans were gained from the archived data in the dental radiographic departments of both government and private health institutions. All included patients had previously been referred from dental or maxillofacial clinics for 3D imaging between 2016 and 2021.

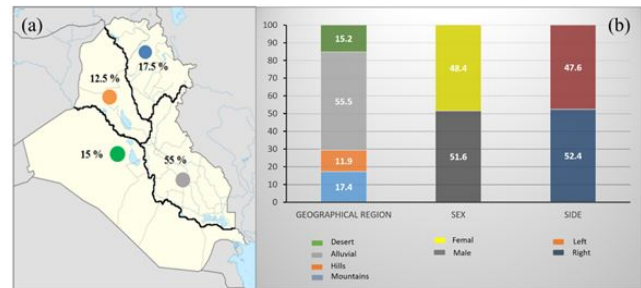


Figure 1: Multi-panel illustration shows, (a) A map of Iraq with four geographic regions and their population densities; (b) Bar chart illustrates percentages of study samples according to three variables (geographic region, sex, and tooth side).

Selection criteria

Inclusion criteria for valid CBCT scans in this study included:

Clear image of the mandible exposes the mandibular first molar region on both sides (preferably medium FOV).

- Presence of at least one permanent first molar tooth with fully developed and closed root apices.
- Normal shape and density of enamel and dentine.
- Healthy periodontal tissue.

Exclusion criteria included:

- Blurred images.
- Immature tooth or open root apex.
- Root canal treatment.
- Crown and post treatment.
- Root caries.
- Coronal caries encroaching on pulp chamber space.
- Root fracture.
- Internal or external resorption.
- Periapical or periodontal lesion.
- Skeletal asymmetry, trauma, or bony disease affecting the mandible.
- Unclear or deranged tooth anatomy due to physiologic or pathologic condition.

Training and pilot study

Before commencing this study, the researcher (DM) passed general training conducted by an experienced radiologist on CBCT device operation, image setting and management, and identifying the root and root canal morphology on different views. A pilot study was then carried out on 38 samples (10%), during which the researcher and two endodontists undertook observations independently, on the same screen, and the same lighting conditions. After a period of 2 weeks, the same process

was performed before kappa analysis was applied to determine inter and intra-observer agreement.

Radiographic technique and image analysis

Large to medium sized CBCT study samples (23%, 77%, respectively of the total sample size) were obtained from five different devices (CARESTREAM 8100 3D, France, 2017) (Villa, Italy, 2017) (GALILIOS Sirona comfort PLUS unit, Germany) (GENDEX, GDDP-700-1, Finland, 2014) (WhiteFox control, Australia, 2017), and displayed by installed software (CS 3D imaging v 3.8.6) (dental studio) (GALILEOS viewer v1.9) (*In vivo* dental viewer v 5.1) (white fox imaging) correspondingly. Technical settings and parameters were in the following ranges: FOV (8 × 9 to 16 × 17 mm²), image height: 7 to 13 cm, voxel size (0.125 to 0.200 mm³), slice thickness (0.15 to 1 mm), exposure time (15 to 10.08' s), tube voltage (80 to 105 Kvp), and tube current (3.2 to 10 mA). Images were displayed on a single 15.6 inch DESKTOP-NOBV05T laptop computer, with 1920 × 1080 screen resolution. Before starting examination of tooth slices, the axial view angulation was adjusted to be parallel with the long axis of each root/root section. Serial reformatted images in adjusted axial, sagittal, and coronal sections of the target tooth were then observed, analyzed, and documented, by sliding the mouse pointer scrolling ring back and forth along each section. Zooming was kept standardized for all images, while contrast and brightness were adjusted for each sample for better details observations. Samples were studied by the researcher twice (with at least one week between readings) in one hour sessions, to reduce eye fatigue, before conducting kappa analysis for intra-observer reliability. The following tooth aspects were identified:

- Root canal number in the mesial and distal roots.
- Root canal configuration in the mesial and distal roots, according to Vertucci's classification [20].

- **Incidence of aberrant anatomic features:** Middle Mesial Canal (MMC) (modified Mehrnaz's method, details illustrated in the discussion section), Middle Distal Canal (MDC) (modified Mehrnaz's method), Radix Entomolaris (RE) (additional third root located disto to medio-lingually), Radix Paramolaris (RP) (additional third root located bucco-mesially), and C-Shaped Canal (CSC) [21].

Statistical analysis

Descriptive statistics was expressed by frequency and percentage, while correlation analysis was done by *Chi-square* test, at a confidence level of 95%, and P value of 0.05. Statistical analysis was performed using IBM SPSS software (version 23, IBM, USA), and figures and tables were plotted using Excel Microsoft Office Professional Plus 2013. Inter and intra-examiners correlation tests were also calculated.

RESULTS

Among 384 CBCT samples evaluated, 620 mandibular first molar teeth were valid for data registration. These samples were sorted according to three demographic variables (geographic region, patient sex, and tooth side). Scans derived from clinics in the alluvial region occupied the highest percentage (55%) of samples, while scans from clinics in the hilled lands represented the smallest proportion (12.5%) (Figure 1). Comparable numbers of samples were collected for patient sexes, and sides of the mandible. Cohen kappa value for inter-examiner agreement ranged between 0.6 to 0.78, while the intra-examiner agreement ranged between 0.8 to 1, this revealed perfect agreement [22].

With respect to the mesial root, the highest percentage were contained two canals (85.6%), much less (13.2%) had three canals, and very small percentages presented with other variants (Table 1). There were no significant correlations between the number of canals in the mesial root and other study variables.

Table 1: Mesial root canal number of the permanent mandibular first molar. Descriptive statistics includes frequency (and percentage for totals values) and inferential statistics represented by *Chi square* test. *Total row represents the same total for each study variable (geographical region, sex or tooth side) individually.

Variable		Mesial root canal number				Total (100%)	Chi ²
		1	2	3	4		
Geographical regions	Mountains	0	85	22	1	108 (17.53)	0.138
	Hills	0	64	9	0	74 (12.01)	
	Alluvials	0	302	38	1	341 (55.35)	
	Desert	1	80	13	0	94 (15.25)	
Sex	Male	1	268	51	0	320 (51.94)	0.072
	Female	0	263	31	2	296 (48.05)	
Tooth side	Right	0	274	47	2	323 (52.43)	0.278
	Left	1	257	35	0	293 (47.56)	

Total* (%)	1 (0.16)	531 (86.20)	82 (13.31)	2 (0.32)	616 (100)
------------	----------	-------------	------------	----------	-----------

The dominant canal configurations within the mesial root (Table 2), according to Vertucci's classification, were class IV (39.2%) and class II (36.8%), with smaller proportions of other configurations. Other canal forms not consistent with Vertucci's classification were also found, which were approximately 21 extra canal configurations. However, the percentage of each of these forms was very small, therefore, presented together with total percentage of 13.9%. There was a statistically

significant difference for the canal configurations among different geographic regions (0.000). The widely evident class II canals had low incidence in the mountainous area (16.66%), which contained higher percentages of the class IV variant (58.33%). The non-Vertucci's configurations were highly concentrated in the desert lands (22.34%), with lowest levels observed in the hilled region (6.75%).

Table 2: Mesial root canal classification of the permanent mandibular first molar according to study variables. Descriptive statistics includes frequency (and percentage for totals values), inferential statistics represented by Chi square test. *Total row represents the same total for each study variable (geographical region, sex or tooth side) individually.

Variable		Mesial root canal classification								Total (100%)	Chi ²
		I	II	III	IV	V	VI	VIII	others		
Geo-region	Mountain	0	18	0	63	1	2	11	13	108 (17.53)	0
	Hills	0	27	0	37	0	0	4	5	74 (12.01)	
	Alluvials	0	150	2	114	2	9	17	47	341 (55.35)	
	Desert	1	33	2	29	0	1	7	21	94 (15.25)	
Gender	Male	1	111	2	131	0	5	27	43	320 (51.94)	0.146
	Female	0	117	2	112	3	7	12	43	296 (48.05)	
Tooth side	Right	0	123	3	121	2	7	20	47	323 (52.43)	0.845
	Left	1	105	1	122	1	5	19	39	293 (47.56)	
Total* (%)		1 (0.16)	228 (37.01)	4 (0.64)	243 (39.44)	3 (0.48)	12 (1.94)	39 (6.33)	86 (13.96)	616 (100)	

For the distal root (Table 3), the number of detected root canals was either one or two (66% or 28.2% respectively), with very few presenting with 3 canals. A statistically significant relation was identified between the distal root canal number and both the geographical region and patient sex (0.000). The incidence of two canals within the distal root was apparently higher in samples from the mountainous area (representing 45.37% of this region), in comparison to other

geographical regions which had a higher incidence of one canal, especially in the alluvial region (73.9%). Moreover, the incidence of third canals within the distal root of specimens derived from alluvial lands was much lower (2.05%) when compared to the other geographical areas. In addition, the incidence of three canals within the distal root was higher in males (9.06%) in comparison to females.

Table 3: Root canal numbers within distal of the permanent mandibular first molar according to study variables. Descriptive statistics includes frequency (and percentage for totals values), inferential statistics represented by Chi square test. *Total row represents the same total for each study variable (geographical region, sex or tooth side) individually.

Variables		Distal root canal number			Total (100%)	Pearson Ch ²
		1	2	3		
Geographical region	Mountains	48	48	12	108 (17.53)	0
	Hills	50	17	6	74 (12.01)	
	Alluvials	252	82	7	341 (55.35)	
	Desert	58	27	9	94 (15.25)	
Gender	Male	207	84	29	320 (51.94)	0

	Female	201	90	5	296 (48.05)	
Tooth side	Right	210	100	13	323 (52.43)	0.17
	Left	198	74	21	293 (47.56)	
Total* (%)		408 (66.23)	174 (28.24)	34 (5.51)	616 (100)	

The commonest root canal configuration within the distal roots (Table 4), according to vertucci’s classification, was class I (65.6%), with other configurations observed less frequently such as classes IV, II and V (11.8%, 7.4%, and 6% respectively). Similar to the mesial root canals, some canal configurations that did not conform to vertucci classification were also found within the distal root, but at low levels (3.5%). A statistically significant relation

was also detected between canal configurations in the distal roots and both the geographic region and patient sex (0.000, 0.006, respectively). Individually, samples from the mountainous region showed high incidence of class IV configuration (30.55%). In addition, samples collected from males had higher frequencies of both class VIII (4.37%) and non-Vertucci (5.93%) forms in comparison to females.

Table 4: Distal root canal classification of the permanent mandibular first molar according to study variables. Descriptive statistics includes frequency (and percentage for totals values), and inferential statistics represented by Chi square test. *Total row represents the same total for each study variable (geographical region, sex or tooth side) individually.

Variable	Distal root canal classification									Total (100%)	Chi ²
	I	II	III	IV	V	VI	VIII	Others			
Geo-regions	Mountains	48	6	1	33	8	0	6	6	108 (17.53)	0
	Hills	50	5	0	8	4	0	1	5	74 (12.01)	
	Alluvials	252	28	6	20	21	4	5	5	341 (55.35)	
	Desert	57	7	1	12	4	2	5	6	94 (15.25)	
Gender	Male	206	20	4	34	19	4	14	19	320 (51.94)	0.006
	Female	201	26	4	39	18	2	3	3	296 (48.05)	
Tooth side	Right	209	24	4	46	19	3	6	12	323 (52.43)	0.592
	Left	198	22	4	27	18	3	11	10	293 (47.56)	
Total* (%)		407 (66.07)	46 (7.46)	8 (1.29)	73 (11.85)	37 (6)	6 (0.97)	17 (2.75)	22 (3.57)	616 (100)	

The majority of the examined molars showed symmetrical bucco-lingual distribution of the canal orifices on the pulp chamber floor (93.2%). A statistically significant relation for this property was detected only within the geographic regions (0.000), as samples obtained from the mountainous area presented a higher incidence of asymmetrical configuration (22.22%).

Observing anomalies within permanent mandibular first molars (Table 5), most of the evaluated teeth had no anomalous features (78.2%). The most frequently detected abnormality was MMC (13.22%, 82), followed by: RE (5.64%), MDCs (5.48%), and the least was for CSC (0.64%), while no RP was identified. There was a

statistically significant relation between anomalies within this tooth and the geographical origin of samples (0.000). Noticeably, 39% of the samples documented from the mountainous area appeared with different anomalies (anomalous root number RE: 12.03% and anomalous canal number MMC: 20.37%, MDC: 11.11%), in comparison to other regions. A statistically significant relationship was also found between patient sex and anomalies within this tooth (0.000), with male samples showing higher incidence of MDCs (9.06%) than in female (1.6%). Females, by contrast, showed a much higher incidence of anomalies related to root number (RE) when compared to males (8.66%, 2.81%, respectively).

Table 5: Anomalies within the permanent mandibular first molars in comparison to study variables. Descriptive statistics includes frequency (and percentage for totals values), and inferential statistics represented by Chi square test. *Total row represents the same total for each study variable (geographical region, sex or tooth side) individually.

Variable	Anomalies	Total (100%)	Pearson Chi ²
----------	-----------	--------------	--------------------------

		None	MMC	MDC	RE	CSC		
Geographical regions	Mountains	61	22	12	13	0	100 (17.41)	0
	Hills	53	9	6	5	1	74 (11.93)	
	Alluvials	282	39	7	13	3	344 (55.48)	
	Desert	69	12	9	4	0	94 (15.16)	
Gender	Male	231	51	29	9	0	320 (51.61)	0
	Female	234	31	5	26	4	300 (48.38)	
Tooth side	Right	244	47	13	19	2	325 (52.41)	0.476
	Left	221	35	21	16	2	295 (47.58)	
Total* (%)		465 (75)	82 (13.22)	34 (5.48)	35 (5.64)	4 (0.64)	620 (100)	

DISCUSSION

The main findings of this retrospective study on an Iraqi population were that geographical location and patient sex had significant associations with tooth morphology and canal configuration of the permanent mandibular first molar tooth. These included canal number and canal configuration for each root, and a variety of tooth anomalies.

In the last decade, 3D imaging techniques have become popular for observational studies of dental morphology. Such technology supersedes traditional radiography (peri-apical and panoramic), which failed to represent the third dimension of dental structure with adequate resolution, and made the assessment of complex tooth anatomy challenging [23]. Among contemporary imaging systems, Micro-Computed Tomography (μ -CT) could be set at the top of the pyramid in terms of three-dimensional image quality. However, because of its high radiation doses, and long scanning and rendering times, it is only applicable for *in vitro* studies [24]. Therefore, CBCT was employed within the present study where historical clinical records could be assessed without any need for further costly intervention or radiation exposure to patients. To validate data examination procedure, a kappa test appeared with high agreement in inter and intra-examiner evaluation.

In the present study, the collection of images was depending on the percentage of population within geographical regions rather than race distribution in the assessment of associations of the dental and pulp anatomy. Race factor is difficult to be accounted in a retrospective study. Furthermore, there is no available data about race distribution within the whole Iraqi country to be used as a factor for such analysis.

In the current study, the predominant Vertucci configurations were type II and IV (39.2%, 36.8% respectively) in the mesial root, and type I (65.6%) in the distal root (Figures 1a and 1b). These results partially disagree with a previous study by Martins et al. [25] who compared root canal configuration of the mandibular first molars derived from patients of two different ethnicities, Asians and Whites. The study showed predominant Vertucci configuration in the mesial root,

was type IV for Asians (76.8%) and type II (46.9%) for Whites, with a very rare incidence of type I for both, while in the distal root, type I configuration constituted the major form (70.8%-79.5%), followed by type IV for Asians (7.7%), and type II for Whites (11.9%).

Observations of a second canal in the distal root of mandibular first molar was recorded in 28.2% of the collected samples. This appears in the middle of a range from previous reports (between 10.4 and 51.9%) for different ethnicities and populations [26-29].

The detection of a middle mesial canal is highly variable in many reports from different populations (0.26%–53.8%)[30-32]. This variation may be influenced by variations in examination technique and confusion with isthmuses, but primarily by the method of identification [33], as in Pomeranz's [34] and Mehrnaz's theories. In this study the "modified Mehrnaz's method" was proposed, in which the presence of middle root canal was defined as an obvious round cross-sectional appearance between buccal and lingual root canals, and limited to those starting up from the pulp chamber floor because of their clinical significance. This method was adopted for identification of both MMC and MDC configurations (13.2% and 5.48% respectively). Although different reports have documented the incidence of MMCs within the mandibular first molar, the MDC was less mentioned in the literature, and in a more limited range (0.2%-3%) [35]. This unavoidable possibility of additional canals prompts the clinician to follow the appropriate clinical procedures on endodontic access opening, pay attention to unusually persistent endodontic signs and symptoms, and make use of other modalities for canals detections such as magnification and enhanced lighting.

Triple-rooted mandibular first molars with an extra mesial root located disto to medio-lingually (Radix Entomolaris) (RE) presented in 5.6% of tested teeth. This agrees with the result of a previous clinical study conducted in Baghdad with a similar sample size (5.8%) [36], but differs from two older Iraqi studies. One was a mixed clinical and laboratory investigation which found a higher prevalence of RE (8.1%) [37], while the other was a clinical study for Iraqi Arabic people with smaller sample size (120) revealed a prevalence of 1.6% [38]. In general, the incidence of a third root within samples of

permanent mandibular first molars may be associated with racial origin, appearing as a usual morphological feature within Asian populations, reaching up to 29% in Chinese, 25.9% in Japanese [39] and 25.82% in Korean populations [40], reducing to 8.98% in Indian [41], and less than 5% in Turkish, European, Eurasian [42] and Saudi populations [43].

In the present study, all the examined single-rooted mandibular first molars presented with a C-Shaped Canal (CSC) configuration. This aspect was not investigated previously for the permanent mandibular first molar within an Iraqi population. The detected incidence of C-shape canal was (0.6%), which is comparable to other similar studies in Saudi Arabia (0.19%) [44], Israel (0.16%) [45], Brazil (1.7%) and Portugal (0.6%) [46]. C-shaped canal has been also detected in other teeth such as mandibular premolars[47], maxillary lateral incisors and molars [48-49]; however, its highest observations were in mandibular second molars, especially within east Asian population (2.7%-44.5%) [50].

Regarding correlation analysis, geographical region especially mountainous area was the more associated with tooth variations. These included a higher incidence of most anomalous conditions (MMCs 20.37%, MDCs 11.11%, RE 12.3%), second distal canals (45.37%), and different canal configurations in the mesial root (less values for class II: 16.6% compensated by class VIII and other rare canal forms) and the distal root (less incidence of class I: 44.4% compensated with class IV and class VIII canals) compared to other geographic regions. This could be attributed to the abundance of people of Kurdish origin in this area in comparison to other regions in Iraq. Another cause could be the difference in the life style of people living in this region which may affect tooth morphology through generations. Similarly, patient sex was shown in the current study to be associated with variations in tooth morphology, which summarized as a significantly higher prevalence of a third root (RE) in females compared to those in males, and third distal canals in males compared to those in females. Although, several comparable studies found no such association.

One of the limitations for this study was different CBCT imaging devices from which data was collected. These devices varied in the FOV, settings and technical parameters. These could affect image resolution and the detection of tooth anatomical features, especially the fine details which may require higher resolution scans. However, it was difficult for the researchers to find similar devices with similar parameters and proper FOV scans from different regions included in this study. Therefore, this should be taken in consideration for any future interpretation. Another limitation which is inevitable in observational studies is the subjectivity during data analysis. All efforts were taken to standardize the assessment methods for each parameter, including the use of second observers and kappa analysis, which revealed high levels of agreement.

The comparison of our data on the basis of tooth side was done in general (all right teeth against all left teeth), as

some of the scans contained unilateral or bilateral molars. This should be taken in consideration in future comparison with other studies.

Additionally, although this epidemiological analysis was based on international information about the population size and distribution in Iraq, there is no recent national census for the total Iraqi population size, races and their regional distribution and densities. This could be considered as another limitation for the current study.

According to such type of investigations which targeted special population, the results obtained cannot be generalized and further studies should be done on different populations to widen the knowledge in this field of science.

CONCLUSION

In conclusion, permanent mandibular first molars showed variations in their root morphology and canal configurations within Iraqi population. These variations were correlated with geographical region and sex factors. Dentist should be aware about the complexity of root canal system of the mandibular first molars. Good knowledge of tooth anatomy and the use of 3D scans can improve root canal identification for better treatment outcomes.

ETHICAL APPROVAL

This study was based on the retrospective evaluation of CBCT images and was approved by the Research Ethics Committee in College of Dentistry University of Baghdad (Ref. no. 345 in 13-06-2021).

ACKNOWLEDGEMENT

The authors are grateful to Dr. Maisaa Ali the radiologist in Al-falah medical centre for her role in training the researcher on cbct software. Special thank for assistant prof. Dr. Ali Abdulkareem in department of periodontics university of Baghdad for his role in the study design. Authors also thank assistant prof. Dr. Ahmed Ali and lecturer Dr. Nassr al-nuaimi in the department of restorative and aesthetic dentistry university of Baghdad for their statistical advices. Special thanks to Prof. John M Whitworth for his kind efforts in reviewing the manuscript.

REFERENCES

1. Robinson S, Czerny C, Gahleitner A, et al. Dental CT evaluation of mandibular first premolar root configurations and canal variations. *Oral Surg Oral Med Oral Pathol Oral Radiol* 2002; 93:328-332.
2. Barbizam JVB, Ribeiro RG, Tanomaru Filho M. Unusual anatomy of permanent maxillary molars. *J Endod* 2004; 30:668-671.
3. Witherspoon DE, Small JC, Regan JD. Missed canal systems are the most likely basis for endodontic retreatment of molars. *Tex Dent J* 2013; 130:127-139.

- Silva EJNL, Nejaim Y, Silva AV, et al. Evaluation of root canal configuration of mandibular molars in a Brazilian population by using cone-beam computed tomography: An *in vivo* study. *J Endod* 2013; 39:849-852.
- Baugh D, Wallace J. Middle mesial canal of the mandibular first molar: A case report and literature review. *J Endod* 2004; 30:185-186.
- Ballullaya SV, Vemuri S, Kumar PR. Variable permanent mandibular first molar: Review of literature. *J Conserv Dent* 2013; 16:99.
- Venumuddala VR, Sridhar M, Rajasekaran M, et al. Endodontic management of mandibular first molar with middle distal canal: a case report. *Case Rep Dent* 2012; 4.
- Sert S, Bayirli GS. Evaluation of the root canal configurations of the mandibular and maxillary permanent teeth by gender in the Turkish population. *J. Endod* 2004; 30:391-398.
- Nosrat A, Deschenes RJ, Tordik PA, et al. Middle mesial canals in mandibular molars: incidence and related factors. *J Endod* 2015; 41:28-32.
- Peiris H, Pitakotuwage T, Takahashi M, et al. Root canal morphology of mandibular permanent molars at different ages. *Int Endod J* 2008; 41:828-835.
- Zheng Q, Zhang L, Zhou X, et al. C-shaped root canal system in mandibular second molars in a Chinese population evaluated by cone-beam computed tomography. *Int Endod J* 2011; 44:857-862.
- Kim S, Kim B, Kim Y. Mandibular second molar root canal morphology and variants in a Korean subpopulation. *Int Endod J* 2016; 49:136-144.
- Ahmed HA, Abu-Bakr N, Yahia N, et al. Root and canal morphology of permanent mandibular molars in a Sudanese population. *Int Endod J* 2007; 40:766-771.
14. Nezan K. The Kurdish population. 12th Edition. Kurdish Institute of Paris. Paris, France. 2017.
 15. Central-Statistical-Organization (CSO), population estimation of Iraq. Iraqi ministry of planning 2019.
 16. Kim SY, Yang SE. Cone-beam computed tomography study of incidence of distolingual root and distance from distolingual canal to buccal cortical bone of mandibular first molars in a Korean population. *J Endod* 2012; 38:301-304
- Von Elm E, Altman DG, Egger M, et al. The Strengthening the Reporting of Observational Studies in Epidemiology (STROBE) statement: guidelines for reporting observational studies. *J Clin Epidemiol* 2008; 61:344-349.
- Kotrlik J, Higgins C. Organizational research: Determining appropriate sample size in survey research appropriate sample size in survey research. *ITLPI* 2001; 19:43.
19. Mahdee AF, Gul SS, Abdulkareem AA, et al. Anxiety, practice modification and economic impact among iraqi dentists during the COVID-19 Outbreak. *Front Med (Lausanne)* 2020; 7:595028.
 20. Vertucci FJ. Root canal anatomy of the human permanent teeth. *Oral Surg Oral Med Oral Pathol Oral Radiol* 1984; 58:589-599.
 21. Fan B, Cheung GS, Fan M, et al. C-shaped canal system in mandibular second molars: Part I-anatomical features. *J Endod* 2004; 30:899-903.
 22. Landis JR, Koch GG. The measurement of observer agreement for categorical data. *Biometrics* 1977; 33:159-174.
 23. Shihab DM, Mahdee AF. Root and Root Canal Morphology: Study Methods and Classifications. *JBCD* 2021; 33:11-19.
 24. Zhang D, Chen J, Lan G, et al. The root canal morphology in mandibular first premolars: a comparative evaluation of cone-beam computed tomography and micro-computed tomography. *Clin Oral Investig* 2017; 21:1007-1012.
 25. Martins JN, GU Y, Marques D, et al. Differences on the root and root canal morphologies between Asian and white ethnic groups analyzed by cone-beam computed tomography. *J Endod* 2018; 44:1096-1104.
 26. Celikten B, Tufenkci P, Aksoy U, et al. Cone beam CT evaluation of mandibular molar root canal morphology in a Turkish Cypriot population. *Clin Oral Investig* 2016; 20:2221-2226.
 27. Wang Y, Zheng QH, Zhou XD, et al. Evaluation of the root and canal morphology of mandibular first permanent molars in a western Chinese population by cone-beam computed tomography. *J Endod* 2010; 36:1786-1789.
 28. Mashyakhly M, Chourasia HR, Halboub E, et al. Anatomical variations and bilateral symmetry of roots and root canal system of mandibular first permanent molars in Saudi Arabian population utilizing cone-beam computed tomography. *Saudi Dent J* 2019; 31:481-486.
 29. Al-Qudah A, Awawdeh L. Root and canal morphology of mandibular first and second molar teeth in a Jordanian population. *Int Endod J* 2009; 42:775-784.
 30. Bansal R, Hegde S, Astekar M. Morphology and prevalence of middle canals in the mandibular molars: A systematic review. *J Oral Maxillofac Pathol* 2018; 22:216.
 31. Tahmasbi M, Jalali P, Nair MK, et al. Prevalence of middle mesial canals and isthmi in the mesial root of mandibular molars: An *in vivo* cone-beam computed tomographic study. *J Endod* 2017; 43:1080-1083.
 32. Azim AA, Deutsch AS, Solomon CS. Prevalence of middle mesial canals in mandibular molars after guided troughing under high magnification: An *in vivo* investigation. *J Endod* 2015; 41:164-168.

- Xu S, Dao J, Liu Z, et al. Cone-beam computed tomography investigation of middle mesial canals and isthmuses in mandibular first molars in a Chinese population. *BMC Oral Health* 2020; 20:1-9.
- Pomeranz HH, Eidelman DL, Goldberg MG. Treatment considerations of the middle mesial canal of mandibular first and second molars. *J Endod* 1981; 7:565-568.
- Kirici D, Koc S. Middle distal canal of mandibular first molar: A case report and literature review. *Niger J Clin Pract* 2019; 22:285-285.
- Abdulla, HE. Prevalence of Radix Entomolaris & Radix paramolaris in the extraction of permanent mandibular first and second molar (5-year clinical study). *MDJ* 2018; 11:96-105.
- Rashid AM, Suliman HA. Incidence of third root in mandibular permanent first molar: An endodontic challenge. *Dent J* 2006; 6:194-198.
- Jameel NG, AL Nema MM. Assessment of the morphology of apical area in Iraqi Arabic first molars. *Dent J* 2002; 2: 243-248.
- Ishii N, Sakuma A, Makino Y, et al. Incidence of three-rooted mandibular first molars among contemporary Japanese individuals determined using multidetector computed tomography. *Leg Med* 2016; 22:9-12.
- Kim SY, Kim BS, Woo J, et al. Morphology of mandibular first molars analyzed by cone-beam computed tomography in a Korean population: Variations in the number of roots and canals. *J Endod* 2013; 39:1516-1521.
- Neelakantan P, Subbarao C, Subbarao CV, et al. Root and canal morphology of mandibular second molars in an Indian population. *J Endod* 2010; 36:1319-1322.
- Gulabivala K, Opananon A, Ng YL, et al. Root and canal morphology of Thai mandibular molars. *Int Endod J* 2002; 35:56-62.
- Mashyakhy M, Chourasia HR, Halboub E, et al. Anatomical variations and bilateral symmetry of roots and root canal system of mandibular first permanent molars in Saudi Arabian population utilizing cone-beam computed tomography. *Saudi Dent J* 2019; 31:481-486.
- Alfawaz H, Alqedairi A, Alkhayyal AK, et al. Prevalence of C-shaped canal system in mandibular first and second molars in a Saudi population assessed via cone-beam computed tomography. *Clin Oral Investig* 2019; 23:107-112.
- Shemesh A, Levin A, Katzenell V, et al. C-shaped canals-prevalence and root canal configuration by cone beam computed tomography evaluation in first and second mandibular molars—a cross-sectional study. *Clin Oral Investig* 2017; 21:2039-2044.
- Martins JN, Mata A, Marques D, et al. Prevalence of C-shaped mandibular molars in the Portuguese population evaluated by cone-beam computed tomography. *Eur J Dent* 2016b; 10:529-535.
- Fan B, Ye W, Xie E, et al. Three-dimensional morphological analysis of C-shaped canals in mandibular first premolars in a Chinese population. *Int Endod J* 2012; 45:1035-1041.
- Forghani M, Moghim Farooji E, Abuchenari J, et al. Conservative treatment of an invaginated maxillary lateral incisor with a C-shaped canal using cone-beam computed tomography. *Iran Endod J* 2015; 10:281-3.
- Martins JN, Mata A, Marques D, et al. Prevalence and characteristics of the maxillary C-shaped molar. *J Endod* 2016a; 42:383-389.
- Fernandes M, Ye Ataide I, Wagle R. C-shaped root canal configuration: A review of literature. *J Conserv Dent* 2014; 17:312.