

See discussions, stats, and author profiles for this publication at: <https://www.researchgate.net/publication/328131086>

Simultaneous complete intracorneal ring implantation combined with collagen cross linking for treatment of keratoconus

Article · October 2018

CITATION

1

READS

34

1 author:



[Suzan Rattan](#)

University of Baghdad

11 PUBLICATIONS 5 CITATIONS

[SEE PROFILE](#)

Some of the authors of this publication are also working on these related projects:



Keratoconus [View project](#)



MyoRing [View project](#)

Simultaneous Complete Intracorneal Ring Implantation with Intrapocket Collagen Cross- Linking for Treatment of Keratoconus

Suzan Amana Rattan

ABSTRACT:

BACKGROUND:

Keratoconus is a progressive non inflammatory bilateral (usually asymmetric) ectatic corneal disease characterized by paraxial stromal thinning ,weakening that lead to corneal surface distortion ,vision loss primarily from irregular astigmatism and myopia and secondly from corneal scar.

OBJECTIVE:

To evaluate visual and refractive outcomes after intracorneal continuous ring (ICCR) implantation combined with intrapocket corneal collagen cross linking in patient with keratoconus.

Setting: Eye Specialty Private Hospital, Baghdad, Iraq.

METHODS:

This study assessed the results of implantation of Myoring ICCR combined with CXL in 40 eyes with KC. Outcome measures include UDVA,CDVA(spectacle correction),refraction, complications and side effects. Postoperative follow- up was up to 1 year.

RESULTS:

The study evaluated 40 eyes of 34 patients with a mean age of 25.75 years. Preoperatively, the pachymetry at thinnest location range from (367_555μm) and the mean keratometry (K) readings $50.51 \pm 3.94D$. Post operatively ,there was statistically significant improvement in the UDVA,CDVA,K reading ,manifest spherical and cylindrical refractive errors ,and spherical equivalent ($p < .05$).The mean UDVA improved by 13 lines ,CDVA improved by 3.5 lines and the mean K reading decreased by 7.14 D .No serious intraoperative complications occurred .Side effects includes glare and night vision problems.

CONCLUSION:

Treatment of KC with simultaneous ICCR implantation and intrapocket collagen cross linking significantly improved visual and refractive outcomes .the UDVA and CDVA continuously improved during the 1st year postoperatively.

KEY WORDS:keratoconus, intracorneal continuous ring, collagen cross-linking and: implantable collamer lens.

INTRODUCTION:

Surgical interventions in keratoconus have biomechanical consequences both by redistributing stress and affecting the rigidity of the cornea .These effects can result in both immediate and delayed shape changes that affect visual performance .Since corneal rigidity is greater anteriorly than posteriorly and peripherally versus centrally⁽¹⁾ ,different surgical procedures can have a different biomechanical impact.

Surgical methods for keratoconus treatment:

1. Corneal collagen cross- linking : relatively new minimum invasive surgical technique used for management of ectatic disorders producing stiffening effect capable of halting progression of ectasia and may accompanied by improvement of UDVA,CDVA, reduce myopia ,astigmatism ,K reading and high order aberration⁽²⁾.
2. Intracorneal ring segment: a widely accepted tool for vision improvement in contact lens intolerant keratoconic patient with unsatisfactory VA with glass .This approach can eliminate or delay the need for keratoplasty and improve the quality of life in patient with keratoconus⁽³⁾.

Al-Kindy Medical College Baghdad University.

3. Combined treatment approaches:

a. Collagen cross linking with intra corneal ring segment has additive effect with improvement in CDVA, SE and mean K in combined therapy better than intra corneal ring alone⁽⁴⁻⁸⁾.

b. Topographic PRK with collagen cross linking intended to reduce the topographic abnormality and reduce the amount of astigmatism while at the same time stabilize and stiffing the cornea but further studies with long term follow up is required to confirm the result⁽⁹⁻¹¹⁾.

4. Phakic ICL: is off labeled used of the lens to correct residual spherocylindrical error inpatient with stable or stabilized keratoconus⁽¹²⁻¹³⁾.

5. Keratoplasty: worsening of the disease, progression of ectasia with insufficient correction or intolerance to contact lens is one of the indications of keratoplasty and also corneal scar secondary to hydrops⁽¹⁴⁾.

New surgical option referred to as corneal intrastromal implantation system (CISIS) in which Myring full ring implant (Dioptex GmbH, Linz, AUSTRIA) is inserted into corneal pocket made by special automated microkeratome specifically developed for CISIS. The pocket maker (Dioptex GmbH) proven to be safe, effective for treatment of moderate to high myopia as alternative to LASIK or intraocular lens implantation surgery and also applied for treatment of KC⁽¹⁵⁾.

The mechanism of action of CISIS is the same as other intra corneal ring segment; by adding volume to the peripheral cornea through implantation of Myring into circular corneal tunnel leads to a new biomechanical equilibrium of the cornea by displacement of local anterior surface forward at this area and flattening of the central portion of the anterior cornea (arc shortening effect) of corneal lamellae in accordance to Barraquer's thickness law which describe the central corneal flattening with addition of material to peripheral cornea⁽¹⁶⁻¹⁹⁾. Keratoconic cornea flattened more easily than normal cornea as relatively this tissue is more flaccid⁽²⁰⁾.

CISIS generate a closed pocket by cutting only parallel to the direction of the collagen fibrils, in contrast to LASIK; corneal biomechanical stability remains unaffected²¹. It can be combined with intra pocket corneal collagen cross linking in a single session procedure to avoid the need of epithelial debridement⁽²²⁾.

The aim of this study is to assess visual and refractive outcomes after simultaneous Myring implantation and intra pocket collagen cross linking in patients with KC.

PATIENTS AND METHODS:

A total 40 eyes for 34 patients with age range 20-35 years all cases were diagnosed to have KC by clinical slit lamp examination and Sirius corneal topography.

Inclusion criteria:

No corneal scar, no history of ocular surgery, minimal corneal thickness $\geq 360\mu\text{m}$ measured by ultrasonic pachymetry (Tomey SP-100), UDVA not better than 0.3 LogMAR and keratometry (K) reading >42.00 diopters (D) using the following formula $K=(K1+K2)/2$.

Pupil size was not considered in inclusion criteria. Informed consent obtained from the patients after explanation of all possible options of KC treatment and the need to exchange or reposition the ring.

In addition to keratometry (measured by Sirius topography), outcome measures include UDVA, CDVA, spherical and cylindrical component of manifest refraction, and spherical equivalent (SE). Lines of improvement were calculated in logarithmic scales according to Log MAR notation. In all cases, CDVA is reported with spectacle correction. All these parameters measured at 1 month, 6 months and 1 year.

METHODS:

Myring is a flexible continuous PMMA ring that inserted in a pocket via small tunnel it available in diameter 5-8mm and thickness range from 200-400 μm in 20 μm increment, width of ring body 0.5 mm. Anterior surface convex, posterior surface is concave with radius of curvature 8mm this particular shape and dimension permit folding which make implantation in the pocket feasible via small incision, there is available nomogram for implantation that derived from theoretical calculation based on biomechanical corneal model developed according to experimental data, this nomogram considered the corneal thickness at the thinnest point and mean central k reading. According to the nomogram a particular ICCR dimension cover wide range of K reading and therefore specific severity range of the disease. Table 1 shows the current nomogram provided by the manufacturer (Dioptex GmbH, Linz, AUSTRIA).

Table 1: Current nomogram

ICCR Dimension		
ACK	Diameter(mm)	Thickness(μm)
<48D	6	240
48<ACK>52	6	280
52<ACK>55	5	280
55<ACK	5	320
ACK : $k1+k2/2$, k = keratometry, ICCR= intracorneal continuous ring		

Surgical procedure:

The surgery was done under topical anesthesia by the same surgeon.

The procedure can be summarized in 4 steps:

1st step: Creation of corneal pocket within the stroma by automated pocket maker microkeratome, the diameter of pocket 9mm, depth of 300mm. Except for a 3mm wide and 2mm long incision tunnel which located in temporal periphery of the cornea the pocket is closed along the entire circumference .The incision is selfsealing and requires no suturing.

2nd step: Continuous irrigation of the pocket with a sterile standard dose of riboflavin(0.1 %riboflavin in 3 ml of 20% dextran 500 solution) for 3 minutes via standard canula of 0.3- mm diameter through the incision tunnel .

3rd step: The cornea was subjected to a 4 minutes irradiation treatment with UV-A light of 365nm (Peschke Meditrade GmbH, Clemont –Ferrand Switzerland) and UV intensity of 9 mW/cm².

4th step: Within 5minutes after UV-A irradiation, a flexible Myoring implanted into the pocket through the small incision tunnel, centration of the ring within the pocket by forceps only.

Topical antibiotic- steroid eye drops prescribed four times daily for 1week postoperatively. Examination of the patient done at 1st day post operatively ,1wk , 1month ,3month, 6month and 1year

Statistical analysis:

Statistical data are presented as mean ±SD and K reading is from the 3.00mm zone .All the preoperative data compared with postoperative data taken at 1month,6months, 12 months by One -way ANOVA analysis using Minitab 13, then the preoperative and 1 year postoperative data were statistically compared using paired t-test .The change in data considered statistically significant when the p value was less than 0.05.The UDVA and CDVA were obtained in decimal scaling and transformed into LogMAR for statistical analysis.

RESULTS:

Of 40 eyes that had simultaneous ICCR and CXL ,1 required downward shifting of the ring by 0.5mm which showed improvement in UDVA from 0.01(2.0 LogMAR) to 0.25(0.6 LogMAR),the CDVA from 0.2 (0.7LogMAR) to 0.33(0.48 LogMAR) and K reading from 36.36 to 39.23D.

The mean age of the patients was 25.75ys ±7.06 range from 20-35ys. The preoperative pachymetry at the thinnest point of the cornea with range of (367-555 μm).Table 2 shows preoperative and postoperative visual and refractive data. There was statistically significant improvement in all parameters from preoperatively to postoperatively p value was 0.000. Figures 1 to 6 shows changes in these parameters over time. At 1 year, the mean UDVA improved by 13 lines, from less than 0.03(1.66 ±0.45LogMAR) to better than 0.50 (0.23± 0.09 LogMAR), the mean CDVA improved by 3.5 lines, from 0.32 (0.52 ± 0.46 LogMAR) to better than 0.63(0.14 ± 0.07LogMAR), the mean K improved by 7.14 D, the mean preoperative sphere reduced by -5.90 D while the mean cylinder by -4.09D and the mean spherical equivalent reduced by -7.93D. No eyes lost lines of CDVA or UDVA postoperatively. The cornea was hazy in early postoperative phase the turbidity of the cornea appeared evenly distributed over the entire corneal thickness and treated diameter with a slightly higher density in the anterior cornea after 1 month the haze was almost completely resolved.

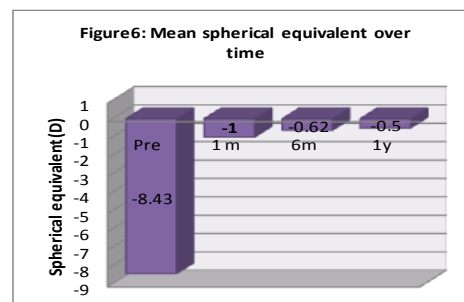
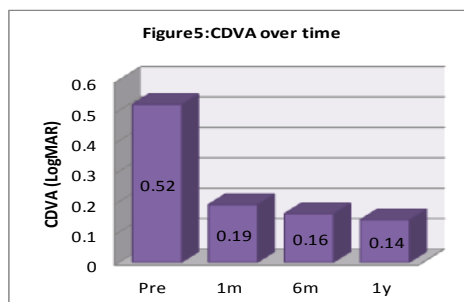
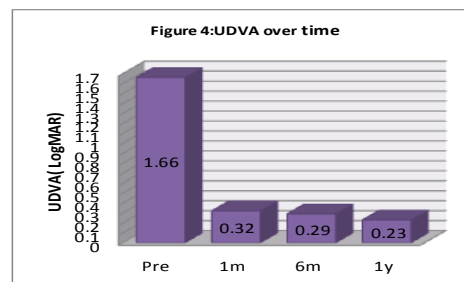


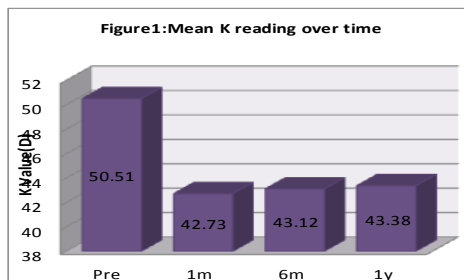
There were no postoperative complications .Patients reported side effects more frequently in the early postoperative period than in the late postoperative period .Glare and night vision problems were reported in 2 eyes .These eyes received pilocarpine 1% eyedrop therapy for 3 months within the first postoperative year. No ICCR was removed for side effects or complications.

TREATMENT OF KERATOCONUS

Table 2: The pre-and postoperative visual and refractive data (Mean± SD).

Sphere(D)±SD	cylinder(D) ±SD	SE (D)±SD	UDVA±SD	CDVA±SD	K(D)±SD	
Preoperative	-6.09 ±3.49	-4.69± 2.21	-8.43±3.59	1.66±0.45	0.52±0.46	50.51±3.94
1month Postop	-0.55±1.31	-0.91±1.66	-1.00± 1.77	0.32±0.15	0.19±0.13	42.73±2.47
6months postop	-0.29±0.70	-0.67±1.13	-0.62±1.05	0.29±0.10	0.16±0.08	43.12±2.49
1 year postop	-0.19± 0.47	-0.61±0.92	-0.50±0.74	0.23±0.09	0.14±0.07	43.38 ±2.4

SE=spherical equivalent; UDVA=uncorrected distance visual acuity; CDVA= corrected distance visual acuity; K=keratometry ; postop=postoperatively



DISCUSSION:

As seen from clinical data, ICCR implantation in keratoconus has potential to correct significant myopic as well as astigmatic refractive errors, improve UDVA, CDVA and significantly reduce K reading.

ICCR allows individualized treatment of keratoconus based on control of ring thickness, ring diameter and centration .The smaller diameter the bigger thickness the higher

corrective effect that achieved ⁽²²⁾ .The limiting factor may be the pupil size but this is less important than in treatment of high myopia for that we didn't consider it within inclusion criteria.

As the shape of the cornea in advance keratoconus is highly irregular, there is no existing theory or method to predict the optimal position in a given case preoperatively, therefore

we consider an adjustment in the position of implant after its insertion to achieve optimal results⁽²²⁾.

In our cases we aimed to center the Myring on the pupil. In some case the impression of centration under surgical microscope may be wrong and ICCR appear decentered on slit lamp in such case recenteration required as occurred in 1 of 40 eyes.

The decision of whether recenteration is required can be made by analyzing the tangential topographic map done 1wk after surgery. If ICCR appears concentric around fairly regular center on tangential map no intervention required, other indication of active surgical decentration is to achieve a sufficient refractive result this can happened when ICCR well centered but central cornea is very irregular.

During the 1st postoperative year we notice continuous improvement in UDVA and CDVA the explanation may be adaptation to ICCR diameter of 5mm this adaptation also reduce the incidence of side effects as glare and night vision problems. This explanation corresponds well with observation that the patient subjectively reports improvement in vision overtime as well as reduction in side effects that correspond to the improvement in vision.

Advantages of the procedure:

One of the advantages is that a minimum corneal thickness as less as 360 μm can safely treated and one patient with this corneal thickness included in our study. As the thinnest area of the cornea is involved in the formation of the pocket, the cutting depth of 300 μm allows a keratoconic cornea with minimum of 360 μm to be safely treated. Due to transcorneal pressure implant trapped between anterior and posterior lamellae so that displacement of implant cannot occur without surgical intervention⁽²³⁾. There is no reported extrusion case as the ring totally in the pocket and no free end.

By combination of Myring implantation with collagen cross linking we got benefit of visual improvement due to corneal remodeling by ring implantation while stopping the progression by intra pocket collagen cross linking. Riboflavin irrigation within 300 mm depth reduces the required total UV-A energy transfer to the cornea to about 2.1 J/cm² compared to 5.4J/cm² of the conventional epi-off technique. For this particular kind of treatment the UV-A exposure time can be significantly reduced according to the Daxer – Formula⁽²²⁾.

UV-A exposure time (minutes) = $36/\text{UV-A intensity (mW/cm}^2)$

Intra pocket riboflavin grants that 400 μm limit for cross linking is not violated even in patient with pachymetry as less as 360 μm ⁽²⁴⁾. And by preservation of the epithelium no postoperative pain and short recovery time.

Another advantage for the ICCR over other ring types is that the ICCR effect independent on the location and the type of the cone, with simple nomogram in which keratoconus is graded using the K readings only; while for ring segment the implant has chosen in number 1 or 2, segment arc length and implant positioning within the cone according to the type and location of the cone to provide better long term stability⁽²⁵⁻²⁶⁾.

Previous studies that support the efficacy of Myring implantation in KC that done without CXL: Daxer et al found that the UDVA improved by 10 lines, the mean CDVA improved by 3 lines and the mean K decreased by 5.76D⁽²⁷⁾.

Jabbarvaned et al. described one month after Myring implantation, an improvement of mean UDVA from 1.17 LogMAR to 0.66 LogMAR, mean CDVA from 0.85 LogMAR to 0.51 LogMAR, mean K from 51.90D to 45.00D, mean sphere from -5.48D to -0.08 D and mean cylinder from -5.30D to -2.21D⁽²⁸⁾.

Authors presented one case report for combined Myring implantation with intrapocket CXL with a very good result, UDVA increased by 7 lines and the average central K reading decreased by 11diopters⁽²⁹⁾.

A recent study on simultaneous surgery shows that mean UDVA improved by 6 lines from preoperative data, the mean CDVA improved by 2.5 lines mean K improved by 3.94D with statistically significant reduction of sphere, cylinder and spherical equivalent⁽³⁰⁾.

In our work we evaluated 1 year results of this simultaneous procedure in 40 eyes with keratoconus One month postoperatively we noticed improvement in all visual and refractive parameters and we noticed further improvement of mean UDVA ,CDVA, Sphere(D),cylinder(D) and SE(D) between 1month to 1 year after surgery. Improvement was highly statistically significant for all the measured data p value=0.000.

Conclusions: Treatment of KC with simultaneous ICCR implantation and intrapocket collagen cross linking significantly improved visual and refractive outcomes .The UDVA and CDVA continuously improved during the 1st year postoperatively.

TREATMENT OF KERATOCONUS

Recommendations: This study shows that the simultaneous ICCR implantation with intrapocket collagen cross linking was effective in improving all the measured preoperative parameters but in future we need to evaluate the results in larger sample of patients and for longer duration of follow up.

REFERENCES:

1. Dawson DG, et al , biomechanical and wound healing characteristics of corneas after excimer laser photorefractive surgery: is there a difference between advanced surface ablation and sub-Bowman keratomileusis? *J Refract Surg*2008;24:S90-6.
2. Caporossi A ,Baiocchi S,Mazzotta C,Traversi C,Caporossi T.Para surgical therapy for keratoconus by riboflavin – ultraviolet type A rays induced cross – linking of corneal collagen ;preliminary refractive result in an Italian study .*J Cataract Refract Surg*.2006;32:837-45.
3. Adel Barbara, Lamis Abdelaziz, Ramez Barbara. Intacs Intracorneal Ring Segments (ICRS) and Keratoconus. Textbook on keratoconus by Adel Barbara, Yaron S Rabinowitz . Section 3 ,ch. 15.First Edition 2012.
4. Chann CC, Sharma M, Wachler BS .Effect of implantation of inferior segment Intacs with and without C3R on keratoconus .*J Cataract Refract Surg*. 2007;75-80.
5. Kamburoglu G, Ertan A. Intacs implantation with sequential collagen cross linking treatment in post lasik ectasia .*J Cataract Refract Surg*. 2008 ;24:S726-769.
6. Coskunseven E, Jankov MR II, Hafezi ,Atuns,Arslan E,Kymionis GD.Effect of treatment sequences in combined intrastromal rings and collagen cross linking for keratoconus .*J Cataract Refract Surg*. 2009;35:2084-91.
7. Vicente LL,Boxer Wachler BS. Factors that correlate with improvement in vision after combined Intacs and trans -epithelial corneal cross linking *Br J Ophthalmol* 2010; 94:1597-1601.
8. EL-Raggal TM. Sequential versus concurrent Keraring insertion and corneal collagen cross –linking for keratconus .*Br J Ophthalmol* 2011;95:37-41.
9. Kymionis GD, Karavitaki AE, Kounis GA, Portalion DM, YOO SH,Pallikaris IG .Management of pellucid marginal corneal degeneration with simultaneous customized photorefractive keratotomy and collagen cross linking .*J Cataract Refract Surg*.2009;35-1298-1301.
10. Kymionis GD, Kontadakis GA, Kounis GA, et al. Simultaneous topography guided PRK followed by collagen cross linking for keratoconus. *J Cataract Refract Surg* .2009;25: S 807-811.
11. Kanelopoulos AJ, Binder PS.Collagen Cross Linking (CCL) with sequential topography –guided PRK. a temporizing alternative to penetrating keratoplasty .*Cornea* 2007;26:891-95.
12. MK Kummelil ,MS Hemamalini, Ridhima Bhagali , Koushik Sargod,Somshekar Nagappa,Rohit Shetty, and Bhujang K Shetty .Toric implantable collamer lens for keratoconus. *Indian Journal of Ophthalmol*, Aug 2013;61:456 -60.
13. EL-Reggal TM, Adel Fattah AA. Sequential Intacs and Verisyse phakic intraocular lens for refractive improvement in keratoconic eyes . *J Cataract Refract Surg*. 2007;33:966-70.
14. Soosan Jacob ,MS,FRCS ,Dip NB, Amar Agarwal ,MS,FRCS ,FRCOphth; Keratoconus and keratectasia prevention ,diagnosis and treatment by Ming Wang MD, PhD, 2010; 135,ch.13.
15. Albert Daxer ,MD, PhD .Corneal intrastromal implantation surgery for moderate and high myopia .*J Cataract Refract Surg*. 2008;34:194-8.
16. Colin J, Cochner B,Savary G,Malet F. Correcting keratoconus with intracorneal ring .*J Cataract Refract Surg*.2000;26:1117-22.
17. Miranda D ,Sartori M,Franceconi C,Allemann N,Ferrara P,Campos M. Ferrara intrastromal corneal ring segments for sever keratoconus .*J Refract Surg*.2003;19:645-53.
18. Shabayek MH , Alio JL. Intrastromal corneal ring segment implantation by femtosecond laser for keratoconus correction. *Ophthalmology* .2007;114:1643-52.
19. Ertan A, Colin J. Intracorneal rings for keratoconus and keratectasia. *J Cataract Refract Surg* .2007;33: 1303-14.

TREATMENT OF KERATOCONUS

20. George O. Waring IV, MD, Jason E, Stah I, MD, Brian Boxer Wachler ; MD and William B. keratoconus and keratectasia prevention ,diagnosis and treatment by Ming Wang MD, PhD. 2010:161.
21. Ortiz D ,Pinero D, Shabayek MH, et al. Corneal biomechanical properties in normal ,post –laser in situ keratomileusis ,and keratoconic eyes. J Cataract Refract Surg 2007; 33:1371-75.
22. Albert Daxer, Lamis Abdelaziz, Ramiz Barbara .The Myring for the treatment of keratoconus .Text book on Keratoconus: New Insights by Adel Barbara. Section 3 , ch.17. First Edition 2012
23. Daxer A .Adjustable intracorneal ring in a lamellar pocket for keratoconus .J Refract Surg 2010; 26:217-21.
24. Jerome C.Vryghem ,MD, PhD,; Efehan Coskunseven, MD;Albert Daxer ,MD, PhD; A. John Kanellopoulos,MD; and Rudy M.M. A Nuijts , MD,PhD. Surgical visual rehabilitation technique. Cataract and Refractive Surgery TODAY EUROPE. April 2009.
25. Alio JL, Artola A, Hassanein A, Haroun H, Galal A. One or 2 Intacs segments for the correction of keratoconus .J Cataract Refract Surg 2005; 31: 943-53.
26. Sharma M,Boxer Wachler BS .Comparison of single –segment and double- segment Intacs for keratoconus and post –Lasik ectasia .Am J Ophthalmol 2006;141:891-95.
27. Albert Daxer, MD,PhD ,Haifa Mahmoud ,MD ,Rengaswamy Srinivasan Venkateswaran, OD. Intracorneal Continuous ring Implantation for Keratoconus: one –year follow up .J Cataract Refract Surg 2010;36: 1296-1302.
28. M.Jabbarvand ,A.Salamatrad , H.Hashemian ,M.Mazloumi, M.Khodaparast ,and A.Aldave , Continuous intracorneal ring implantation for keratoconus using femtosecond Laser ,Journal of Cataract and Refractive Surgery 2013;39:1081-87.
29. A.Daxer,H.A.Mahmoud ,and R.S. Venkateswaran, Corneal cross linking and visual rehabilitation in keratoconus in one session without epithelial debridement :new technique ,Cornea 2010;29:1176-79.
30. Pavel Studeny ,Deli Krizova ,and Zbynek Stranak.Clinical Outcomes after Complete Intracorneal Ring Implantation and Collagen Cross Linking in an Intrastromal Pocket in One Session for Keratoconus. Journal of Ophthalmology. 2014;Article ID 568128:5.