

Primary Intramuscular Hydatid Cyst of the Thigh Muscle in 20-Year-Old Female: A Rare Case Report

Abstract

Primary muscular hydatid cyst is rare and on clinical basis, it may resemble any soft tissue tumor. We present a case report of a 20 year-old Iraqi female patient who presented with a large progressively painful mass in the anteriomedial aspect of her left thigh. It was diagnosed clinically as a soft tissue sarcoma and was excised successfully. Histopathologic examination of the resected specimen confirmed the hydatid cyst. This case emphasizes the importance of considering hydatidosis in differential diagnosis of any soft tissue mass especially in endemic countries.

Keywords: Echinococcosis; Hydatid cyst; Muscle; Case report

Case Report

Volume 7 Issue 1 - 2017

Qays A Hassan^{1*}, Mohammed S Al-edani² and Zuhair B Kamal³

¹Section of Radiology, Department of Surgery, Al-kindy College of Medicine Baghdad University, Iraq

²Section of Orthopedics, Department of Surgery, Al-kindy College of Medicine Baghdad University, Iraq

³Department of Surgery, Al-kindy College of Medicine Baghdad University, Iraq

***Corresponding author:** Qays A Hassan, Section of Radiology, Department of Surgery, Al-kindy College of Medicine -Baghdad University, Baghdad, Iraq, Tel: 9647722604163; Email: qtimeme@yahoo.com

Received: November 25, 2016 | **Published:** January 17, 2017

Introduction

Hydatid cyst (HC) occurs because of infestation by the genus of Echinococcus. It is a global public health threat [1]. The greatest prevalence of hydatidosis in human and animal hosts is found in sheep raising countries, including Iraq [2]. Various parts of body may be involved with HC but the liver and lungs are the main locations [3]. Primary skeletal muscle infection is rare even in endemic regions and reported 1% - 4% of all cases of echinococcosis [4]. Patients with musculoskeletal HC are asymptomatic and present at an advanced stage of hydatidosis, when lesions have become extensive [3,4]. Here we report a case of this rare entity of an isolated HC of the muscle of the thigh which carry a diagnostic challenge.

Case Presentation

A 20-year-old female from Baghdad city with no significant past medical history presented with swelling of the anteromedial aspect of her left thigh that had been increasing in size for last two years and had become progressively more painful especially during hip movement. There was no history of trauma, fever, or weight loss. Physical examination demonstrated a firm, tender, non moveable, large mass of approximately 20 cm length in the anterior and medial aspects of the left thigh. Clinically the mass was suspected to be a soft tissue sarcoma. MRI demonstrates a large intramuscular mass within the adductor magnus muscle extended to the lateral wall of vagina with two cystic components (Figure 1). The radiologist reported that the lesion appearance was highly unusual for a soft tissue sarcoma and he revealed that atypical parasitic infections such as echinococcal infections can give this appearance. Chest radiograph and ultrasonography of the abdomen were normal and serological test for hydatid disease was negative.

On exploration under general anesthesia, two round cystic masses occupying the adductor magnus muscle were found. These cysts were excised (Figure 2). Histopathology showed soft cystic masses that contains gelatinous material. A diagnosis of HC of the muscle was reached and the patient was treated with albendazole postoperatively for 6 months.

Discussion

HC is a disease caused by Echinococcus Granulosis that has worldwide distribution and can cause high morbidity and mortality.

HC is most commonly found in the liver and lung, while they can occur in other organs including muscle, brain, eye, spleen, kidney, orbit, lymphatic glands, myocardium, tonsil, pancreas, skin, ovary, uterus and parotid glands [5,6]. Isolated primary hydatidosis of skeletal muscle is rare and has been reported in only 1-4% of all patients with hydatidosis and 2.3% of cases in endemic areas [7,8]. The muscle is not a favorable environment for larval growth because of the presence of lactic acid and mechanical factors, such as contractile activity which make encasement less likely [9]. The patient in our case had no further lesions that were detected other than the muscle cyst.

Preoperative diagnosis of muscular hydatidosis is difficult clinically and radiologically. Muscular HC is an insidious infection with no specific symptoms and it grows gradually and may mimic any soft tissue tumor such as abscess, chronic hematoma, synovial cyst, and necrotic malignant tumor. Thus, the diagnosis of soft-tissue HC needs a high index of suspicion.

The confirmation of the hydatid diagnosis is mandatory before surgical exploration and biopsy of the cyst to avoid leakage of cyst contents and the accompanying risks of anaphylaxis.

Radiological studies, including MRI, are the mainstay of the preoperative diagnosis of the skeletal muscle HC. In our case, the clinical primary impression was soft tissue sarcoma, but the radiologist put this possibility as a less likely and he raise the suspicion of HC as a diagnosis especially in our endemic country and this made the surgeon refrain from doing the diagnostic aspiration biopsy.

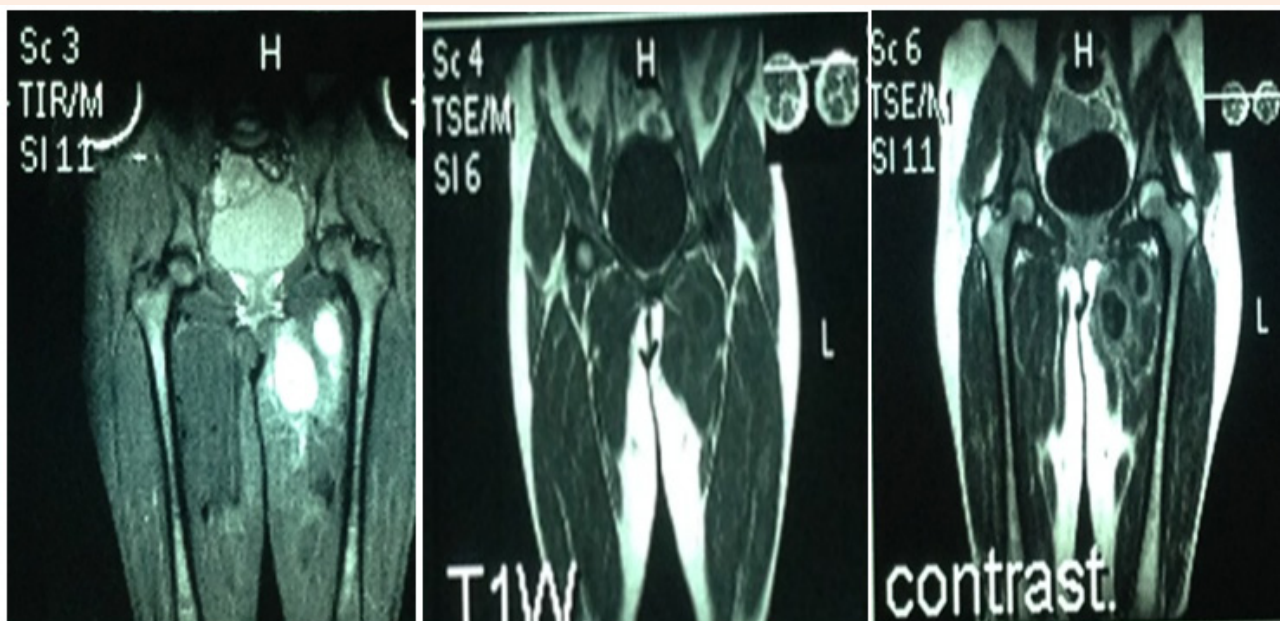


Figure 1: MRI demonstrated large intramuscular lesion with two cystic components within the left adductor magnus muscle.

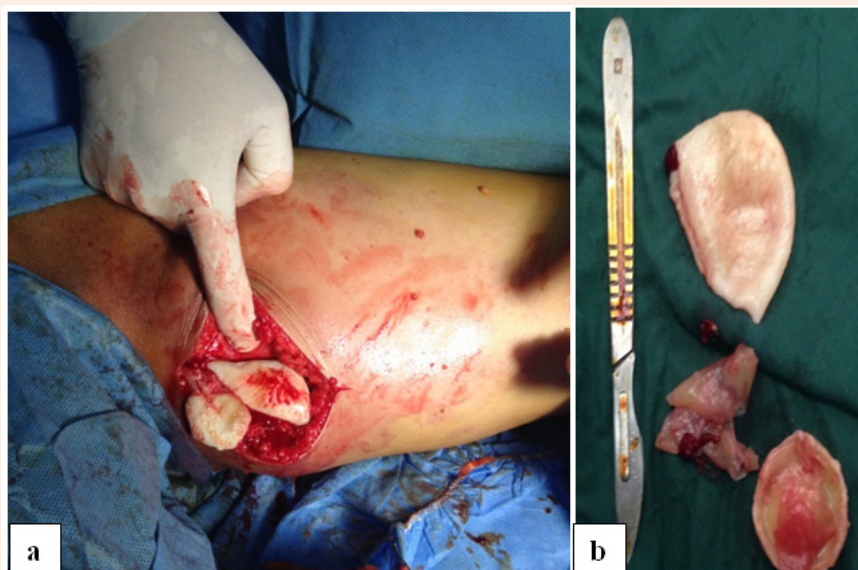


Figure 2a: Exploration gross photograph showing two masses within the adductor magnus muscle of left thigh with pearly white muscle free wall.

Figure 2b: Gross section photograph showing two pearly white translucent cysts with gelatinous material.

Although a variety of serological tests like latex agglutination and enzyme linked immunosorbent assay (ELISA) are used to establish the diagnosis and follow up of hydatid disease, but more than 70% of serologies were negative in a cohort of patients with musculoskeletal echinococcosis [10]. Unfortunately, the ELISA test was negative in our case.

Surgery is the treatment of choice for muscular HC and the best option for a complete cure. Chemotherapy with high-dose albendazole, mebendazole or praziquantel can be considered if the cyst is inoperable due to its location. Prevention is the key including education regarding the means of transmission. Personal hygiene and hand-washing is critical in rural areas

inhabited by dogs and livestock. Dogs should not be fed the viscera of slaughtered animals.

In conclusion, HC can present in any part of the body. The infestation may resemble a soft tissue tumor in the muscle and therefore in endemic area of hydatidosis, HC should be considered as differential diagnosis of any soft tissue mass.

References

1. Mandal S, Deb Mandal M (2012) Human cystic echinococcosis: Epidemiologic, zoonotic clinical, diagnostic and therapeutic aspects. *Asian Pacific J Trop Med* 5(4): 253-260.
2. Mousavi SR, Samsami M, Fallah M, Zirakzadeh H (2012) A retrospective survey of human hydatidosis based on hospital records during the period of 10 years. *J Parasitic Dis* 36(1): 7-9.
3. Metanat M, Sharifi-mood B, Sandoghi M, Alavi-Naini R (2008) Osseous hydatid disease. *Iran J Parasitol* 3: 60-64.
4. Uraiqat AA, Al-Awamleh A (2010) Hydatid cyst in the muscles: A case report. *JRMS* 17: 72-74.
5. Fakoor M, Marashi-Nejad S, Maraghi S (2006) Hydatidosis of tibia. *Pak J Med Sci* 22(4): 468-470.
6. Ghanaati H, Mohammadifar M, Ghajarzadeh M, Firouznia K, Motevalli M, et al (2011) Hydatid Cyst of the Knee: A Case Report. *Iran J Radiol* 8(3): 170-172.
7. Kumar S, Kumar S, Ramakanat P, Ahmad A, Ramakant (2008) Intramuscular Hydatid Cyst: A Rare Presentation. *The Internet Journal of Surgery* 16(1): 1-4.
8. Geramizadeh B (2013) Unusual locations of the hydatid cyst: A review from Iran. *Iran J Med Sci* 38(1): 2-14.
9. Karimi A, Asadi K, Mohseni F, Hossein Akbar M (2011) Hydatid cyst of the biceps femoris muscle (a rare case in orthopedic surgery). *Shiraz E Med J* 12(3): 150-154.
10. Gougoulas NE, Varitimidis SE, Bargiotas KA, Dovas TN, Karydakos G, et al. (2010) Skeletal muscle hydatid cysts presenting as soft tissue masses. *Hippokratia* 14(2): 126-130.