

Effect of Application of BMP2/TGF β 1 in Traumatic Pulp of Osteoporotic Rat

Abdulla MW Al-shamma¹, Athraa Y. Al-Hijazi^{2*}, Dhuha M Hasan³

¹Restorative department, College of Dentistry, University of Baghdad, Iraq

²Oral histology and biology, Al-Mustaqbal University College/ Dentistry Department, Babylon, Iraq.

³Preventive dentistry, Al-Mustaqbal University College/Dentistry Department, Babylon, Iraq

*Corresponding Author: Athraa Y. Al-Hijazi

E-mail: athraayms@yahoo.com

Article History:

Submitted: 10.04.2020

Revised: 14.05.2020

Accepted: 22.06.2020

ABSTRACT

Introduction: Dental pulp tissue contains many undifferentiated mesenchymal cells, which have the ability to differentiate into different specialized cells. Induced pluripotent stem cells have been developed by various growth factors. The present study was designed to evaluate the effect of application of a combination BMP2/TGF β 1 as capped material for traumatic pulp in osteoporotic rat.

Materials and Methods: Twelfth female rats (6 normal rat and other 6 osteoporotic rat), their maxillary anterior teeth subjected to mechanical traumatized pulptomy, the left tooth has speared without treatment, while the right tooth capped with application of 0.5 μ l of BMP2 and 0.5 μ l of TGF β 1. Evaluation of histological changes includes scoring of pulp inflammation and scoring of morphology and thickness of dentin bridge were estimated for all study groups.

Results: Histological examination of tooth with pulptomy capped by

BMP-2&TGF β 1 for both normal and osteoporotic rat showed formation of reparative dentin bridge and minimal inflammatory response with a significant differences value in comparison to control.

Conclusion: The study concludes that application of a combination of BMP-2&TGF β 1 enhanced tooth repair in osteoporotic rat.

Keywords: BMP-2, osteoporosis, pulptomy, reparative dentin, TGF β 1, tooth repair

Correspondence:

Athraa Y. Al – Hijazi

Oral Histology and Biology, Al – Mustaqbal University College, Dentistry Department, Babylon, Iraq

E-mail: athraayms@yahoo.com

DOI: [10.31838/srp.2020.6.111](https://doi.org/10.31838/srp.2020.6.111)

@Advanced Scientific Research. All rights reserved

INTRODUCTION

Growth factors and extracellular matrix molecules, that are expressed during tooth development, are re-expressed in dental tissues under pathological conditions such as caries and dental injuries. They are often act as bio-stimulus to the pulp cells which can be differentiated to odontoblast^{1,2}, or enhance progenitor cells to differentiate into odontoblast-like cells and produce a reparative dentin.^{3,4}

Direct pulp capping by bioactive molecules or seeding of these molecules in the pulp may stimulate the formation of reparative dentin and enhanced pulp mineralization.

Pulp-capping studies with different biological agents, including growth factors and extracellular matrix molecules, showed the formation of tertiary dentin (reparative dentin formation).^{5,6}

Osteoporosis, is a prevalent metabolic bone disorder with increased susceptibility to fractures. It is also, thought to delay or impair the regenerative response.^{7,8}

osteoporotic fractures remain challenging to treat. Among other risk factors, decreased expression of morphogenetic proteins has been identified in osteoporosis.^{9,10} Studies on osteoporotic animals show atrophy of the periodontal ligament (PDL) and that this atrophy was accompanied by a reduction in the pool of osteo-progenitor cells that associated with significantly slower extraction socket healing.^{11,12}

Bone morphogenetic proteins BMPs are group of bone-inducing growth factors that used to enhance osseous repair. Many studies have indicated that BMP promotes a proliferation and differentiation of dental pulp cells both in vitro and in vivo. Furthermore, BMP is used as a pulp capping agent, for its ability to induce the formation of reparative dentin. ^{13,14} It was concluded that TGF- β 1 could induce odontoblast differentiation and dentin formation and act as substrate for the progenitor cells to anchor and initiate the differentiation to odontoblast cells.^{15,16} The

present study was designed to find the effect of using a combination of BMP-2 and TGF β 1 as a new pulp capping material to enhance tooth healing in osteoporotic rats .

MATERIALS AND METHODS

Twelfth 8-week-old female Wistar Albino rats ,weighted 230-250 g have been enrolled in this study and according to ethical approval from the ethical committee of the Al-Mustaqbal University College (license No: 069220) authorized all of the experimental approaches. These animals were kept in the animal department of National Center of Drug Control and Research (Iraq) at a constant humidity and temperature of 23°C and according to the National Council's guide for the care of laboratory animals.

A combination of Bone morphogenic protein-2 and Transforming growth factor beta-1 factor were used as pulp capped material for maxillary anterior teeth of the normal and osteoporotic rats following the mechanical traumatized procedure. The control and experimental teeth have studied histologically (H&E stain) after 28 days postoperatively. Six teeth were enrolled from each of following groups.

Group 1: Normal rats with the pulptomy restored with resinous glass ionomer cement.

Group 2: Normal rats with pulptomy capped by application of BMP-2& TGF β 1.

Group 3: Induced osteoporotic rats with pulptomy restored with resinous glass ionomer cement.

Group 4: Induced osteoporotic rats with pulptomy capped by application of BMP-2&TGF β 1 .

Induction of osteoporosis

Six rats were induced for osteoporosis by bilateral ovariectomy, and after 2 weeks postoperatively ,the animals were received a systemic daily I.M injection of methylprednisolone hemi succinate (MPH) at dose (1 mg/kg) for 4 consecutive.

Operative procedure

After six weeks of ovariectomy, operative preparation was started. Before the pulptomy procedure, the experimental teeth were submitted to prophylaxis, and absolute isolation of the operative field was performed with a rubber dam. The tooth was washed with 0.2% chlorhexidine prior to cavity preparation. Then a classic class V cavity was prepared at the buccal aspect of the crown near the gingiva by using a sterile 0.8 mm slow-speed round diamond bur.

The depth of the cavity was approximately half the diameter of the bur. Each bur was changed after 2 cavity preparations. During the preparation, the cutting area was irrigated with copious saline solution (0.9% NaCl) to prevent heat generation. Then pulp exposure were induced using dental explorer in the middle point of the cavity (Shayegan et al, 2012).¹⁷

Pulpal bleeding was controlled by pressing with a sterile saline-soaked cotton pellet and paper points. The left tooth was considered a control, represented the group 1&3 and only a cotton pellet was inserted over the exposed pulp tissue and the cavity was restored with resinous glass ionomer cement (Vitremmer, 3M ESPE, St. Paul, Minn., USA). The right tooth was considered an experimental, represented the group 2&4 with application of 0.5 μ l of BMP2 (rhBMP-2) Medtronic Sofamor Danek, TN/USA and 0.5 μ l of TGF β 1 (ab50036, Abcam) was placed in the pulp chamber using micro-pipette, allowed for one minute then restored, as previously described.

Histological Examination

At 28 days after direct pulp capping, the animals were sacrificed by an overdose of carbon dioxide gas. The whole maxilla was collected and fixed in 10% neutral buffered formalin for 24 hours at room temperature, and demineralized in 20% formic acid for 3 days. Then, the maxilla was sectioned carrying two anterior teeth, washed in running tap water overnight, dehydrated through ascending concentrations of ethanol, and embedded in paraffin blocks. The 5- μ m thick serial sections were cut through the incisor area in the mesio-distal direction using a sliding microtome (RM2255, Leica Biosystems, Wetzlar, Germany) to include the entire pulp chamber and the exposed area. The slides were numbered, and the sections were stained with hematoxylin and eosin to evaluate the pulp tissue response and reparative dentin formation.

The stained sections were blindly evaluated by a trained investigator who was previously calibrated with an experienced pathologist. Under a light microscope (Olympus BX53, Olympus, Tokyo, Japan), all samples were evaluated and scored in terms of: 1) inflammatory cell infiltration, 2) reparative dentin formation, According to Mestrenner et al (2003)¹⁸, the quantitation of intensity of inflammatory response and the thickness of dentine bridge were evaluated by counting them in visual field (X10, X20, X40) with subsequent of arithmetic mean for each specimen as follow:

Intensity of inflammatory reaction

- I. Absent or very few inflammatory cell.
- II. Mild average number less than 10 inflammatory cells.

III. Moderate average number 10-25 inflammatory cells.

IV. Severe average number greater than 25 or necrosis.

Thickness of Dentine Bridge

I. Up to 250 μ m.

II. 150- 249 μ m.

III. 1-149 μ m.

IV. Partial or absent bridge

STATISTICAL ANALYSIS

All records were entered into Excel spread sheets for evaluation with PASW statistics for windows, version 18.0. Statistical evaluation was executed using the SPSS (Statistical package deal for Social studies, Chicago, IL, united states of America).

Descriptive statistics

1. Means
2. Frequency
3. Percentage

Inferential statistics

1. Chi square: to compare the scores of inflammatory response and thickness of dentin bridge between groups of teeth.
2. Likelihood ratio test: used as alternative to Chi square when the expected frequency is less than 1 in any cell or less than 5 in 20% of the cells.

RESULTS

Results for histological examination revealed that dentine-pulp interface for normal rats with pulptomy at 28th day showed thin layer of reparative dentin with inflammatory cells in sub odontoblastic area, while the view was differed for pulptomy capped with BMP-2&TGF β 1, the reparative dentin was regular and mostly score II in thickness and dentin bridge formation was observed. Pulp shows odontoblast like cells occupy its surface as flat cell with odontoblastic process extend in dentin. Calcospherite is detected as mineralized globules in reparative dentin, figure 1.

Histological examination for osteoporotic rats with pulptomy at 28th day showed internal dentin resorption with identification of odontoclast cells as multinucleated giant cell occupied the how ship's lacunae, the pulp shows fibrosis with fibroblast subside in dental pulp tissue and infiltration of inflammatory cells. Furthermore, Pulp shows a necrosis, with no evidence of reparative dentin formation.

Histological features for osteoporotic rats with pulptomy capped with BMP-2&TGF β 1 at 28th day showed a formation of irregular reparative dentin with dentin bridge while pulp revealed an active new blood vessels with presences of inflammatory mononuclear cell infiltrated pulp tissue, figure 2.

Statistical results

Statistical analysis revealed a significant difference in frequency and percentage of inflammatory response, and the scoring of reparative dentin bridge thickness (μ m) for the normal and osteoporotic with pulptomy capped by a combination of BMP2&TGF- β 1 in comparison to control, tables (1,2).

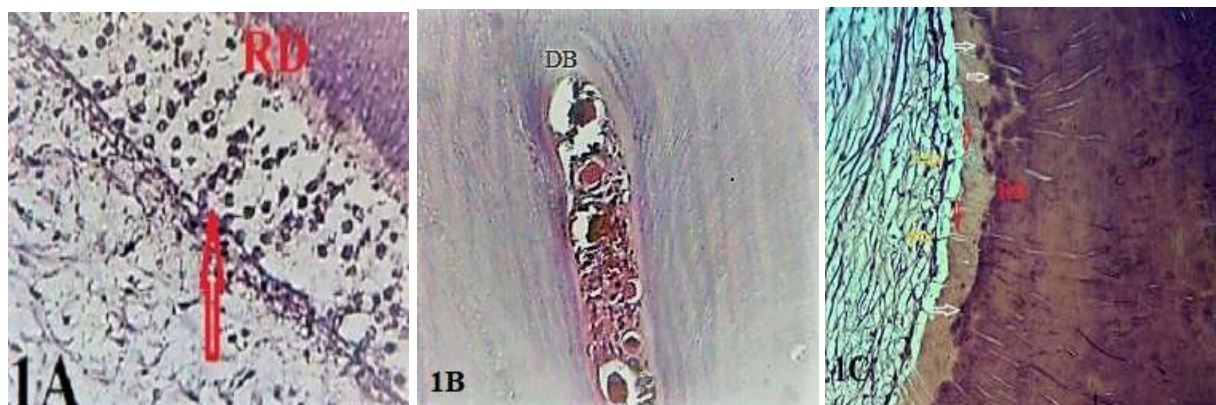


Figure 1: Histological description for dentin-pulp interface for normal rats with pulptomy (untreated and treated) at 28th day

- 1A: dentin-pulp interface for normal rats with pulptomy shows thin layer of reparative dentin (RD), inflammatory cells in subodontoblastic area (arrow).H&Ex10
 1B: Formation of dentin bridge (DB) for normal rats with pulptomy treated with BMP-2&TGF β 1 .H&Ex4
 1C: View for shows reparative dentin (RD), odontoblast like cell (yellow arrows), odontoblast process (red arrows), calcospherite (white arrows) in normal rat with treated pulptomy.H&Ex40

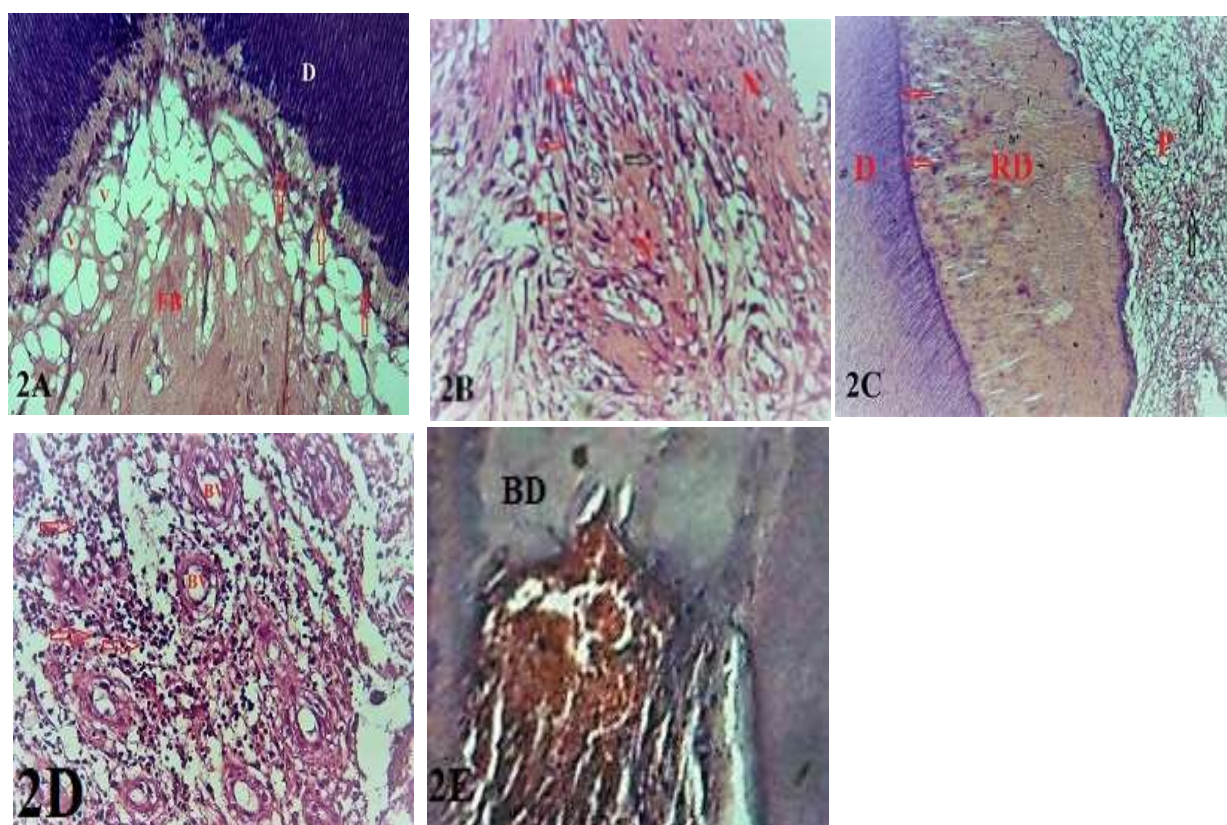


Figure 2: Histological description for dentin-pulp interface for osteoporotic rats with pulptomy (untreated and treated) at 28th day

- 2A: dentin-pulp interface for osteoporotic rats shows internal resorption with odontoclast (arrows), pulp illustrates fibrosis (FB). H&Ex20; 2B: Magnifying view for the pulp shows fibrosis (FB), necrosis (N), fibroblast (red arrows), inflammatory cells (black arrows). H&Ex40; 2C: dentin-pulp interface for osteoporotic rats with pulptomy treated with BMP-2&TGF β 1 shows dentin (D), reparative dentin (RD), demarcated line (red arrows), pulp (P) with inflammatory cells (black arrows). H&Ex10; 2D: Magnifying view for the pulp shows active new blood vessels formation (BV), mononuclear cells infiltration (arrows).H&Ex20; 2E: Formation of dentine bridge (DB). H&Ex10

Table 1: Frequency and percentage of inflammatory response in different groups

Non Sig. at P> 0.0

groups	inflammatory score				X2	Likelihood ratio	d.f.	P-value
	I	II	III	IV				
Normal	2 (16.7%)	2 (16.7%)	1 (8.3%)	1 (8.3%)	10	12.77	3	0.02 (S)
Normal BMP2&TGF β 1	5 (41.7%)	1 (8.3%)	0 (0%)	0 (0%)				
Osteoporosis	0 (0%)	1 (8.3)	2 (16.7%)	3 (25%)	7.9	10.9	3	0.001 (HS)
Osteoporosis BMP2& TGF β 1	2 (16.7%)	2 (16.7)	2 (16.7%)	0 (0%)				

Table 2: Reparative dentin bridge score in different groups

Non Sig. at P> 0.0

groups	Dentin bridge score				X2	Likelihood ratio	d.f.	P-value
	I	II	III	IV				
Normal	0 (0%)	0 (0%)	3 (25%)	3 (25%)	9	11.98	3	0.006 (HS)
Normal BMP2&TGF β 1	2 (16.7%)	3 (25%)	1 (8.3%)	0 (0%)				
Osteoporosis	0 (0%)	0 (0%)	2 (16.7%)	4 (33.3%)	6.9	8.95	3	0.03 (S)
Osteoporosis BMP2&TGF β 1	1 (8.3%)	2 (16.7%)	3 (25%)	0 (0%)				

DISCUSSION

The present study shows that application of a combination of BMP-2 and TGF- β 1 as capped material for pulptomy induce new differentiation of mesenchymal cells into odontoblast like cell that apposed reparative bridge dentin with process of mineralization that appeared a calcospherite in both normal and osteoporotic rats.

Mineralization of dental pulp was increased by TGF- β 1 induction and increased the ALP activity of dental pulp cells as well as expression of dentin sialoprotein (DSP), osteopontin (OPN) and type I collagen.^{19,20} Our results coincide with different studies that shows the effect of using TGF- β 1 as stimulator for odontoblast cell differentiation and then apposition of reparative dentin. Many in vitro and in vivo studies illustrated the inductive potential of scaffold material combing with TGF β 1 to induce odontoblast differentiation and dentin formation from dental pulp cells.^{21,22,23}

Other studies found that BMP-2 provides a strong signal for differentiation and mineralization of odontoblasts and osteoblasts and an over expression of BMP2 can promote fracture healing and osteogenic ability in senile osteoporotic fractures through activating the BMP/Smad signaling pathway.^{24,25}

Animal studies related to post-menopausal estrogen deficient osteoporosis had shown healing to be prolonged with decreased levels of mesenchymal stem cells (MSCs) and

decreased levels of angiogenesis^{26,27,28}, while in our study the application of combination of BMP-2& TGF β 1 illustrates that many events has been affected including the recruitment and differentiation of (MSCs) to odontoblast like cell during the early phase; and angiogenesis with new blood vessels formation during pulp healing ; and finally formation of a reparative dentin.

CONCLUSIONS

The present findings implied that application of combination of BMP-2& TGF β 1 in direct pulp capping for osteoporotic pulp healing, act as inductive agent that initiates the differentiation of odontoblast like cell and formation of dentin bridge and could be taken into consideration when designing capping material for inducing dentin tissue engineering. Further researchers should focus on this important topic and provide more data in this field in order to enable a sound clinical use of these materials in osteoporotic subjects.

ETHICAL CLEARANCE

all work of this study had done according to the National Council's guide for the care of laboratory animals.

CONFLICT OF INTEREST

The authors declare that they have no conflict of interest

FUNDING

Self- funding

REFERENCES

- About, I and Mitsiadis, TA. Molecular aspects of tooth pathogenesis and repair: in vivo and in vitro models. *Adv Dent Res* 2001;15:59-62.
- Umamura, N., Ohkoshi, E., Tajima, M, et al. Hyaluronan induces odontoblastic differentiation of dental pulp stem cells via CD44. *Stem Cell Res Ther* 2016; 7(1):135.
- Zhang, W., Walboomers, XF., Jansen, JA. The formation of tertiary dentin after pulp capping with a calcium phosphate cement, loaded with PLGA microparticles containing TGF- β 1. *J Biomed Mater Res A*.2008; 85(2):439-44.
- Al-Hijazi A., Ali, M., Hasan, D., Al-shamma, A. Pulp Response Capped by Brain Derived Neurotrophic Factor (BDNF). *Ind. J. of Pub. Heal. Res. & Dev* 2019;10(1),337-340.
- Tziafas, D. The future role of a molecular approach to pulp-dentinal regeneration. *Caries Res*. 2004;38(3):314-20.
- Goldberg, M., Six, N., Decup, F. et al. Bioactive molecules and the future of pulp therapy. *Am J Dent*.2003; 16(1):66-76.
- Mathavan N, Turunen MJ, Guizar-Sicairos M, et al. The compositional and nano-structural basis of fracture healing in healthy and osteoporotic bone. *Sci Rep* 2018 Jan 25;8(1):1591.
- Van Lieshout EM, Alt V. Bone graft substitutes and bone morphogenetic proteins for osteoporotic fractures: what is the evidence? *Injury* 2016 Jan;47 Suppl 1:S43-6.
- Chen CH, Wang L, Serdar Tulu U, Arioka M, Moghim MM, Salmon B, Chen CT, Hoffmann W, Gilgenbach J, Brunski JB, Helms JA. An osteopenic/osteoporotic phenotype delays alveolar bone repair. *Bone*. 2018 Jul;112:212-219.
- Iizuka T, Miller SC, Marks SC. Alveolar bone remodeling after tooth extraction in normal and osteoporotic (ia) rats. *Jr. J Oral Pathol Med* 1992 Apr; 21(4):150-5.
- Arioka M, Zhang X, Li Z. et al. Osteoporotic Changes in the Periodontium Impair Alveolar Bone Healing. *J Dent Res* 2019 Apr; 98(4):450-458. Epub 2019 Jan 9.
- Bykova NI, Sirak SV, Kobylkina TL, et al. [Optimization of reparative dentinogenesis in experimental osteoporosis]. *Stomatologiya (Mosk)* 2017;96(6):4-8.
- Gao, Y., Fang, YR, Suwa, F., et al. Induction of reparative dentin formation in dogs by bovine bone morphogenetic protein bound to ceramic dentin. *J Osaka Dent Univ*. 1995;29(1):29-38.
- Goldberg, M., Lacerda-Pinheiro, S., Jegat, N., et al. The impact of bioactive molecules to stimulate tooth repair and regeneration as part of restorative dentistry. *Dent Clin North Am*. 2006; 50(2):277-98.
- Li, F., Liu, X., Zhao, S. et al. Porous chitosan bilayer membrane containing TGF- β 1 loaded microspheres for pulp capping and reparative dentin formation in a dog model. *Dent Mater* 2014; 30(2):172-81.
- Luiz de Oliveira da Rosa, W., Machado da Silva, T., Fernando Demarco, F., et al. Could the application of bioactive molecules improve vital pulp therapy success? A systematic review. *J Biomed Mater Res A*.2017; 105(3):941-956.
- Shayegan A1, Jurysta C, Atash R, et al. Biodentine used as a pulp-capping agent in primary pig teeth. *Dent*. 2012 Nov-Dec;34(7):e202-8.
- Mestrener, SR., Holland, R., Dezan, E. Influence of age on the behavior of dental pulp of dog teeth capping of adhesive system. *Dental Traumatology* 2003;19(5):255-61.
- Liu, J., Jin, T., Chang, S., et al. Matrix and TGF- β 1-related gene expression during human dental pulp stem cell (DPSC) mineralization. *In Vitro Cell Dev Biol Anim*.2007; 43(3-4):120-8.
- Li, Y., Lü, X., Sun, X., et al. Odontoblast like cell differentiation and dentin formation induced with TGF- β 1. *Arch Oral Biol*. 2011;56(11):1221-9.
- Nie, X, Jin, Y. Induction of transforming growth factor- β 1 and dentin non-collagen proteins on tissue engineering pulp. *Zhongguo Xiu Fu Chong Jian Wai Ke Za Zhang* CY. Zhi 2004;18(2):115-8.
- Laurent, P., Camps, J., About, I. Biodentine(TM) induces TGF- β 1 release from human pulp cells and early dental pulp mineralization. *Int Endod J*.2012; 45(5):439-48.
- AbdulSahib, N., Al-Dahan, Z., Al-Hijazi, A. Expression of TGF β 1 by Pulp Tissue of Human Permanent and Primary Teeth Capped by Biodentine™. *J. of Nat. Sci. Res*.2015;15(10):21-25.
- Cho, YD., Yoon, WJ., Woo, KM., et al. The canonical BMP signaling pathway plays a crucial part in stimulation of dentin sialoprotein expression by BMP-2. *J Biol Chem*. 2010;285(47):36369-76.
- Ariffin, SH., Manogaran, T., Abidin, IZ., et al. A Perspective on Stem Cells as Biological Systems that Produce Differentiated Osteoblasts and Odontoblasts. *Curr Stem Cell Res Ther*.2017;12(3):247-259.
- Cheung WH, Miclau T, Chow SK, Yang FF, Alt V. Fracture healing in osteoporotic bone. *Injury*.2016;47 Suppl 2:S21-6.
- Huang K, Wu G, Zou J, Peng S. Combination therapy with BMP-2 and psoralen enhances fracture healing in ovariectomized mice. *Exp. Ther. Med*. 2018;16(3):1655-1662.
- Wu, J., Wang, Q., Han, Q., Zhu, H., Li, M., Fang, Y., Wang, X. (2019) Effects of Nel-like molecule-1 and bone morphogenetic protein 2 combination on rat pulp repair. *J Mol Histol*. 2019;50(3):253-261.