



Research Article

The Effectiveness of Autogenous Dentin Graft as a Biomaterial in Optimizing the Esthetic Outcomes of Immediate Dental Implants: A Prospective Clinical Study

Ikhlas Abd Dkheel , Ahmed Fadhel Al-Quisi* 

Department of Oral and Maxillofacial Surgery, College of Dentistry, University of Baghdad, Baghdad, Iraq

Received: 19 September 2023; Revised: 22 October 2023; Accepted: 30 October 2023

Abstract

Background: Immediate implant placement in the maxillary anterior region was challenging, especially with the jumping gap and limited primary implant stability. **Objective:** To assess the autogenous dentin graft biomaterial's ability to improve the esthetic outcomes of an immediately inserted implant. **Methods:** Twenty patients with non-restorable retained roots in the maxillary non-molar region surrounded by natural sound teeth were included in this study after a complete clinical and radiological examination, including patient health and clinical fitness for the immediate dental implant procedure. A single dental implant was inserted for each patient, and the resulting jump distance was filled with the mineralized dentin graft and covered by gel foam with the figure of eight suturing. The Pink Esthetic Score index of the implant-supported prostheses was evaluated six months after the initial surgery. **Results:** Twenty eligible patients were included in this study. The assessment of the clinical measurements of the alveolar ridge width and gingival biotype before surgical intervention and after 6 months showed no significant differences between them. The mean Pink Esthetic Score (PES) was 7.75. Only two patients achieved a total esthetic score of 10; another three patients had a score of 8, four with a score of 7, and the rest with a score of 6. **Conclusion:** An autogenous dentine graft effectively achieves acceptable esthetic results with an isolated immediate dental implant inserted in the anterior maxillary area.

Keywords: Autogenous dentine graft, Esthetic zone, Immediate implant, Pink Esthetic Score.

فعالية طعم العاج الذاتي كمادة حيوية في تحسين النتائج الجمالية لزراعة الأسنان الفورية: دراسة سريرية مستقبلية

الخلاصة

الخلفية: كان وضع الزرع الفوري في المنطقة الأمامية للفك العلوي أمراً صعباً، خاصة مع فجوة القفز واستقرار الغرسة الأولية المحدود. **الهدف:** تقييم قدرة المادة الحيوية لطعم العاج الذاتي على تحسين النتائج الجمالية لزراعة الأسنان الفوري. **الطريقة:** أجريت الدراسة على عشرين مريضاً لديهم جذور محتفظ بها غير قابلة للترميم في المنطقة الفكية غير المولية المحاطة بأسنان سليمة طبيعية بعد فحص سريري وإشعاعي كامل، بما في ذلك صحة المريض واللياقة السريرية لإجراء زراعة الأسنان الفورية. تم إدخال زرع أسنان واحدة لكل مريض، وتم ملء مسافة القفز الناتجة بطعم العاج المعدني ومغطاة برغوة هلامية مع الخياطة على شكل ثمانية. تم تقييم مؤشر النتيجة الجمالية الوردية للأسنان الاصطناعية المدعومة بالزرع بعد ستة أشهر من الجراحة الأولية. **النتائج:** أظهر تقييم القياسات السريرية لعرض التلال السنخية والنمط الحيوي للثة قبل التدخل الجراحي وبعد 6 أشهر عدم وجود فروق ذات دلالة إحصائية بينهما. كان متوسط درجة الجمالية الوردية 7.75. حقق مريضان فقط درجة جمالية إجمالية قدرها 10. حصل ثلاثة مرضى آخرين على درجة 8، وأربعة بدرجة 7، والباقي بدرجة 6. **الاستنتاج:** يحقق طعم العاج الذاتي المنشأ نتائج جمالية مقبولة بشكل فعال من خلال زرع أسنان فوري معزول يتم إدخاله في منطقة الفك العلوي الأمامي.

* **Corresponding author:** Ahmed F. Al-Quisi, Department of Oral and Maxillofacial Surgery, College of Dentistry, University of Baghdad, Baghdad, Iraq; Email: ahmedquisi@gmail.com

Article citation: Dkheel IA, Al-Quisi AF. The effectiveness of autogenous dentin graft as a biomaterial in optimizing the esthetic outcomes of immediate dental implants: A prospective clinical study. *Al-Rafidain J Med Sci.* 2023;5(Suppl 1):S81-86. doi: <https://doi.org/10.54133/ajms.v5i1S.307>

© 2023 The Author(s). Published by Al-Rafidain University College. This is an open access journal issued under the CC BY-NC-SA 4.0 license (<https://creativecommons.org/licenses/by-nc-sa/4.0/>).



INTRODUCTION

Dental implants are the most acceptable contemporary treatment for replacing missing teeth. In the past, implants were typically placed after a few weeks or months following tooth extraction to allow for socket healing. However, immediate implant placement has gained popularity recently due to its many benefits. Immediate placement offers advantages such as preserving alveolar bone, achieving better implant alignment, improving aesthetics, and providing psychological benefits to patients [1,2]. Non-traumatic extraction with immediate implantation and grafting is to prevent alveolar resorption by preserving the cortical plates and maintaining the dimensions of the extraction socket. These techniques aim to avoid cortical plate collapse and preserve the alveolar ridge's structure and volume [3]. The primary goal of the immediate implantation in the aesthetic zone is to achieve patient satisfaction with the aesthetic outcome and preserve the bone in the extraction area. Successfully managing these challenges makes it possible to maintain both functional and aesthetic aspects of the affected area [4]. Most immediately inserted dental implants in the esthetic zone require bone grafting into the jumping space to avoid severe resorption of the thin buccal bone plate [5]. Bone augmentation can be achieved with different graft materials, and autogenous bone grafts are their golden standard. However, it may be associated with a second surgical site, causing more trauma and pain for the patient [6]. On the other hand, other bone graft materials like allograft and xenograft may be associated with low osteogenic potential and may trigger an immune response that may complicate the procedure, besides the high cost of these materials [7]. The need for a graft having the advantages of autogenous grafts without requiring second-site surgery can be accomplished with an autogenous-derived dentin graft, especially in extracting non-restorable teeth with immediate dental implant insertion [8]. The close similarity between the alveolar bone and natural tooth organic and non-organic components, together with the histological similarity between them, makes it a perfect bone graft material for its osteo-conduction property [9]. The Pink Esthetic Score is an index used to evaluate the esthetic outcomes in dental implant surgery, which primarily focus on the evaluation of soft tissue characteristics in the context of anterior implant restorations in five variables, including mesial papilla, distal papilla, zenith line, convexity of labial mucosa, tissue color, and texture. A score of 0 is the lowest, and 2 is the highest value [10]. This study aims to assess the autogenous dentin graft biomaterial's ability to improve the esthetic outcomes of an immediately inserted implant in the maxillary esthetic region.

METHODS***Study design and setting***

This study was a prospective single-arm observational clinical trial conducted at the Baghdad Dental Teaching Hospital, Department of Oral and Maxillofacial Surgery, from March 2022 to April 2023, following ethical principles and in compliance with the Declaration of Helsinki and its later amendments.

Ethical considerations

This study has been ethically approved by the University of Baghdad Institutional Research Ethics Committee (protocol number 388121). Furthermore, the trial had been registered in the Thai clinical trial registry with registration number TCTR 20220908001.

Patient selection criteria

The study's eligibility criteria included adult patients between the ages of 18 and 60 who had natural, sound teeth surrounding non-restorable retained roots in the maxillary non-molar region. Screening consisted of a complete clinical and radiological examination, including patient health and clinical fitness for the dental implant procedure, gingival biotype, ridge width of at least 6 mm, the availability of at least 3mm of sound subapical bone, the presence of an intact labial bone plate, and the absence of acute periapical infection on cone beam computed tomography (CBCT) and clinically.

Outcome measurements

Alveolar bone width in CBCT before the surgical intervention and 6 months later clinically before the surgical intervention and 6 months later. Successful osseointegration and pink esthetic soft tissue score.

Surgical procedure

Each patient received a single dental implant; the surgical procedure started with the infiltration of a local anesthetic agent of lidocaine hydrochloride 2% and epinephrine (1:80,000). Atraumatic tooth extraction was achieved using a periosteal elevator and retained root extraction forceps, followed by direct measurement of the ridge width with a digital vernier. Caries, debris, remnants of soft tissues, and fillings were removed from the extracted root. Komitabio develops a smart dentin grinder. The "SmartSmartin Grinder"™ device was utilized to grind and sort the extracted tooth particles of 300–1200 microns. After grinding, the resulting particles were treated with a cleanser solution (sodium hydroxide and 20% alcohol) for 5 minutes in order to remove all pathogens and their toxins and to dissolve organic debris from these particles, followed by application of the neutralizer solution (phosphate buffered saline) with a pH of 5-7 for 1 minute, then the

particles were dried and ready for use. At the same time, the extraction site was cleaned by curettage and copious irrigation of normal saline; then, dental implant site preparation started with the pilot drill inserted on the mid-height of the palatal wall of the socket, followed by the next drills according to the manufacturer's instructions. A single dental implant from Binnovation, Brazil, of diameters (3.5 and 4.0 mm) and lengths (8.5–13 mm) was inserted for each patient, and the resulting jump distance was filled with the mineralized dentin graft and covered by gel foam with the figure of eight suturing. 6 months after the initial surgery, the 2nd stage of surgery was accomplished by placing the gingival former, utilizing a crestal incision, and measuring the alveolar ridge width with the digital vernier. After impression, the final prosthetic supragingival part was inserted, and the esthetic outcomes were evaluated with the Pink Esthetic Score index [10] after two weeks by an independent oral and maxillofacial surgeon. The full, detailed steps of the procedure are shown in Figure 1.

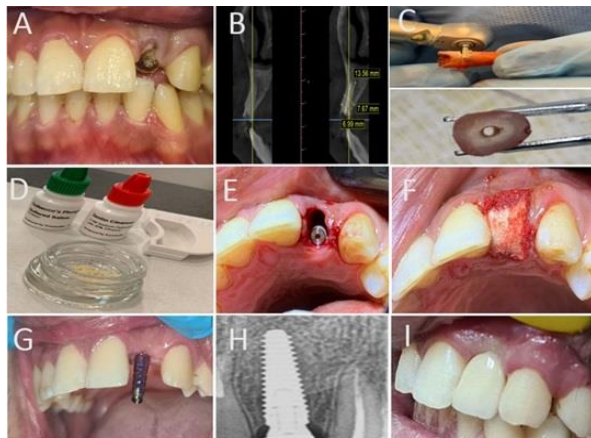


Figure 1: A detailed case of immediate dental implant insertion with an autogenous dentin graft and subsequent prosthetic part loading and evaluation of the Pink Esthetic Score (A) a preoperative view of the non-restorable maxillary left lateral incisor; (B) an axial view of CBCT showing the accused retained root and the surrounding bone; (C) preparation of the extracted retained root before grinding; (D) treating the resulting autogenous dentin particles with cleanser and neutralizer solutions; (E) dental implant placed in the palatal position with a labial jump distance to be filled with the graft; (F) placement of the gel foam plug over the implant and the graft; (G) impression post placed in the second stage of treatment; (H) periapical x-ray showed osseointegration around the dental implant after six months from the initial operation; (I) final clinical view of the implant-supported crown at the time of insertion.

Statistical analysis

The data was analyzed using Statistical Package for Social Sciences (SPSS) software, version 25. The Shapiro-Wilk test was used to assess the normality of the data distribution. In the statistical analyses, the implants are considered statistically independent. The PES index and Pearson correlation coefficient test were used to assess the correlations between gingival biotypes

before and after implantation. At the same time, the study's sample size was calculated using G-Power 3.1 software.

RESULTS

Thirty-three patients volunteered to participate in this study; 13 were excluded because they did not fit the inclusion criteria. Only twenty eligible patients (13 females and 7 males) were enrolled in this study, as illustrated in Figure 2.

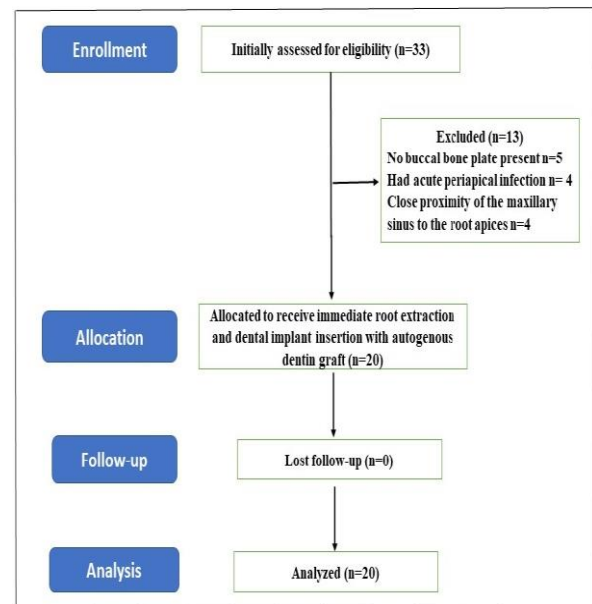


Figure 2: Flow chart of the study

The patients' ages ranged from 26 to 56, with a mean of 39.33 ± 9.02 years. The highest proportion of the studied patients were 30–44 years old. These patients had a single non-restorable retained root in the maxillary esthetic zone, surrounded by healthy natural teeth. The socket width was evaluated preoperatively utilizing both CBCT and direct clinical measurement with a digital vernier; a paired t-test showed a statistically insignificant difference between these two measurement methods, as shown in Table 1.

Table 1: Comparison between clinical and radiological measurements of the alveolar ridge width

Method of measurement	Alveolar ridge width	p- Value
Clinical	8.12±1.97	0.75118
Radiological	8.06±1.48	

Values were expressed as mean±SD.

The assessment of the clinical measurements of the alveolar ridge width and gingival biotype before surgical intervention and six months later showed no significant differences ($p>0.05$) between preoperative and second-stage values, as detailed in Table 2.

Table 2 Comparison of gingival biotypes and alveolar ridge width changes before and after surgical intervention

Variables	Time		p-value*
	Preoperatively	Postoperatively	
Alveolar ridge width	7.78± 2.24	7.52± 2.03	0.567
Gingival biotype	1.40 ± 0.42	1.39 ± 0.36	0.915

Values were expressed as mean±SD; * paired t-test.

The Pink Esthetic Score (PES) mean was 7.75±1.45. Only two patients achieved the total esthetic score of 10, another three patients had a score of 8, four patients had a score of 7, and the rest had a score of 6 or less. The Pearson Correlation Coefficient Calculator was utilized to estimate the correlations between the pre- and postoperative gingival biotype and alveolar ridge width with the esthetic results, as shown in Table 3.

Table 3: the correlations between pink esthetic variables with the gingival biotype and alveolar ridge width in pre- and post-operative periods

Correlations	Pre-operative variables		Post-operative variables	
	Gingival biotype	Alveolar ridge width	Gingival biotype	Alveolar ridge width
Mesial papilla score	0.123§	0.289§	0.086§	0.161§
Distal papilla score	0.687*	0.337*	0.733*	0.521*
Soft tissue contour score	0.146§	0.220§	0.263§	0.107§
Soft tissue level score	0.633*	0.469*	0.290*	0.670*
Alveolar process contour score	0.089§	0.379§	0.356§	0.053§
	0.772*	0.200*	0.146*	0.831*
	0.462§	0.464§	0.230§	0.503§
	0.111*	0.464*	0.358*	0.503*
	0.146§	0.342§	0.398§	0.033§
	0.633*	0.251*	0.101*	0.159*

Spearman's Rho Correlation, § refer to r-value and * refer to p-value (2-tailed)

The results showed only a weak positive relationship between these variables and pink aesthetic score items. However, the alveolar ridge width in the postoperative period strongly correlated with the alveolar process contour item of the pink esthetic score. However, the mean value of the total pink esthetic score had strong positive correlations with the postoperative gingival biotype and alveolar ridge width, as shown in Table 4. Furthermore, no complications were reported during or after the surgical procedure. All the dental implants succeeded in osseointegration.

Table 4: Correlations between The Pink Esthetic Score results with the postoperative gingival biotype and ridge width

Correlations	Alveolar ridge width	Gingival biotype
Pink Esthetic Score	0.62109§	0.8983§
	0.00594*	0.00001*

Spearman's Rho correlation, § refer to r-value and * refer to p-value.

DISCUSSION

This study evaluates the esthetic outcome of 20 patients who underwent immediate dental implant placement

using an autogenous dentin graft as a filling biomaterial for the jumping distance. The anterior maxilla is widely recognized as challenging due to its high esthetic expectations. The successful outcome of implant restorations in this area relies on the interplay between bone support and soft tissue dimensions, as these factors significantly contribute to the final esthetic result [11]. In order to achieve optimal esthetics and functional outcomes, careful consideration should be given to the positioning of dental implants in the anterior maxilla. The placement should take into account the natural contours of neighboring teeth and the ideal position of the alveolar ridge [12,13]. This approach helps to ensure proper integration of the implant with the surrounding bone over time, promoting long-term stability and esthetic harmony. Inadequate thickness of the buccal bone can result in a reduction in buccal bone height and the occurrence of soft tissue dehiscence and gingival recession. These conditions can have detrimental effects on both the biomechanical and esthetic outcomes of dental implant treatment [14]. Multiple methods were used to measure the alveolar socket dimension [15]; most researchers used direct clinical measurements at the time of surgery or radiological 3D measurements with CBCT [16]. To confirm the validity of these methods, this study compared these measurements, and the results showed statistically insignificant differences between them. This result encourages using the direct clinical measurement method to minimize the need to expose the patient to potentially harmful radiation from the CBCT. Different bone substitutes were used to fill the gap (jump distance) after tooth extraction and immediate dental implant insertion with variable efficiency [17,18]. Although it has been hypothesized that demineralization of the autogenous dentin graft may lead to optimization of the osteo-inductive power, the lack of a standardized protocol for demineralization plus the delay as the process may take more than two days limit its use in the immediate cases. Besides, it is mainly indicated when there is a bony wall defect in the socket [19]. In contrast, a mineralized autogenous dentin graft had better mechanical stability, leading to a solid site for implant placement [20]. Furthermore, all cases included in this study had intact bony walls, as checked radiologically in the CBCT preoperatively and clinically at the time of surgery after tooth extraction. Most maxillary anterior teeth have a thin labial bone plate that is liable for fast remodeling. Postoperative gingival biotype thickening will result from resorption of the underlying labial bone plate and excessive soft tissue ingrowth due to the high proliferative rate [21]. The role of the mineralized autogenous dentine graft in the immediate dental implant inserted in the maxillary esthetic zone was investigated for the first time in this clinical study. The results showed excellent outcomes regarding the dimensional stability of the extraction socket, with no statistically significant changes in the mean of the gingival biotype or socket width.

Furthermore, the flapless approach was used in this study, as the resorption of the labial bone plate was found to be more significant when using the flap approach compared to the flapless approach due to the disturbance caused to the periosteum during flap elevation. Such disturbance compromises the blood supply to the area and subsequently increases the activity of osteoclasts on the buccal bone surface, leading to more significant bone resorption [22,23]. The gingival biotype and the thickness of the labial bone plate are important factors that can affect the level of marginal tissue (zenith line) and the presence of papilla when placing implants right away in jaws with a thin labial bone plate [24]. This may explain the strong positive correlation between the postoperative gingival biotype and the Pink Esthetic Score in this study. However, a previous study comparing the gingival biotype thickness changes between immediate and delayed implants showed no statistically significant effect of the gingival biotype thickness on the esthetic outcomes [25]. This counteracting data can be explained by the limited number of implants in each group and the fact that the dental implant sites involved posterior areas of the jaws with a thicker buccal bone plate and gingival biotype. The good esthetic results in the current study resulted from accumulating all these previous factors, flapless surgery in sites with an intact labial bone plate, and using a mineralized autogenous dentin graft to fill the gap and support the thin labial bone plate. Moreover, this study showed a strong positive correlation between the postoperative gingival biotype and the Pink Esthetic Score.

Conclusion

Despite the limitations of this study (the limited number of participants due to strict selection criteria), utilizing only one augmentation material restricts the ability to compare its effectiveness with different materials. An autogenous dentine graft is effective in achieving acceptable esthetic outcomes with a single dental implant placed in the anterior maxillary area.

Conflict of interests

No conflict of interest was declared by the authors

Funding source

The authors did not receive any source of fund.

Data sharing statement

Supplementary data can be shared with the corresponding author upon reasonable request.

REFERENCES

- Schwartz-Arad D, Chaushu G. Placement of implants into fresh extraction sites: 4 to 7 years retrospective evaluation of 95 immediate implants. *J Periodontol.* 1997;68(11):1110-1116. doi: 10.1902/jop.1997.68.11.1110.
- Chen ST, Buser D. Clinical and esthetic outcomes of implants placed in postextraction sites. *Int J Oral Maxillofac Implants.* 2009;24(Suppl):186-217. PMID: 19885446.
- Naeem DM, Al-Jumaily HA. Can the immediate implantation with immediate loading Achieve an Acceptable Esthetic Outcome? A Prospective Observational Clinical Study. *J Craniofac Surg.* 2023;34(1):e79-e84. doi: 10.1097/SCS.00000000000008876.
- Groenendijk E, Staas TA, Bronkhorst E, Raghoobar GM, Meijer GJ. Immediate implant placement and provisionalization: Aesthetic outcome 1 year after implant placement. A prospective clinical multicenter study. *Clin Implant Dent Relat Res.* 2020;22(2):193-200. doi: 10.1111/cid.12883.
- Zucchelli G, Sharma P, Mounssif I. Esthetics in periodontics and implantology. *Periodontol.* 2018;77(1):7-18. doi: 10.1111/prd.12207.
- Aghaloo TL, Misch C, Lin GH, Iacono VJ, Wang HL. Bone augmentation of the edentulous maxilla for implant placement: A systematic review. *Int J Oral Maxillofac Implants.* 2016;3(Suppl):s19-30. doi: 10.11607/jomi.
- Schmitt CM, Doering H, Schmidt T, Lutz R, Neukam FW, Schlegel KA. Histological results after maxillary sinus augmentation with Straumann® BoneCeramic, Bio-Oss®, Puros®, and autologous bone. A randomized controlled clinical trial. *Clin Oral Implants Res.* 2013;24(5):576-585. doi: 10.1111/j.1600-0501.
- Kim YK, Lee JH, Um IW, Cho WJ. Guided bone regeneration using demineralized dentin matrix: Long-term follow-up. *J Oral Maxillofac Surg.* 2016;74(3):515.e1-9. doi: 10.1016/j.
- Kim YK, Kim SG, Um IW, Kim KW. Bone grafts using autogenous tooth blocks: a case series. *Implant Dent.* 2013;22(6):584-589. doi: 10.1097/ID.0000000000000011.
- Belser UC, Grütter L, Vailati F, Bornstein MM, Weber HP, Buser D. Outcome evaluation of early placed maxillary anterior single-tooth implants using objective esthetic criteria: a cross-sectional, retrospective study in 45 patients with a 2- to 4-year follow-up using pink and white esthetic scores. *J Periodontol.* 2009;80(1):140-151. doi: 10.1902/jop.2009.080435.
- Cardaropoli G, Lekholm U, Wennström JL. Tissue alterations at implant-supported single-tooth replacements: a 1-year prospective clinical study. *Clin Oral Implants Res.* 2006;17(2):165-171. doi: 10.1111/j.1600-0501.2005.01210.x.
- Schropp L, Wenzel A, Kostopoulos L, Karring T. Bone healing and soft tissue contour changes following single-tooth extraction: a clinical and radiographic 12-month prospective study. *Int J Periodontics Restorative Dent.* 2003;23(4):313-323. PMID: 12956475.
- Abdulmunem MM, Mohammed JA. Immediate implant placement in fresh extraction socket. *J Baghdad Coll Dentist.* 2016;28(4):103-110. doi:10.12816/0033219.
- Gross MD, Nissan J, Samuel R. Stress distribution around maxillary implants in anatomic photoelastic models of varying geometry. Part I. *J Prosthet Dent.* 2001;85(5):442-449. doi: 10.1067/mpr.2001.115253.
- Karaca Ç, Er N, Gülşahi A, Köseoğlu OT. Alveolar ridge preservation with a free gingival graft in the anterior maxilla: volumetric evaluation in a randomized clinical trial. *Int J Oral Maxillofac Surg.* 2015;44(6):774-780. doi: 10.1016/j.ijom.2015.01.015.
- Horváth A, Mardas N, Mezzomo LA, Needleman IG, Donos N. Alveolar ridge preservation. A systematic review. *Clin Oral Investig.* 2013;17(2):341-363. doi: 10.1007/s00784-012-0758-5.
- Kabi S, Kar R, Samal D, Deepak KC, Kar IB, Mishra N. Immediate dental implant placement with or without autogenous bone graft: A comparative study. *Natl J Maxillofac Surg.* 2020;11(1):46-52. doi: 10.4103/njms.NJMS_59_19.
- Wu D, Zhou L, Lin J, Chen J, Huang W, Chen Y. Immediate implant placement in anterior teeth with grafting material of autogenous tooth bone vs xenogenic bone. *BMC Oral Health.* 2019;19(1):266. doi: 10.1186/s12903-019-0970-7.

19. Kim YK, Pang KM, Yun PY, Leem DH, Um IW. Long-term follow-up of autogenous tooth bone graft blocks with dental implants. *Clin Case Rep.* 2017;5(2):108-118. doi: 10.1002/ccr3.754.
20. Calvo-Guirado JL, Cegarra Del Pino P, Sapoznikov L, Delgado Ruiz RA Fernández-Domínguez M, Gehrke SA. A new procedure for processing extracted teeth for immediate grafting in post-extraction sockets. An experimental study in American Fox Hound dogs. *Ann Anat.* 2018;217: 14–23. doi: 10.1016/j.aanat.2017.12.010.
21. Al-Quisi AF, Aldaghir OM, Al-Jumaily HA. Comparison between Rolled and Nonrolled U-Shaped Flap in the Second Stage of Dental Implant Surgery: A Randomized Clinical Trial. *Int J Dentist.* 2022;2022:1329468. doi: 10.1155/2022/1329468.
22. Blanco J, Alves CC, Nuñez V, Aracil L, Muñoz F, Ramos I. Biological width following immediate implant placement in the dog: flap vs. flapless surgery. *Clin Oral Implants Res.* 2010;21(6):624-631. doi: 10.1111/j.1600-0501.2009.01885.x.
23. Hassan AF, Abdul-Lateef T. A comparative study between flapped and flapless surgical techniques in dental implant stability according to resonance frequency analysis. *J Baghdad Coll Dentist.* 2016;28(2):92-97. doi:10.12816/0033219.
24. Lee A, Fu JH, Wang HL. Soft tissue biotype affects implant success. *Implant Dent.* 2011;20(3):e38-47. doi: 10.1097/ID.0b013e3182181d3d.
25. van Kesteren CJ, Schoolfield J, West J, Oates T. A prospective randomized clinical study of changes in soft tissue position following immediate and delayed implant placement. *Int J Oral Maxillofac Implants.* 2010;25(3):562-570. PMID: 20556256.